



PATIENT

Argon Accello

SPECIES

Canine

BREED

Chihuahua Mix

SEX

Neutered male

AGE

2 years

WEIGHT

13.2 lbs

INTERPRETED BY

Eric Lindquist, DMV
DABVP, Cert. IVUSS

IMAGING PERFORMED BY

Jenn

HOSPITAL NAME

Rockaway AH

REFERRING VET

Dr. Maniar

INVOICE

43622

DATE

3/30/23

PRESENTING CLINICAL SIGNS

History: recheck f/u from hospitalization doing well at home no concerns Previous u/s 3/9 and 3/10 3/9 showed minor retention of ingesta 3/10 showed GI tract is empty w/o further retention of ingesta

ULTRASONOGRAPHIC EXAMINATION OF THE ABDOMEN

Gastrointestinal

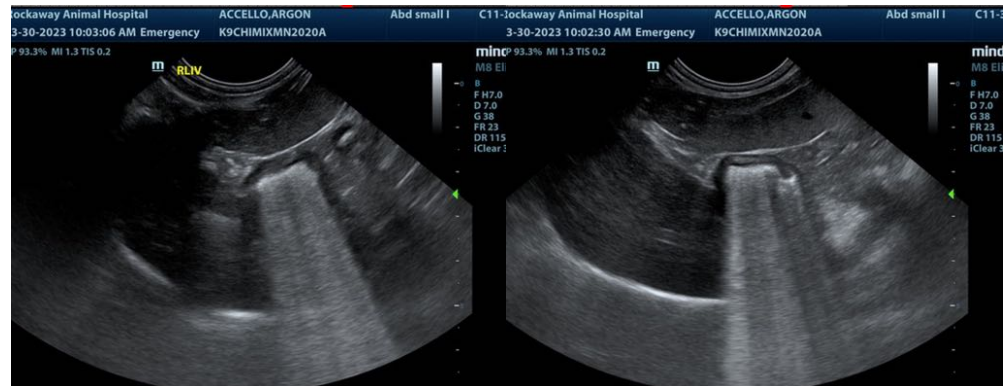
The **gastrointestinal tract** was empty in this patient. The curvilinear patterns were maintained. There was no evidence of residual luminal material. The small intestine and colon were unremarkable.

ULTRASONOGRAPHIC FINDINGS

There is no evidence of retained ingesta.

INTERPRETATION OF THE FINDINGS & FURTHER RECOMMENDATIONS

No therapy is recommended at this time.



The information and recommendations provided are based on the images presented by the referring veterinarian/sonographer. No evaluation can be communicated regarding pathology that was not visible in the image/video clips provided.

Thank you for this referral. If the clinical or image interpretation does not parallel your findings or if I can be of any further assistance please contact me.

Eric Lindquist, DMV, DABVP, Cert. IVUSS, CEO of SonoPath.com
info@SonoPath.com