



**PATIENT**

Mistletoe Humane Society

**SPECIES**

Feline

**BREED**

Domestic Longhair

**SEX**

Spayed Female

**AGE**

9 years

**WEIGHT**

8 lbs

**PRESENTING CLINICAL SIGNS**

History: Heart murmur heard on routine exam (grade 3); heart looked moderately enlarged on radiographs  
 Abnormal PE/Chem/CBC/UA Results: bw unremarkable

**ULTRASONOGRAPHIC EXAMINATION OF THE HEART**

The echocardiogram in this patient demonstrated normal **left atrial** size based on 3 separate LA measurements. The cranial and caudal **mitral** valve leaflets presented normal linear structure and kinetics. The **left ventricle** presented normal thicknesses with linear contour and was not dilated nor restricted. The **myocardium** presented normal echogenicity without subjective evidence of significant fibrotic or ischemic disease. **Contractility** of the ventricular walls was adequate and in normal range for this patient evidenced by the fractional shortening measurement and subjective evaluation of the different regions and angles of the myocardium. The **left ventricular outflow** tract demonstrated normal structural integrity. The **right atrium** and auricle revealed normal size, structure and content. No evidence of masses was noted or chamber overload. **Tricuspid** valvular assessment demonstrated adequate linear morphology and kinetics. The **right ventricle** was of normal size (1/3 diameter of LV), chordae structure, myocardial echogenicity and thickness. **Pulmonic** tract assessment revealed normal valve structure and diameter (approx.1:1 pa/ao ratio). No visible **pericardial** or free pleura fluid was noted or extra cardiac pathology in the visible planes. The cranial **mediastinum and pericardial regions** were free of masses in the visible window.

**INTERPRETED BY**

Eric Lindquist, DMV DABVP, Cert. IVUSS

**IMAGING PERFORMED BY**

Jill Rumachik

**HOSPITAL NAME**

Mazomanie AH

**REFERRING VET**

Dr. Ripley

**INVOICE**

97949

**DATE**

3/30/22

FELINE CARDIAC PARAMETERS	BODY WEIGHT (kg)	HR (BPM)	IVSd (cm)	LVIDd (cm)	LVWd (cm)	FS (%)	EF (%)
NORMAL PARAMETER	-----	150-240	0.3-0.6	1.0-2.1	0.25-0.6	35-67	80-100
PATIENT		NM	0.5	1.4	0.5	50	90
FELINE CARDIAC PARAMETERS	LA/AO (Boon)	LA/AO HEART BASE (Sisson)	LA 2D 4-chamber long axis AS to FW (Sisson) (cm)	LVOT VEL. (m/s)	RVOT VEL. (m/s)	IVRT (m/)	
NORMAL PARAMETER	<1.5	0.88-1.79	0.7-1.7	<1.6	<1.3	40-60	
PATIENT	1.4	1.3					NM
Adapted from June Boon, Veterinary Echocardiography, 1998 Sisson D et al. JVIM 1991; 5: 232, Jacobs et al. Am J Vet Res 1985; 46:1705							



**PATIENT**

Mistletoe Humane Society

**SPECIES**

Feline

**BREED**

Domestic Longhair

**SEX**

Spayed Female

**AGE**

9 years

**WEIGHT**

8 lbs

**INTERPRETED BY**

Eric Lindquist, DMV DABVP, Cert. IVUSS

**IMAGING PERFORMED BY**

Jill Rumachik

**HOSPITAL NAME**

Mazomanie AH

**REFERRING VET**

Dr. Ripley

**INVOICE**

97949

**DATE**

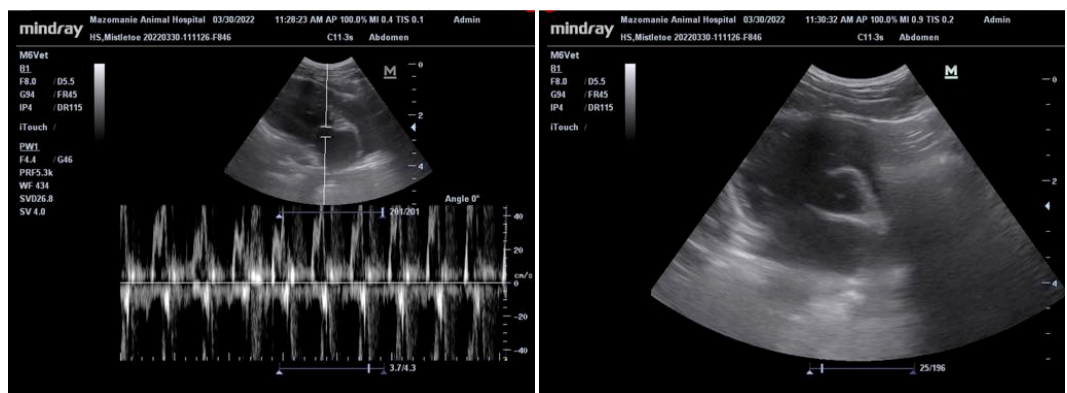
3/30/22

**ULTRASONOGRAPHIC FINDINGS**

Likely flow murmur.

**INTERPRETATION OF THE FINDINGS & FURTHER RECOMMENDATIONS**

The images were somewhat pixelated. The cause of the murmur is unclear in this patient. Chamber sizes and wall thicknesses are normal.



The information and recommendations provided are based on the images presented by the referring veterinarian/sonographer. No evaluation can be communicated regarding pathology that was not visible in the image/video clips provided.

Thank you for this referral. If the clinical or image interpretation does not parallel your findings or if I can be of any further assistance please contact me.

Eric Lindquist, DMV, DABVP, Cert. IVUSS, CEO of SonoPath.com  
info@SonoPath.com