



PATIENT

Cannoli Zeringo

PRESENTING CLINICAL SIGNS

abdominal pain, vomiting, inappetence. On famotidine 10 mg
Abnormal PE/Chem/CBC/UA Results: wnl other than slight neutrophilia

SPECIES

Canine

ULTRASONOGRAPHIC EXAMINATION OF THE ABDOMEN

Urinary System

BREED

Mix

The **urinary bladder**, trigone, and pelvic urethra presented normal thicknesses and normal tone. The ureters were not visible which is normal. No uroliths or sediment were visualized and anechoic urine was present. No evidence of inflammatory or neoplastic changes were noted. Ureteral papillae were normal.

SEX

Spayed Female

The **kidneys** revealed normal size and structure, corticomedullary definition and ratio for this age. The cortices presented largely uniform texture with normal echogenic relationship to liver and spleen. Medullary structure differed distinctly from the cortex and no evidence of pelvic dilation was present. The capsules were acceptably uniform without significant irregularities. The left kidney measured 5.36 cm. The right kidney measured 5.48 cm.

AGE

4 Months

Adrenal Glands

WEIGHT

14.6 Pounds

Both **adrenal glands** were visualized and recognized as having normal shape, size, position and echogenicity for this breed. The phrenic vasculature, glandular echogenicity and detail were unremarkable. Capsule, cortex, and medullary definition were normal for this age patient. The right adrenal gland measured 2.0 cm x 0.52 cm at the caudal pole and 0.84 cm at the cranial pole. The left adrenal gland measured 1.93 cm x 0.39 cm at the caudal pole and 0.44 cm at the cranial pole.

INTERPRETED BY

Eric Lindquist, DMV

DABVP, Cert. IVUSS

Spleen

The **spleen** presented a smooth homogeneous parenchyma hyperechoic to liver and renal cortical parenchyma. The capsule was smooth without noticeable expansion or deviation from within the spleen or adjacent pathology. The splenic vasculature demonstrated normal volume without signs of congestion or thrombosis. No sonographic evidence of acute or chronic inflammatory, neoplastic, or infarctual changes were noted.

IMAGING PERFORMED BY

Diane McFadden

Liver

The **liver** images submitted revealed subjectively normal liver size, contour, and structure. Parenchymal echogenicity was naturally coarse and hypoechoic to the spleen. Vascular and biliary tracts were of normal volume with no evidence of congestion. The gallbladder presented acceptably thin walls with primarily anechoic content. The cystic and common bile ducts were normal. No pathological hepatic lymphadenopathy was evident. No overt structural evidence of inflammatory, infiltrative or regenerative pathology was evident.

HOSPITAL NAME

ACC Landing

REFERRING VET

Dr. Villari

Gastrointestinal

The **stomach** revealed mildly echogenic fluid stasis. Gastric wall was normal. Shadowing gastric material present measuring approximately 4.0 cm, embedded in the pylorus and continuing into the small intestine with linear attachment, corrugated pleating, and a 2nd shadowing structure.

INVOICE

36565

Pancreas

DATE

3/30/22

The base and limbs of the **pancreas** were observed to be largely isoechoic to surrounding omental fat. Pancreatic duct and capsular contour were acceptably normal and parenchyma respected normal curvilinear patterns. No overt evidence of active inflammatory or neoplastic disease was noted.



PATIENT

Free Abdomen

Cannoli Zeringo

Slight free fluid noted.

SPECIES

Canine

ULTRASONOGRAPHIC FINDINGS

- Gastrointestinal linear foreign body anchored in the pylorus with accordion pleating in the small intestine
- Slight free fluid

BREED

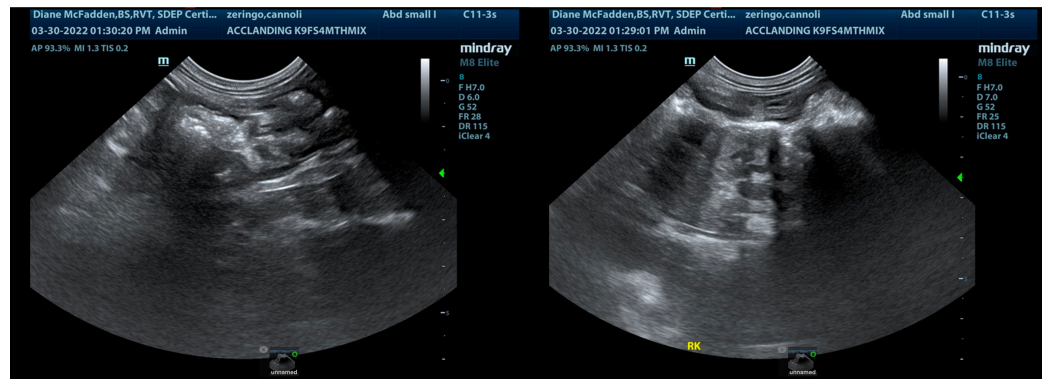
Mix

INTERPRETATION OF THE FINDINGS & FURTHER RECOMMENDATIONS

Immediate exploratory surgery recommended with gastrotomy and enterotomies.

SEX

Spayed Female



AGE

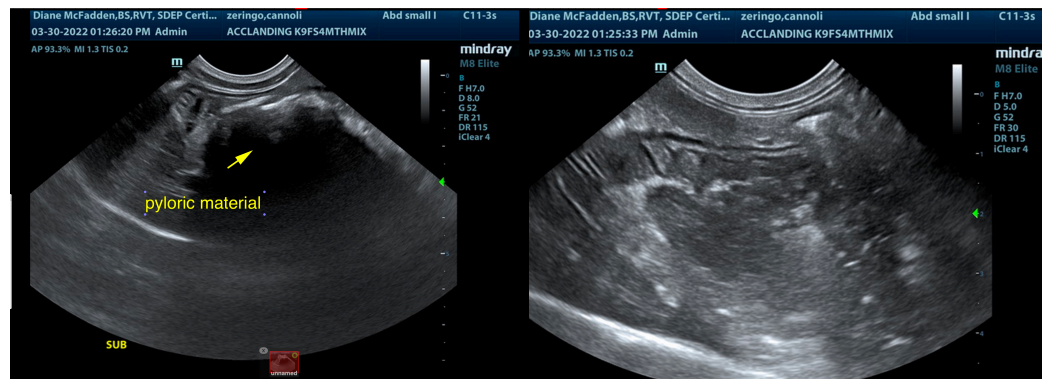
4 Months

WEIGHT

14.6 Pounds

INTERPRETED BY

Eric Lindquist, DMV
DABVP, Cert. IVUSS

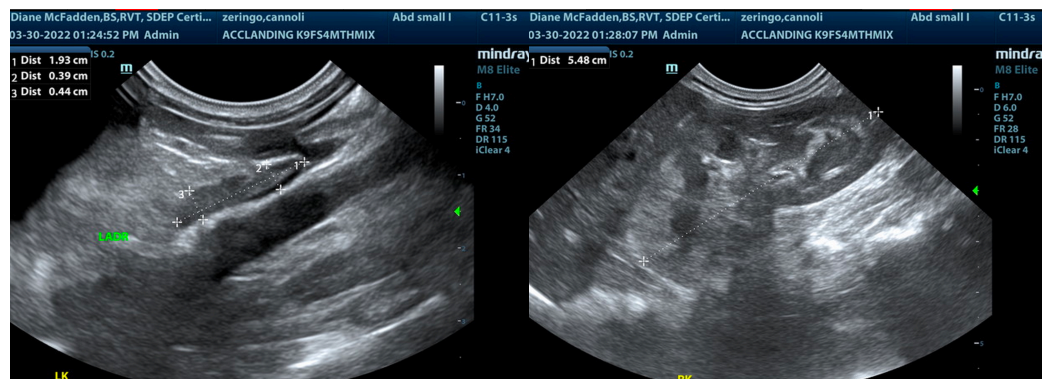


IMAGING PERFORMED BY

Diane McFadden

HOSPITAL NAME

ACC Landing



REFERRING VET

Dr. Villari

INVOICE

36565

DATE

3/30/22



PATIENT

Cannoli Zeringo

SPECIES

Canine

BREED

Mix

SEX

Spayed Female

AGE

4 Months

WEIGHT

14.6 Pounds

INTERPRETED BY

Eric Lindquist, DMV

DABVP, Cert. IVUSS

IMAGING PERFORMED BY

Diane McFadden

HOSPITAL NAME

ACC Landing

REFERRING VET

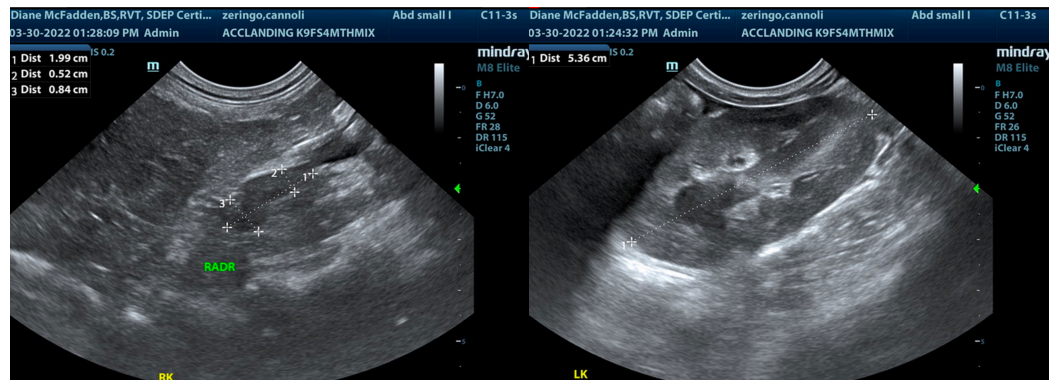
Dr. Villari

INVOICE

36565

DATE

3/30/22



The information and recommendations provided are based on the images presented by the referring veterinarian/sonographer. No evaluation can be communicated regarding pathology that was not visible in the image/video clips provided.

Thank you for this referral. If the clinical or image interpretation does not parallel your findings or if I can be of any further assistance please contact me.

Eric Lindquist, DMV, DABVP, Cert. IVUSS, CEO of SonoPath.com

info@SonoPath.com