



PATIENT

Birdie Krecedelio

SPECIES

Canine

BREED

Wire Hair Griffon

SEX

Spayed Female

AGE

4 Years 6 Months

WEIGHT

50 Pounds

INTERPRETED BY

Eric Lindquist, DMV,
 DABVP (CFM), Cert.
 IVUSS

IMAGING

PERFORMED BY

Kerri Becker

HOSPITAL NAME

Marsh AH

REFERRING VET

Dr. Armani

INVOICE

36072

DATE

3/3/26

PRESENTING CLINICAL SIGNS

History: Anorexia for almost 5-6 days

Abnormal PE/Chem/CBC/UA Results: AST-176 alp-556 wbc-101.2 now wbc-135 lymph-97,152 neut-2,024

ULTRASONOGRAPHIC EXAMINATION OF THE HEART & ABDOMEN

CANINE CARDIAC PARAMETERS	MR VMAX (m/s)	TR VMAX (m/s)	LA/AO (M-Mode)	LA/AO (Heart Base; Swe)	FS (%)	EF (%)	EPSS (cm)
NORMAL PARAMETER	4.5-5.5	<2.7	1.3	Up to 1.6	28-40	40-100	<0.6
PATIENT	--	--	1.1	1.3	35	60	0.1
CANINE CARDIAC PARAMETERS	HR (BPM)	AV VMAX (m/s)	PV MAX (m/s)	BODY WEIGHT (lbs)	LAD LA MAX 4 Chamber	LVIDd Avg; 2D and m-mode short axis (cm)	LVIDs Avg; 2D and m-mode short axis (cm)
NORMAL PARAMETER	50-100	0.7-1.7	0.7-1.6				
PATIENT	110	1.40	90	50 lbs	3.2	3.4	--

Cardiac Presentation

The echocardiogram in this patient demonstrated normal **left atrial** size based on 3 separate methods of LA evaluation. The cranial and caudal **mitral** valve leaflets presented normal linear structure, extension in systole, and union in diastole with normal kinesis. The **left ventricle** presented thicknesses with linear contour and was not dilated nor restricted. The **myocardium** presented normal echogenicity without subjective evidence of significant fibrotic or ischemic disease. **Contractility** of the ventricular walls was adequate and in normal range for this patient evidenced by the fractional shortening measurement and subjective evaluation of the different regions of the myocardium. The **left ventricular outflow** tract demonstrated normal laminar flow and subjective structural integrity. The **right atrium** and auricle revealed normal size, structure and content. No evidence of masses was noted. **Tricuspid** valvular assessment demonstrated adequate linear morphology and kinesis. The **right ventricle** was of normal size (1/3 diameter of LV), chordae structure, myocardial echogenicity and thickness. **Pulmonary outflow** tract assessment revealed normal valve structure, laminar flow, and diameter (approx.1:1 pa/ao ratio). No visible **pericardial** or free pleura fluid was noted. The cranial **mediastinum and pericardial and extra-cardiac regions** were free of masses in the visible window.

Urinary System



PATIENT

Birdie Krecedelio

SPECIES

Canine

BREED

Wire Hair Griffon

SEX

Spayed Female

AGE

4 Years 6 Months

WEIGHT

50 Pounds

INTERPRETED BY

Eric Lindquist, DMV,
DABVP (CFM), Cert.
IVUSS

IMAGING PERFORMED BY

Kerri Becker

HOSPITAL NAME

Marsh AH

REFERRING VET

Dr. Armani

INVOICE

36072

DATE

3/3/26

The **urinary bladder**, trigone, and pelvic urethra presented normal thicknesses and normal tone. The ureters were not visible which is normal. No uroliths or sediment were visualized and anechoic urine was present. No evidence of inflammatory or neoplastic changes were noted. Ureteral papillae were normal. The pelvic urethra was imaged 1.0 cm beyond the cystourethral junction.

The **kidneys** revealed normal size and structure, corticomedullary definition and ratio for this age. The cortices presented largely uniform texture with normal echogenic relationship to liver and spleen. Medullary structure differed distinctly from the cortex and no evidence of pelvic dilation was present. The capsules were acceptably uniform without significant irregularities. The kidneys measured 5.0 cm each.

Adrenal Glands

Both **adrenal glands** appeared flattened and isoechoic. Screening for underlying Addison's is indicated. The left adrenal gland measured 0.5 cm.

Spleen

The **spleen** was folded upon itself cranially. The spleen was mildly enlarged with a focal 5.0 mm nodule at the cranial pole. No over inflammation was noted; however, this may be causing some discomfort. Clinical palpation of the spleen is indicated to assess for discomfort. Vascularity of the spleen appeared to be normal. No overt evidence of torsion, however, I cannot rule out a predisposition to torsion.

Liver

The **liver** images submitted revealed subjectively normal liver size, contour, and structure. Parenchymal echogenicity was naturally coarse and hypoechoic to the spleen. Vascular and biliary tracts were of normal volume with no evidence of congestion. The gallbladder presented acceptably thin walls with primarily anechoic content. The cystic and common bile ducts were normal. No pathological hepatic lymphadenopathy was evident. No overt structural evidence of inflammatory, infiltrative or regenerative pathology was evident.

Gastrointestinal

Examination of the **gastrointestinal tract** revealed a stomach and intestine free of stasis, of normal wall thickness, acceptable curvilinear mural detail, and peristaltic activity. Small and large intestine demonstrated normal luminal chyme and stool consistency respectively. No obstructive or overt infiltrative disease was noted. No associated abnormal lymphatic activity was noted.

Pancreas

The base and limbs of the **pancreas** were observed to be largely isoechoic to surrounding omental fat. Pancreatic duct and capsular contour were acceptably normal and parenchyma respected normal curvilinear patterns. No overt evidence of active inflammatory or neoplastic disease was noted.

ULTRASONOGRAPHIC FINDINGS

- Normal echocardiogram
- Mild splenomegaly without obvious infiltrative pattern and focal nodule
- Flattened adrenal glands- potential underlying Addisons



PATIENT

Birdie Krecedelio

SPECIES

Canine

BREED

Wire Hair Griffon

SEX

Spayed Female

AGE

4 Years 6 Months

WEIGHT

50 Pounds

INTERPRETED BY

Eric Lindquist, DMV,
 DABVP (CFM), Cert.
 IUUSS

IMAGING PERFORMED BY

Kerri Becker

HOSPITAL NAME

Marsh AH

REFERRING VET

Dr. Armani

INVOICE

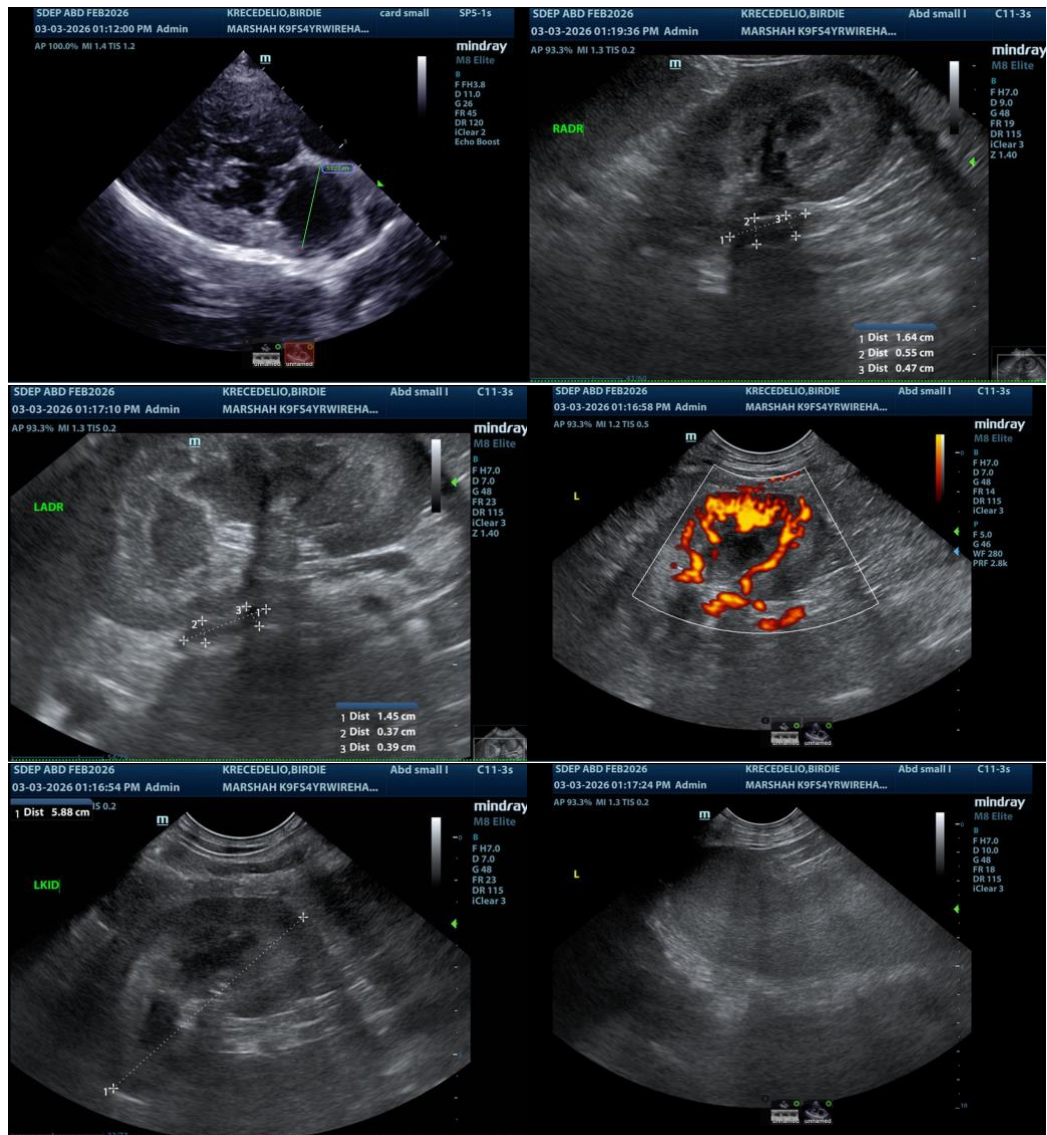
36072

DATE

3/3/26

INTERPRETATION OF THE FINDINGS & FURTHER RECOMMENDATIONS

Screening for Addison's with ACTH stimulation is indicated and manual palpation. Otherwise, other causes of the clinical signs, such as orthopedic pain, CNS or thoracic disease could all be considered.





PATIENT

Birdie Krecedelio

SPECIES

Canine

BREED

Wire Hair Griffon

SEX

Spayed Female

AGE

4 Years 6 Months

WEIGHT

50 Pounds

INTERPRETED BY

Eric Lindquist, DMV,
 DABVP (CFM), Cert.
 IVUSS

IMAGING PERFORMED BY

Kerri Becker

HOSPITAL NAME

Marsh AH

REFERRING VET

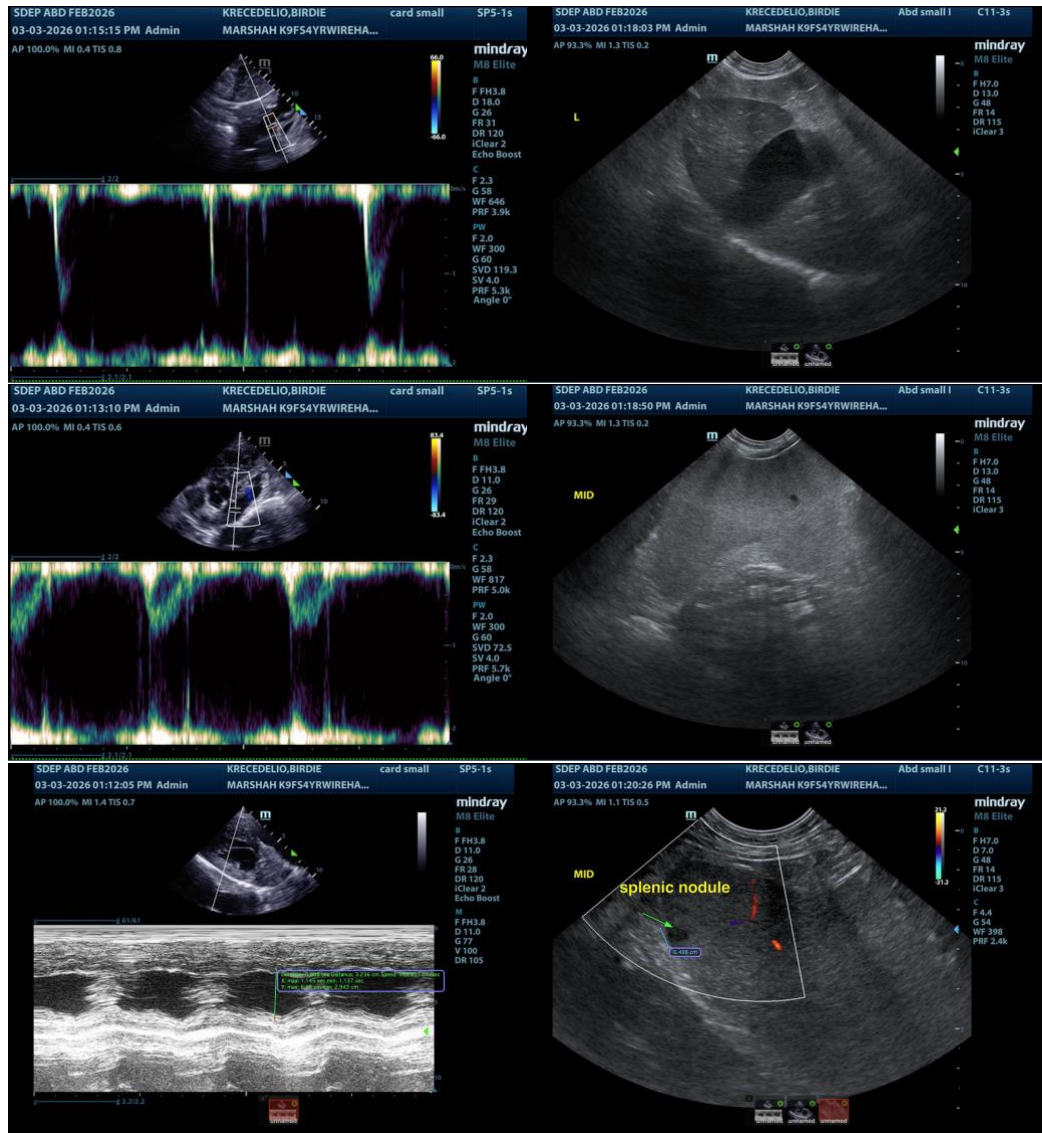
Dr. Armani

INVOICE

36072

DATE

3/3/26



The information and recommendations provided are based on the images presented by the referring veterinarian/sonographer. No evaluation can be communicated regarding pathology that was not visible in the image/video clips provided.

Thank you for this referral. If the clinical or image interpretation does not parallel your findings or if I can be of any further assistance please contact me.

Eric Lindquist, DMV, DABVP(CFM), Cert. IVUSS,
 CEO, Owner, Founder -- SonoPath.com
info@SonoPath.com