SonoPath
Clinical Sonography & Telecytology

EDUCATIONAL TELECONSULTATION SERVICES™

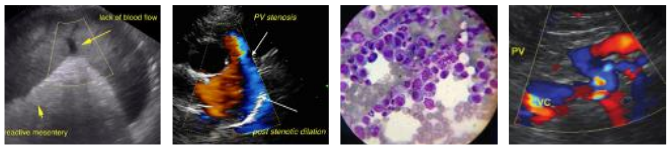

SonoPath.com
1-800-838-4268 info@sonopath.com

PATIENT

Sailor Morgan

SPECIES

Feline

BREED

DSH

SEX

Neutered Male

AGE

6

WEIGHT

11.3

INTERPRETED BY

Eric Lindquist, DMV
DABVP, Cert. IVUSS

IMAGING PERFORMED BY

Dr. Cassels-Conway

HOSPITAL NAME

Central Broward AH

REFERRING VET

Dr. Oms

INVOICE

21428

DATE

3/3/23

PRESENTING CLINICAL SIGNS

History: Hair loss ventrum + lateral limbs, sparse and patchy, no itching Otherwise well no c s v d active, excessive appetite, normal thirst and urination. Strictly indoor . Weight loss 2 # in 1 year. PE unremarkable

Abnormal PE/Chem/CBC/UA Results: Cbc-Wnl, Chem-calcium 10.9 H, U/a- sp g 1063 H, Ph- 8 H, prot 2+, struvite 4-10 H T4- 2.3 N renal tech- neg Keyscreen fecal PCR neg urine c/s and maldigestion profile pending Chest X-rays- wnl

ULTRASONOGRAPHIC EXAMINATION OF THE ABDOMEN

Urinary System

The **urinary bladder**, trigone, and pelvic urethra presented normal thicknesses and normal tone. The ureters were not visible which is normal. No uroliths or sediment were visualized and anechoic urine was present. No evidence of inflammatory or neoplastic changes were noted. Ureteral papillae were normal.

The **kidneys** revealed largely normal size and structure, corticomedullary definition and ratio (cortex 1/3 of medulla) were essentially maintained with some mild age-related loss of curvilinear patterns regarding the capsule and C/M junction. The cortices presented largely uniform texture with some increased echogenicity expected for his age patient. Medullary structure differed distinctly from that of the cortex and no evidence of pelvic dilation was present. The left kidney measured 4.3 cm. The right kidney measured 4.53 cm.

Adrenal Glands

Both **adrenal glands** were visualized and recognized as having normal shape, size, position and echogenicity for this breed. The phrenic vasculature, glandular echogenicity and detail were unremarkable. Capsule, cortex, and medullary definition were normal for this age patient. The right adrenal gland measured 0.26 cm. The left adrenal gland measured 1.04 cm x 0.41 cm.

Spleen

The **spleen** presented a smooth homogeneous parenchyma hyperechoic to liver and renal cortical parenchyma. The capsule was smooth without noticeable expansion or deviation from within the spleen or adjacent pathology. The splenic vasculature demonstrated normal volume without signs of congestion or thrombosis. No sonographic evidence of acute or chronic inflammatory, neoplastic, or infarctual changes were noted.

Liver

The **liver** images submitted revealed subjectively normal liver size, contour, and structure. Parenchymal echogenicity was naturally coarse and hypoechoic to the spleen. Vascular and biliary tracts were of normal volume with no evidence of congestion. The gallbladder presented acceptably thin walls with primarily anechoic content. The cystic and common bile ducts were normal. No pathological hepatic lymphadenopathy was evident. No overt structural evidence of inflammatory, infiltrative or regenerative pathology was evident.

Gastrointestinal

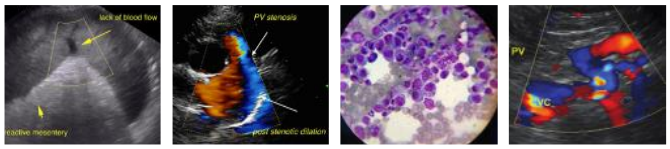

SonoPath.com
1-800-838-4268 info@sonopath.com

PATIENT

Sailor Morgan

SPECIES

Feline

BREED

DSH

SEX

Neutered Male

AGE

6

WEIGHT

11.3

INTERPRETED BY

Eric Lindquist, DMV
DABVP, Cert. IVUSS

IMAGING PERFORMED BY

Dr. Cassels-Conway

HOSPITAL NAME

Central Broward AH

REFERRING VET

Dr. Oms

INVOICE

21428

DATE

3/3/23

The **gastric** wall was thickened in this patient without overt neoplastic criteria. The gastric wall measured up to 9.0 mm. Some early loss of curvilinear patterns was noted. Minor small intestine thickening was noted with hypertrophied muscularis and increased submucosal echogenicity.

Pancreas

The base and limbs of the **pancreas** were observed to be largely isoechoic to surrounding omental fat. Some parenchymal remodeling, however, with mild deviation from curvilinear normalcy was observed. Pancreatic duct and capsular irregularities were present consistent with age related changes. If pain upon imaging (+ Murphy sign) was present or if the patient is focally painful in subxyphoid palpation then low-grade smoldering chronic pancreatitis should be suspected.

ULTRASONOGRAPHIC FINDINGS

- Mild chronic GI changes- no overt neoplastic criteria, however, cannot rule out emerging neoplastic state
- Age-related renal and pancreatic changes

INTERPRETATION OF THE FINDINGS & FURTHER RECOMMENDATIONS

Maldigestion panel, three view chest radiographs and full CNS examination is recommended to examine for occult disease that could be responsible for the weight loss. Evaluation for competitive eating environments should also be considered.

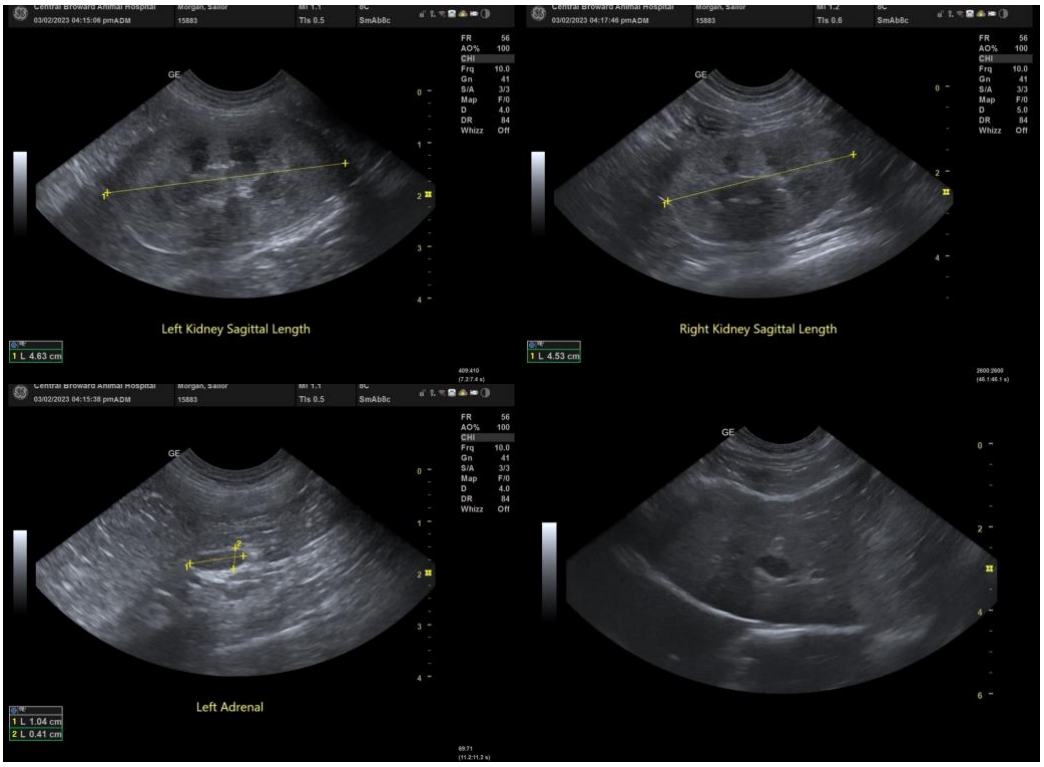

SonoPath
Clinical Sonography & Telecytology

EDUCATIONAL TELECONSULTATION SERVICES™

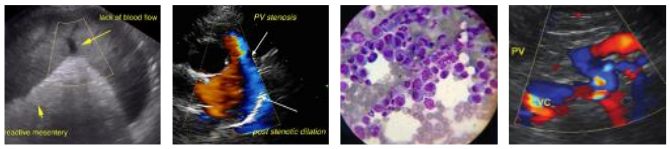

SonoPath.com
1-800-838-4268 info@sonopath.com

PATIENT

Sailor Morgan

SPECIES

Feline

BREED

DSH

SEX

Neutered Male

AGE

6

WEIGHT

11.3

INTERPRETED BY

Eric Lindquist, DMV
DABVP, Cert. IVUSS

IMAGING PERFORMED BY

Dr. Cassels-Conway

HOSPITAL NAME

Central Broward AH

REFERRING VET

Dr. Oms

INVOICE

21428

DATE

3/3/23

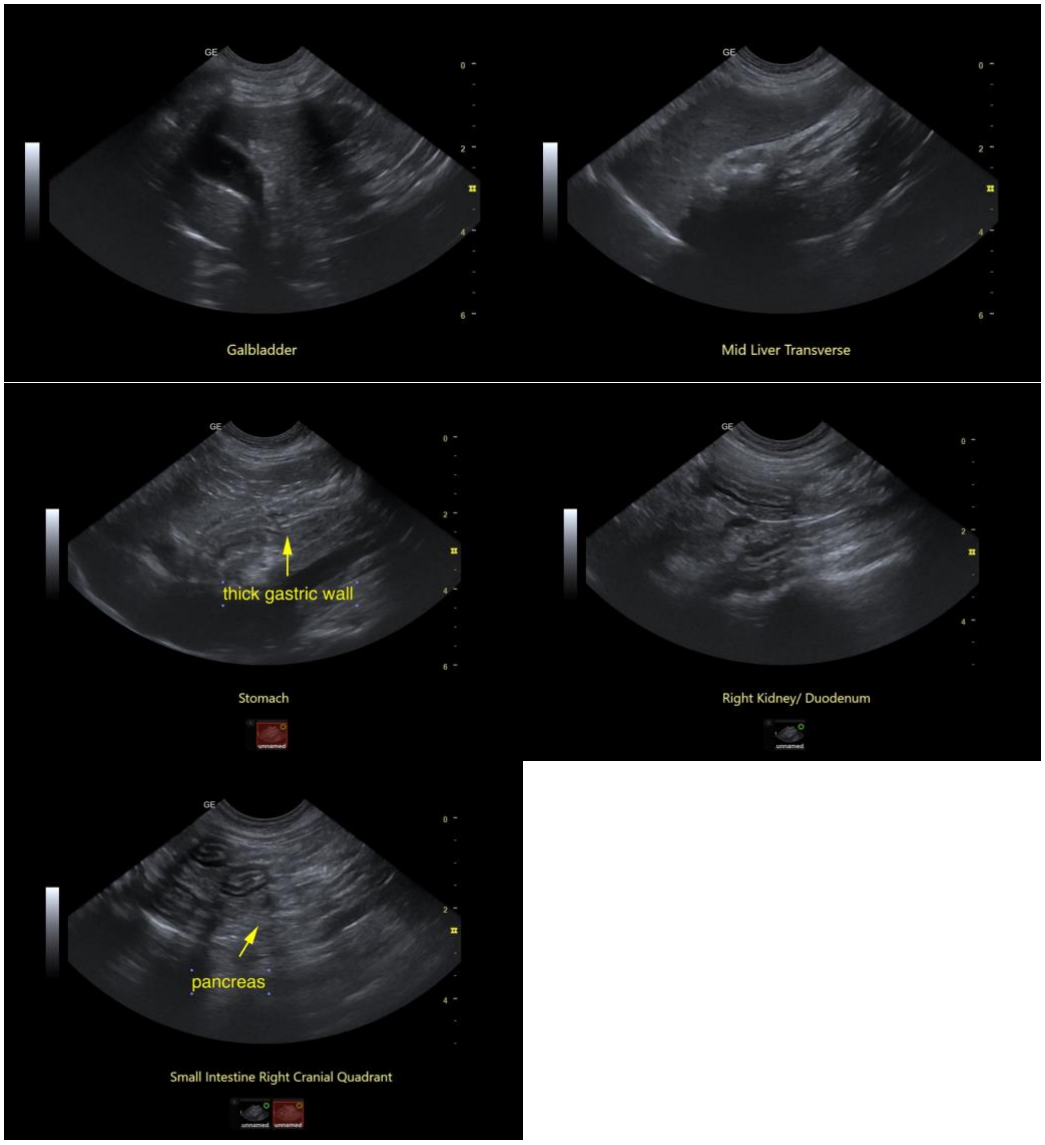

The information and recommendations provided are based on the images presented by the referring veterinarian. No evaluation can be communicated regarding pathology that was not visible in the image/video clips provided.

Thank you for this referral. If the clinical or image interpretation does not parallel your findings or if I can be of any further assistance please contact me.

Eric Lindquist, DMV, DABVP, Cert. IVUSS, CEO of SonoPath.com
info@SonoPath.com