



PATIENT PRESENTING CLINICAL SIGNS

Penelope Brigham

History: Practice US

SPECIES

Canine

Abnormal PE/Chem/CBC/UA Results: Bilaterally symmetrical truncal alopecia.

ULTRASONOGRAPHIC EXAMINATION OF THE HEART & ABDOMEN

BREED

Pitbull

SEX

Spayed Female

AGE

4

WEIGHT

55.8

CANINE CARDIAC PARAMETERS	MR VMAX (m/s)	TR VMAX (m/s)	LA/AO (Boon method)	LA/AO (Heart Base; Swe)	FS (%)	EF (%)	EPSS (cm)
NORMAL PARAMETER	4.5-5.5	<2.7	1.3	<1.3	28-40	40-100	<0.6
PATIENT	--	--	1.15	1.3	25	--	0.5
CANINE CARDIAC PARAMETERS	HR (BPM)	AV VMAX (m/s)	PV MAX (m/s)	BODY WEIGHT (kg)	LA 2D short axis Base view (cm)	LVIDd Avg; 2D and m-mode short axis (cm)	LVIDs Avg; 2D and m-mode short axis (cm)
NORMAL PARAMETER	50-100	0.7-1.7	0.7-1.6				
PATIENT	--	1.30	.70	--	--	3.5	--

INTERPRETED BY

Eric Lindquist, DMV
DABVP, Cert. IVUSS

IMAGING PERFORMED BY

Adrienne Waffle

HOSPITAL NAME

Torch Lake VC

REFERRING VET

Adrienne Waffle

INVOICE

21433

DATE

3/3/23

Cardiac Presentation

The echocardiogram in this patient demonstrated normal **left atrial** size based on 3 separate methods of LA evaluation. Trivial mitral insufficiency was noted in this patient, not clinically significant. The **left ventricle** presented thicknesses with linear contour and was not dilated nor restricted. The **myocardium** presented normal echogenicity without subjective evidence of significant fibrotic or ischemic disease. **Contractility** of the ventricular walls was adequate and in normal range for this patient evidenced by the fractional shortening measurement and subjective evaluation of the different regions of the myocardium. The **left ventricular outflow** tract demonstrated normal laminar flow and subjective structural integrity. The **right atrium** and auricle revealed normal size, structure and content. No evidence of masses was noted. **Tricuspid** valvular assessment demonstrated adequate linear morphology and kinesis. The **right ventricle** was of normal size (1/3 diameter of LV), chordae structure, myocardial echogenicity and thickness. **Pulmonary outflow** tract assessment revealed normal valve structure, laminar flow, and diameter (approx. 1:1 pa/ao ratio). No visible **pericardial** or free pleura fluid was noted. The cranial **mediastinum and pericardial and extra-cardiac regions** were free of masses in the visible window.

Urinary System

The **urinary bladder**, trigone, and pelvic urethra presented normal thicknesses and normal tone. The ureters were not visible which is normal. No uroliths or sediment were visualized and anechoic urine was present. No evidence of inflammatory or neoplastic changes were noted. Ureteral papillae were normal. The pelvic urethra was imaged 2.0 cm beyond the cystourethral junction.



PATIENT

Penelope Brigham

SPECIES

Canine

BREED

Pitbull

SEX

Spayed Female

AGE

4

WEIGHT

55.8

INTERPRETED BY

Eric Lindquist, DMV
DABVP, Cert. IVUSS

IMAGING PERFORMED BY

Adrienne Waffle

HOSPITAL NAME

Torch Lake VC

REFERRING VET

Adrienne Waffle

INVOICE

21433

DATE

3/3/23

The **kidneys** revealed largely normal size and structure, corticomedullary definition and ratio (cortex 1/3 of medulla) were essentially maintained with some moderate age-related loss of curvilinear patterns regarding the capsule and C/M junction. The cortices presented largely uniform texture with some increased echogenicity expected for his age patient. Medullary structure differed distinctly from that of the cortex. The right kidney measured 5.37 cm. The left kidney measured 5.2 cm. Pyelectasia was noted in the left kidney.

Adrenal Glands

Both **adrenal glands** were visualized and recognized as having normal shape, size, position and echogenicity for this breed. The phrenic vasculature, glandular echogenicity and detail were unremarkable. Capsule, cortex, and medullary definition were normal for this age patient. The right adrenal gland measured 3.15 cm x 0.57 cm at the cranial pole and 0.44 cm at the caudal pole. The left adrenal gland measured 3.28 cm x 0.62 cm at the caudal pole and 0.57 cm at the cranial pole.

Spleen

The **spleen** presented a smooth homogeneous parenchyma hyperechoic to liver and renal cortical parenchyma. The capsule was smooth without noticeable expansion or deviation from within the spleen or adjacent pathology. The splenic vasculature demonstrated normal volume without signs of congestion or thrombosis. No sonographic evidence of acute or chronic inflammatory, neoplastic, or infarctual changes were noted.

Liver

The **liver** images submitted revealed subjectively normal liver size, contour, and structure. Parenchymal echogenicity was naturally coarse and hypoechoic to the spleen. Vascular and biliary tracts were of normal volume with no evidence of congestion. The gallbladder presented acceptably thin walls with primarily anechoic content. The cystic and common bile ducts were normal. No pathological hepatic lymphadenopathy was evident. No overt structural evidence of inflammatory, infiltrative or regenerative pathology was evident.

Gastrointestinal

A minor amount of chyme was noted in the **stomach**. The small intestine and colon were unremarkable.

Pancreas

The base and limbs of the **pancreas** were observed to be largely isoechoic to surrounding omental fat. Pancreatic duct and capsular contour were acceptably normal and parenchyma respected normal curvilinear patterns. No overt evidence of active inflammatory or neoplastic disease was noted.

ULTRASONOGRAPHIC FINDINGS

- Mild to moderate degenerative renal changes with pyelectasia and cortical remodeling
- Minor chyme in the stomach
- Normal echocardiogram- no evidence of pathology

INTERPRETATION OF THE FINDINGS & FURTHER RECOMMENDATIONS

Full urinary work up is warranted if not already performed. No visceral disease noted that would be responsible for the alopecia.



PATIENT

Penelope Brigham

SPECIES

Canine

BREED

Pitbull

SEX

Spayed Female

AGE

4

WEIGHT

55.8

INTERPRETED BY

Eric Lindquist, DMV
DABVP, Cert. IVUSS

IMAGING PERFORMED BY

Adrienne Waffle

HOSPITAL NAME

Torch Lake VC

REFERRING VET

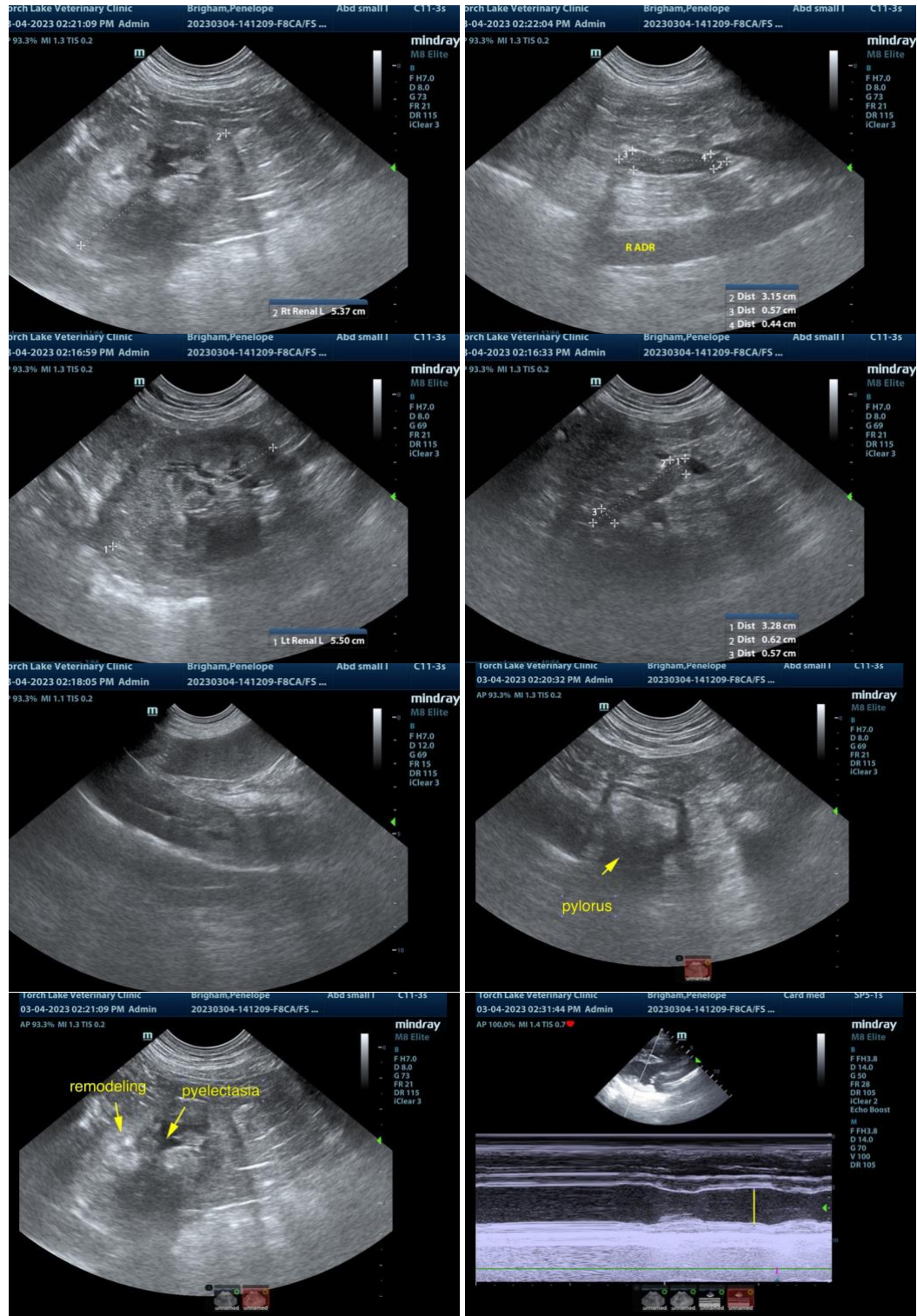
Adrienne Waffle

INVOICE

21433

DATE

3/3/23





PATIENT

Penelope Brigham

SPECIES

Canine

BREED

Pitbull

SEX

Spayed Female

AGE

4

WEIGHT

55.8

INTERPRETED BY

Eric Lindquist, DMV
DABVP, Cert. IVUSS

IMAGING PERFORMED BY

Adrienne Waffle

HOSPITAL NAME

Torch Lake VC

REFERRING VET

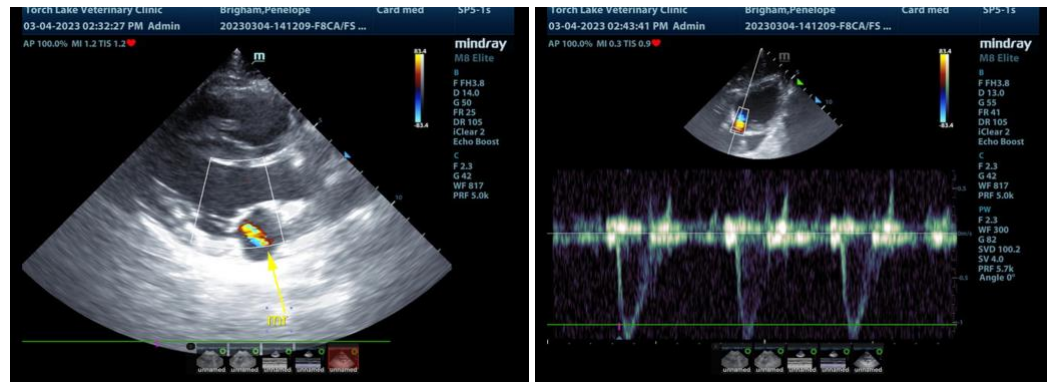
Adrienne Waffle

INVOICE

21433

DATE

3/3/23



The information and recommendations provided are based on the images presented by the referring veterinarian. No evaluation can be communicated regarding pathology that was not visible in the image/video clips provided.

Thank you for this referral. If the clinical or image interpretation does not parallel your findings or if I can be of any further assistance please contact me.

Eric Lindquist, DMV, DABVP, Cert. IVUSS, CEO of SonoPath.com
info@SonoPath.com