



**PATIENT**

Sylvie Schroeder

**SPECIES**

Canine

**BREED**

Border Collie

**SEX**

Spayed Female

**AGE**

9.5 Years

**WEIGHT**

49 Pounds

**INTERPRETED BY**

Eric Lindquist, DMV

DABVP, Cert. IVUSS

**IMAGING PERFORMED BY**

Dr. Judy Schroeder

**HOSPITAL NAME**

Animal Health Associates

**REFERRING VET**

Dr. Judy Schroeder

**INVOICE**

35905

**DATE**

3/3/22

**PRESENTING CLINICAL SIGNS**

Hyperlipidemia, cholesterolemia and elevated spec cPL. Inappropriate urination with large numbers of epithelial cells in urine. Not PU/PD. Several years ago patient had a severe case of pancreatitis that resolved with treatment. Normal CBC, T4. Hx of positive antibody to Anaplasma. Abnormal PE/Chem/CBC/UA Results: Overweight. Spec cPL 435 ug/dl. Cholesterol 449 mg/dl Triglycerides 1804 mg/dl (non fasting; fasting sample pending) Lipase 386 U/l WBCs 6-10/hpf, epithelial cells 2+, proteinuria (not quantified), ketonuria 1+, bilirubinuria 1+ (Culture pending).

**ULTRASONOGRAPHIC EXAMINATION OF THE ABDOMEN**

**Urinary System**

The **urinary bladder**, trigone, and pelvic urethra presented normal thicknesses and normal tone. The deep urethra presented no evidence of pathology. The ureters were not visible which is normal. No uroliths or sediment were visualized and anechoic urine was present. No evidence of inflammatory or neoplastic changes were noted. Ureteral papillae were normal. The pelvic urethra was imaged 3.0 cm beyond the cystourethral junction.

The **kidneys** revealed largely normal size and structure, corticomedullary definition and ratio (cortex 1/3 of medulla) were essentially maintained with some age-related loss of curvilinear patterns regarding the capsule and C/M junction. The cortices presented largely uniform texture with some increased echogenicity expected for his age patient. Medullary structure differed distinctly from that of the cortex and no evidence of pelvic dilation was present. The right kidney measured 6.09 cm. The left kidney measured 5.86 cm.

**Adrenal Glands**

Both **adrenal glands** were visualized and recognized as having normal shape, size, position and echogenicity for this breed. The phrenic vasculature, glandular echogenicity and detail were unremarkable. Capsule, cortex, and medullary definition were normal for this age patient. The left adrenal gland measured 0.51 cm. The region of the right adrenal gland was unremarkable.

**Spleen**

The **spleen** presented a smooth homogeneous parenchyma hyperechoic to liver and renal cortical parenchyma. The capsule was smooth without noticeable expansion or deviation from within the spleen or adjacent pathology. The splenic vasculature demonstrated normal volume without signs of congestion or thrombosis. No sonographic evidence of acute or chronic inflammatory, neoplastic, or infarctual changes were noted.

**Liver**

The **liver** was uniformly swollen with minor, excessive gallbladder debris and over distension with dependent and suspended bile without evidence of overt mucocele formation. However, excessive sludge was present. The liver presented coarse architecture with mildly increased portal markings and subtle, mixed echogenic changes. This is consistent with vacuolar hepatopathy and some level of remodeling and history of inflammatory component. There was no overt suspicion of neoplasia.

**Gastrointestinal**

Examination of the **gastrointestinal tract** revealed a stomach and intestine free of stasis, of normal wall thickness, acceptable curvilinear mural detail, and peristaltic activity. Small and large intestine demonstrated normal luminal chyme and stool consistency respectively. No obstructive or overt infiltrative disease was noted. No associated abnormal lymphatic activity was noted.



**PATIENT**

Sylvie Schroeder

**SPECIES**

Canine

**BREED**

Border Collie

**SEX**

Spayed Female

**AGE**

9.5 Years

**WEIGHT**

49 Pounds

**INTERPRETED BY**

Eric Lindquist, DMV

DABVP, Cert. IVUSS

**IMAGING PERFORMED BY**

Dr. Judy Schroeder

**HOSPITAL NAME**

Animal Health Associates

**REFERRING VET**

Dr. Judy Schroeder

**INVOICE**

35905

**DATE**

3/3/22

**Pancreas**

The base and limbs of the **pancreas** were observed to be largely isoechoic to surrounding omental fat. Pancreatic duct and capsular contour were acceptably normal and parenchyma respected normal curvilinear patterns. No overt evidence of active inflammatory or neoplastic disease was noted.

**ULTRASONOGRAPHIC FINDINGS**

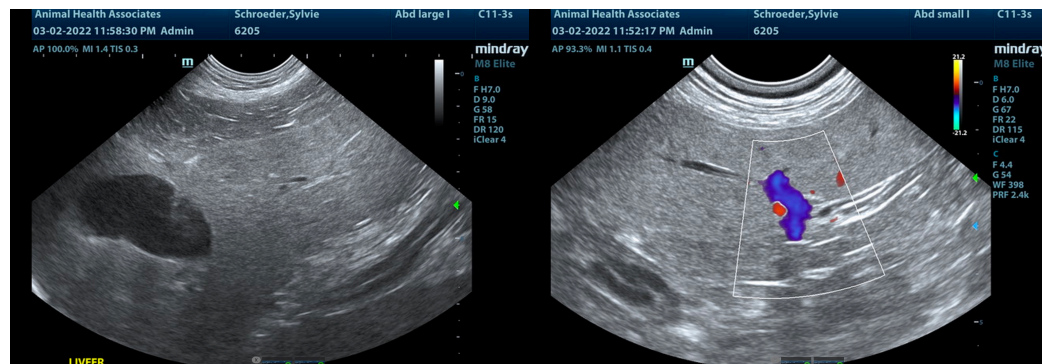
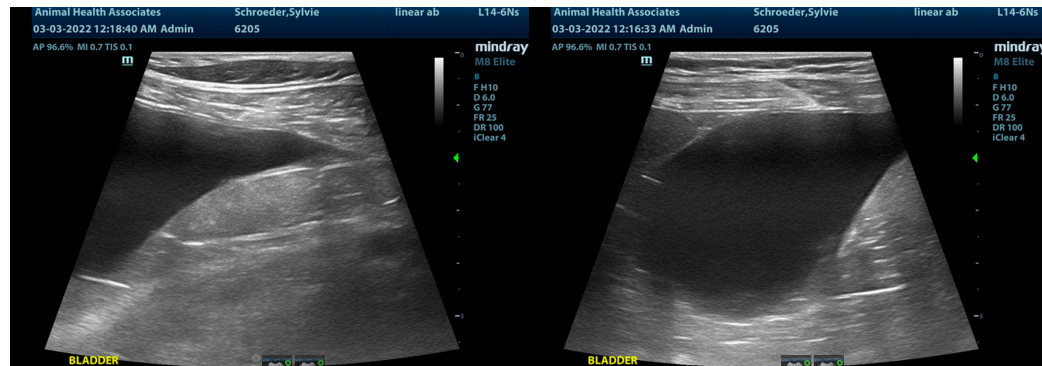
- Minor age related renal changes
- Structurally normal lower urinary tract

**INTERPRETATION OF THE FINDINGS & FURTHER RECOMMENDATIONS**

No evidence of pathology.

**Chronic UTI Protocol**

I recommend **Enrofloxacin** (5-10 mg/kg SID PO) (In patients > 1 year of age) in late pm after urination to maximize urinary concentrations overnight. This assumes that culture supports this use. Repeat **culture** at 3-4 weeks and continue treatment at least 7-10 days post negative urinary sediment and negative culture. *Note: Negative culture does not necessarily mean lack of UTI.* Other favorite antibiotics for chronic UTI include third generation Cefa (Ceftiafur or similar s.i.d. injectable) or Clavamox. If suspicion of occult urinary incontinence is present then **phenylpropanolamine (PPA)** (1-2 mg/kg BID) can be employed long term to enhance urethral tone.





**PATIENT**

Sylvie Schroeder

**SPECIES**

Canine

**BREED**

Border Collie

**SEX**

Spayed Female

**AGE**

9.5 Years

**WEIGHT**

49 Pounds

**INTERPRETED BY**

Eric Lindquist, DMV  
DABVP, Cert. IVUSS

**IMAGING PERFORMED BY**

Dr. Judy Schroeder

**HOSPITAL NAME**

Animal Health  
Associates

**REFERRING VET**

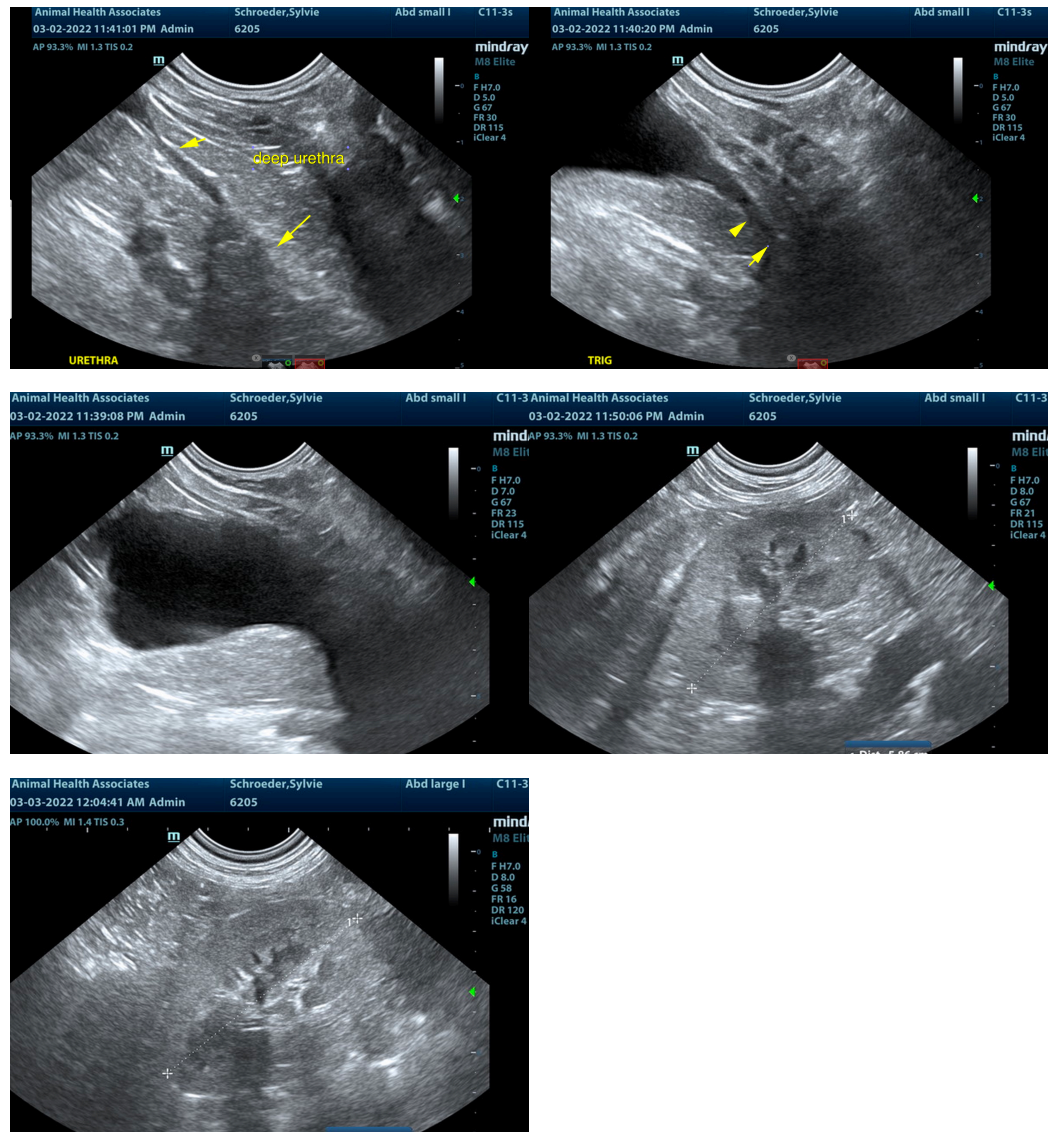
Dr. Judy Schroeder

**INVOICE**

35905

**DATE**

3/3/22



The information and recommendations provided are based on the images presented by the referring veterinarian/sonographer. No evaluation can be communicated regarding pathology that was not visible in the image/video clips provided.

Thank you for this referral. If the clinical or image interpretation does not parallel your findings or if I can be of any further assistance please contact me.

**Eric Lindquist, DMV, DABVP, Cert. IVUSS, CEO of SonoPath.com**

[info@SonoPath.com](mailto:info@SonoPath.com)