

**DATE PRESENTING CLINICAL SIGNS**

3/3/22

Vomiting and about ½ pound weight loss in a cat that has always been slim. Since treatment mid Feb with Cerenia pet has not vomited, but still lethargic.

PATIENT

Sophie Wilson

Current Medications: Cerenia 16mg- ½ SID.

Lab Results: see attached.

Date of Previous IntraPet Ultrasound: No previous.

Sedation: Dexdomitor/Torbugesic IV.

Stat Report: Not requested.

SPECIES

Feline

ULTRASONOGRAPHIC EXAMINATION OF THE ABDOMEN**BREED****Urinary System**

DSH

The **urinary bladder**, trigone, and pelvic urethra presented normal thicknesses and normal tone. The ureters were not visible which is normal. No uroliths or sediment were visualized and anechoic urine was present. No evidence of inflammatory or neoplastic changes were noted. Ureteral papillae were normal.

SEX

Spayed Female

The **kidneys** revealed normal size and structure, corticomedullary definition and ratio for this age. The cortices presented largely uniform texture with normal echogenic relationship to liver and spleen. Medullary structure differed distinctly from the cortex and no evidence of pelvic dilation was present. The capsules were acceptably uniform without significant irregularities. The right kidney measured 3.55 cm. The left kidney measured 3.66 cm.

AGE

8/25/14

WEIGHT

6.69 Pounds

Adrenal Glands**INTERPRETED BY**

Eric Lindquist, DMV
DABVP, Cert. IVUSS

Both **adrenal glands** were visualized and recognized as having normal shape, size, position and echogenicity for this breed. The phrenic vasculature, glandular echogenicity and detail were unremarkable. Capsule, cortex, and medullary definition were normal for this age patient. The left adrenal gland measured 0.27 cm.

Spleen**IMAGING PERFORMED BY**

Stephanie Pearce
RDMS, RVT

The **spleen** was enlarged with scalloping contour and was folded upon itself, measuring 1.3 cm in width.

Liver**HOSPITAL NAME**

Everhart VH

The **liver** images submitted revealed subjectively normal liver size, contour, and structure. Parenchymal echogenicity was naturally coarse and hypoechoic to the spleen. Vascular and biliary tracts were of normal volume with no evidence of congestion. The gallbladder presented acceptably thin walls with primarily anechoic content. The cystic and common bile ducts were normal. No pathological hepatic lymphadenopathy was evident. No overt structural evidence of inflammatory, infiltrative or regenerative pathology was evident.

REFERRING VET

Dr. DeFavero

Gastrointestinal**INVOICE**

35907

Examination of the **gastrointestinal tract** revealed a stomach and intestine free of stasis, of normal wall thickness, acceptable curvilinear mural detail, and peristaltic activity. Small and large intestine demonstrated normal luminal chyme and stool consistency respectively. No obstructive or overt infiltrative disease was noted. No associated abnormal lymphatic activity was noted.

Pancreas

The base and limbs of the **pancreas** were observed to be largely isoechoic to surrounding omental fat. Pancreatic duct and capsular contour were acceptably normal and parenchyma respected normal curvilinear patterns. No overt evidence of active inflammatory or neoplastic disease was noted.

Free Abdomen

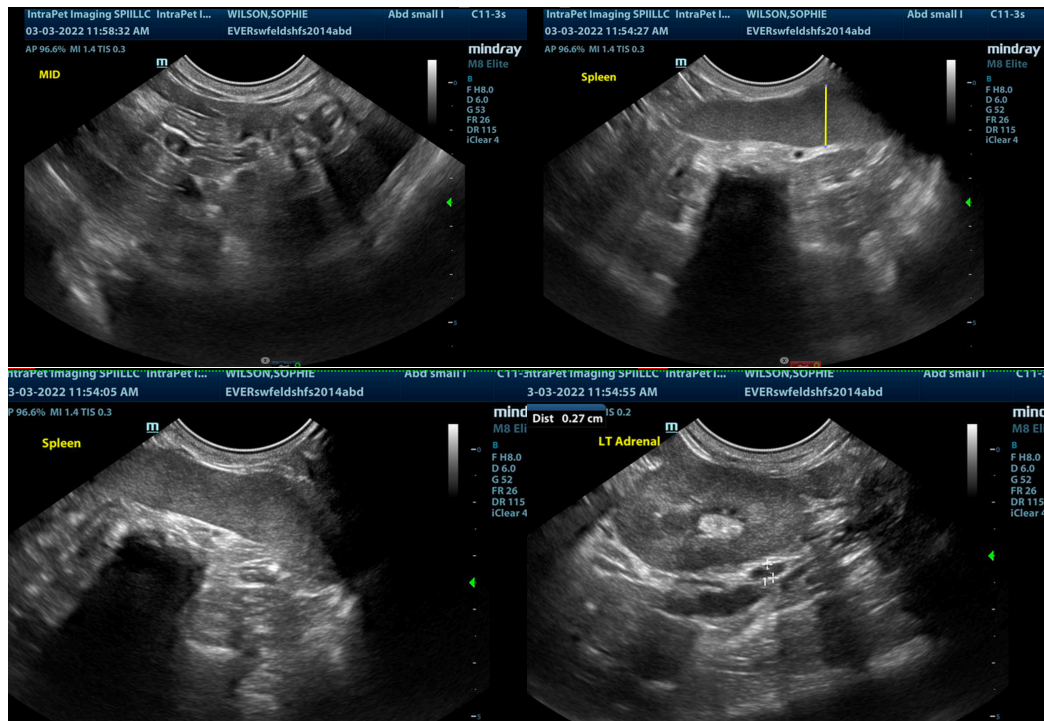
A cranial abdominal lymph node was enlarged, measuring 1.64 cm x 0.6 cm.

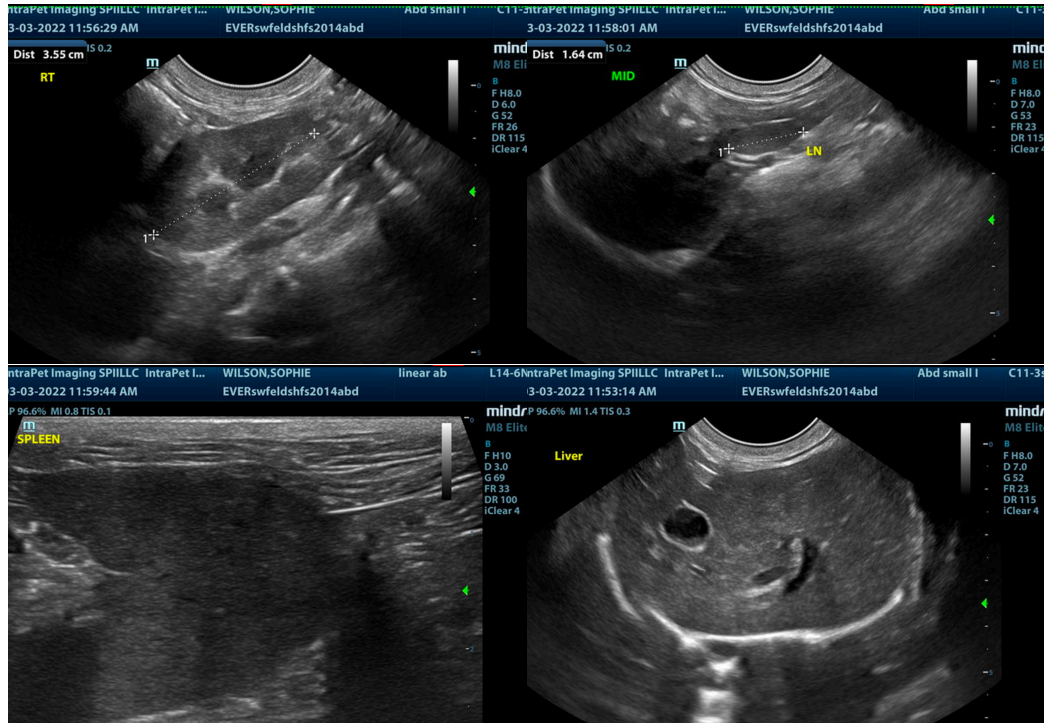
ULTRASONOGRAPHIC FINDINGS

- Mild splenic enlargement with slight scalloping contour
- Unremarkable abdomen otherwise.

INTERPRETATION OF THE FINDINGS & FURTHER RECOMMENDATIONS

Likely reactive state. However, given the patient history, FNA of the spleen would be warranted to ensure an emerging lymphoma or similar neoplasia is not present. Maldigestion panel, three view chest radiographs and full CNS examination is recommended to examine for occult disease that could be responsible for the weight loss. Evaluation for competitive eating environments should also be considered. Underlying dietary intolerance possibly an issue if neoplasia is not found on splenic FNA.





The information and recommendations provided are based on the images presented by the referring veterinarian. No evaluation can be communicated regarding pathology that was not visible in the image/video clips provided.

Thank you for this referral. If the clinical or image interpretation does not parallel your findings or if I can be of any further assistance please contact me.

Eric Lindquist, DMV, DABVP, Cert. IVUSS, CEO of SonoPath.com
info@SonoPath.com