



PATIENT

Martin Tilson

SPECIES

Feline

BREED

DSH

SEX

Neutered Male

AGE

9 Years

WEIGHT

9.88 Pounds

INTERPRETED BY

Eric Lindquist, DMV

DABVP, Cert. IVUSS

IMAGING PERFORMED BY

Dr. Judy Schroeder

HOSPITAL NAME

Animal Health Associates

REFERRING VET

Dr. Judy Schroeder

INVOICE

35903

DATE

3/3/22

PRESENTING CLINICAL SIGNS

Chronic vomiting. Patient was seen in January of this year for 1 month history of vomiting daily. Lab work was normal and patient was placed on course of Cerenia and Famotidine. Once medication was stopped, vomiting recurred. Abdominal rads taken, radiologist was concerned about possible gastric mural mass or thickening.

Abnormal PE/Chem/CBC/UA Results: Heart murmur. Mild neutrophilia. Normal Spec fPL.

VD radiograph: Concentric gastric wall thickening.

ULTRASONOGRAPHIC EXAMINATION OF THE ABDOMEN

Urinary System

The **urinary bladder**, trigone, and pelvic urethra presented normal thicknesses and normal tone. The ureters were not visible which is normal. No uroliths or sediment were visualized and anechoic urine was present. No evidence of inflammatory or neoplastic changes were noted. Ureteral papillae were normal. The pelvic urethra was imaged 2.0 cm beyond the cystourethral junction.

The **kidneys** revealed normal size and structure, corticomedullary definition and ratio for this age. The cortices presented largely uniform texture with normal echogenic relationship to liver and spleen. Medullary structure differed distinctly from the cortex and no evidence of pelvic dilation was present. The capsules were acceptably uniform without significant irregularities. The left kidney measured 3.7 cm. The right kidney measured 3.85 cm. Blood flow to the kidneys appeared to be adequate.

Adrenal Glands

Both **adrenal glands** were visualized and recognized as having normal shape, size, position and echogenicity for this breed. The phrenic vasculature, glandular echogenicity and detail were unremarkable. Capsule, cortex, and medullary definition were normal for this age patient. The left adrenal gland measured 0.41 cm.

Spleen

The **spleen** presented a smooth homogeneous parenchyma hyperechoic to liver and renal cortical parenchyma. The capsule was smooth without noticeable expansion or deviation from within the spleen or adjacent pathology. The splenic vasculature demonstrated normal volume without signs of congestion or thrombosis. No sonographic evidence of acute or chronic inflammatory, neoplastic, or infarctual changes were noted.

Liver

The **liver** images submitted revealed subjectively normal liver size, contour, and structure. Parenchymal echogenicity was naturally coarse and hypoechoic to the spleen. Vascular and biliary tracts were of normal volume with no evidence of congestion. The gallbladder presented acceptably thin walls with primarily anechoic content. The cystic and common bile ducts were normal. No pathological hepatic lymphadenopathy was evident. No overt structural evidence of inflammatory, infiltrative or regenerative pathology was evident.

Gastrointestinal

The **gastric** mucosa was mildly thickened without loss of mural detail. Submucosal layer was intact. The lumen of the stomach was empty. The small intestine and colon were unremarkable.



PATIENT

Pancreas

Martin Tilson

The base and limbs of the **pancreas** were observed to be largely isoechoic to surrounding omental fat. Pancreatic duct and capsular contour were acceptably normal and parenchyma respected normal curvilinear patterns. No overt evidence of active inflammatory or neoplastic disease was noted. Reactive pancreatic lymph nodes noted, measuring 0.92 cm and 0.73 cm.

SPECIES

Feline

ULTRASONOGRAPHIC FINDINGS

- Minor gastric hypertrophy and slight regional reactive lymph nodes

BREED

DSH

INTERPRETATION OF THE FINDINGS & FURTHER RECOMMENDATIONS

SEX

Neutered Male

No overt neoplastic criteria. Inflammatory bowel/gastritis suspected. However, cannot rule out an emerging round cell neoplastic event. If clinical signs persist despite medical management, then recheck sonogram would be indicated in 10-14 days. A clinical trial of the following may prove effective.

AGE

9 Years

Triaditis/Pancreatitis protocol

Part or all of this protocol may be considered based on your clinical impression of the patient:

WEIGHT

9.88 Pounds

Recommend pain management when anorexic with **Buprenorphine** (0.01-0.02 mg/kg IM or SC), clinical trial of **Zithromax** (50 mg sid/cat x 10 days, 3 weeks if bartonella +), **Prednisolone** (0.5-2 mg/kg tapering over 1 week to minimal effective dose), and **B12 injections** if weight loss (Cyanobalamine 250 mcg sub-q once-weekly x six weeks, then every other week for six weeks and then once-monthly, long-term if necessary), **novel-protein or hydrolyzed diet** (*Hydrolyzed diets have been shown to be more effective in dietary intolerance case management compared to hypoallergenic diets*) or the **magical Purina DM** (changing protein source is crucial and may need rotation every 6 months if clinical signs recur) Diet trials is a whatever works phenomenon. If vomiting becomes a persistent issue then endoscopy would be warranted and/or recheck sonogram to assess more emerging disease. One diet does not work for all patients so different trials may be necessary or protein source rotation every 6 months as new sensitivities develop.

INTERPRETED BY

Eric Lindquist, DMV

DABVP, Cert. IVUSS

IMAGING PERFORMED BY

Dr. Judy Schroeder

HOSPITAL NAME

Animal Health Associates

REFERRING VET

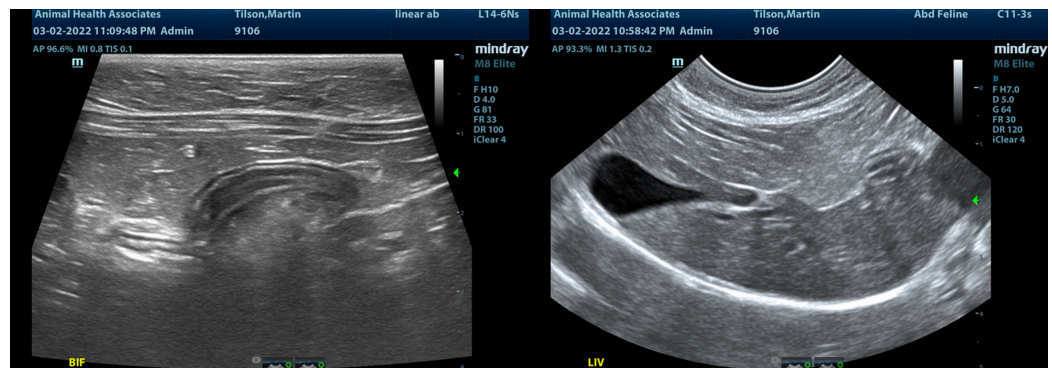
Dr. Judy Schroeder

INVOICE

35903

DATE

3/3/22





PATIENT

Martin Tilson

SPECIES

Feline

BREED

DSH

SEX

Neutered Male

AGE

9 Years

WEIGHT

9.88 Pounds

INTERPRETED BY

Eric Lindquist, DMV
DABVP, Cert. IVUSS

IMAGING PERFORMED BY

Dr. Judy Schroeder

HOSPITAL NAME

Animal Health
Associates

REFERRING VET

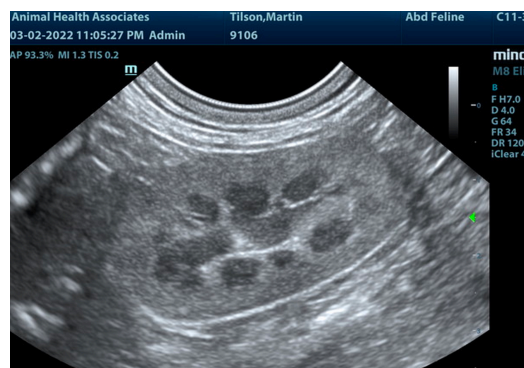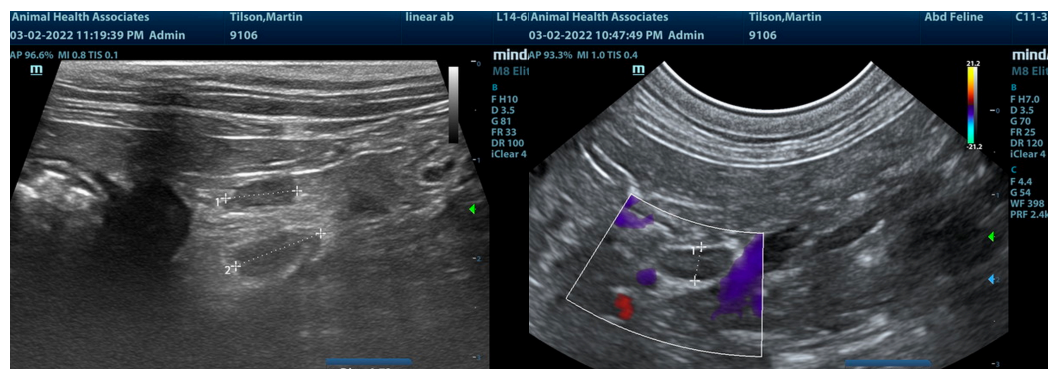
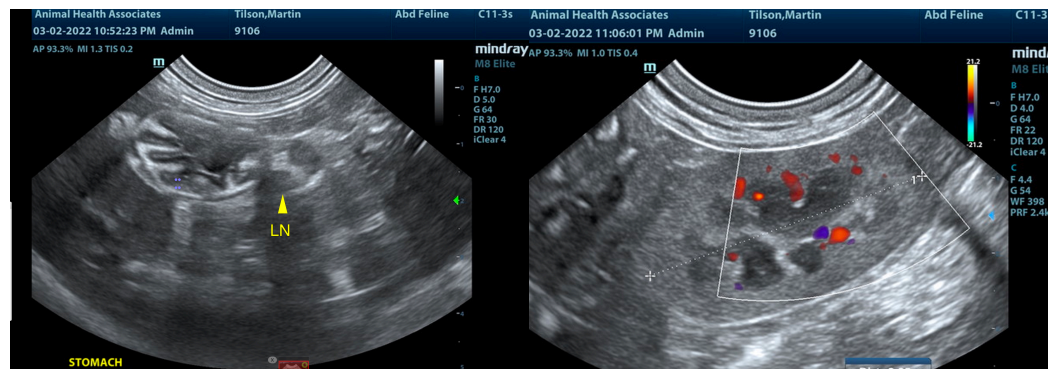
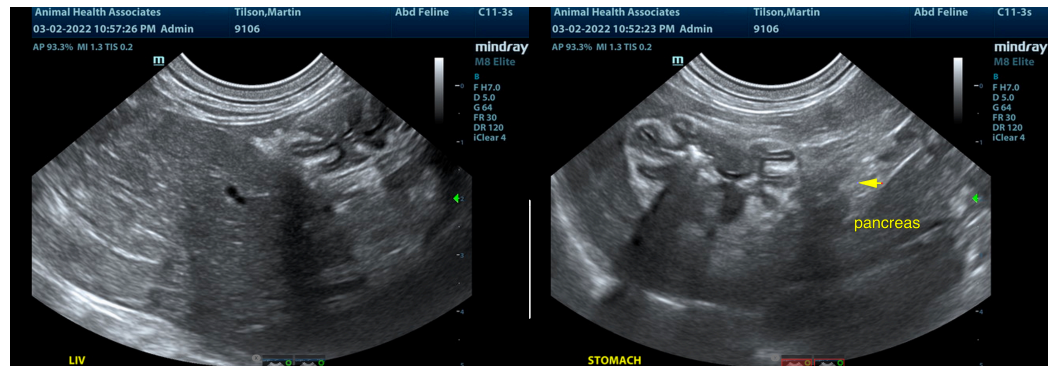
Dr. Judy Schroeder

INVOICE

35903

DATE

3/3/22





PATIENT

Martin Tilson

The information and recommendations provided are based on the images presented by the referring veterinarian/sonographer. No evaluation can be communicated regarding pathology that was not visible in the image/video clips provided.

SPECIES

Feline

Thank you for this referral. If the clinical or image interpretation does not parallel your findings or if I can be of any further assistance please contact me.

Eric Lindquist, DMV, DABVP, Cert. IVUSS, CEO of SonoPath.com

info@SonoPath.com

BREED

DSH

SEX

Neutered Male

AGE

9 Years

WEIGHT

9.88 Pounds

INTERPRETED BY

Eric Lindquist, DMV

DABVP, Cert. IVUSS

IMAGING PERFORMED BY

Dr. Judy Schroeder

HOSPITAL NAME

Animal Health
Associates

REFERRING VET

Dr. Judy Schroeder

INVOICE

35903

DATE

3/3/22