

IMAGING PERFORMED BY

IntraPet.com



**SonoPath**

Clinical Sonography & Telectology

EDUCATIONAL TELECONSULTATION SERVICES™

1-800-838-4268 info@sonopath.com SonoPath.com

**DATE PRESENTING CLINICAL SIGNS**

3/3/22

Diarrhea with mucous ongoing- did not improve with Metronidazole or Provable. PE: Malka was BAR on presentation. Her MMs were pink and moist, CRT <2 seconds. No murmur or arrhythmia noted on auscultation. Normal bronchovesicular sounds appreciated throughout the lung fields. Abdominal palpation was comfortable and unremarkable. Remainder of PE was WNL.

**PATIENT**

Malka Nathan

**SPECIES**

Canine

**BREED**

Beagle

**SEX**

Spayed Female

**AGE**

9/9/12

**WEIGHT**

41 Pounds

**INTERPRETED BY**

Eric Lindquist, DMV  
DABVP, Cert. IVUSS

**IMAGING PERFORMED BY**

Rachel Brilhart RDMS

**HOSPITAL NAME**

Severna Park VH

**REFERRING VET**

Dr. Storm

**INVOICE**

35887

Current Medications: Tylan powder (per tsp) give 1/8 tsp SID for 10 days, ID Canine Cans, Provable Capsules- 1 SID for 10 days.

Lab Results: Fecal- negative.

Date of Previous IntraPet Ultrasound: No previous.

Sedation: Not required to complete full diagnostic ultrasound.

Stat Report: Not requested.

**ULTRASONOGRAPHIC EXAMINATION OF THE ABDOMEN**

**Urinary System**

The **urinary bladder**, trigone, and pelvic urethra presented normal thicknesses and normal tone. The ureters were not visible which is normal. No uroliths or sediment were visualized and anechoic urine was present. No evidence of inflammatory or neoplastic changes were noted. Ureteral papillae were normal.

The **kidneys** revealed normal size and structure, corticomedullary definition and ratio for this age. The cortices presented largely uniform texture with normal echogenic relationship to liver and spleen. Medullary structure differed distinctly from the cortex and no evidence of pelvic dilation was present. The capsules were acceptably uniform without significant irregularities. The right kidney measured 5.09 cm.

**Adrenal Glands**

Both **adrenal glands** were visualized and recognized as having normal shape, size, position and echogenicity for this breed. The phrenic vasculature, glandular echogenicity and detail were unremarkable. Capsule, cortex, and medullary definition were normal for this age patient. The left adrenal gland measured 2.28 cm x 0.60 cm at the caudal pole and 0.56 cm at the cranial pole. The right adrenal gland measured 1.85 cm x 0.53 cm at the caudal pole and 0.67 cm at the cranial pole.

**Spleen**

The **spleen** presented slight micronodular changes, likely hyperplasia, appears subjectively benign.

**Liver**

The **liver** images from right and left intercostal as well as subcostal views revealed subjectively normal liver size, contour, and structure. Some age-related parenchymal remodeling was noted but likely not clinically significant at this time. Vascular and biliary tracts were of normal volume and no evidence of congestion was noted. The gallbladder presented some dependent debris with essentially normal contour. The cystic and common bile ducts were normal. No overt evidence of active inflammatory, infiltrative or regenerative pathology was noted but should be paired with current or past LE elevations regarding any clinical significance to this presentation. The hepatic lymph nodes were unremarkable.

## ***Gastrointestinal***

The **gastrointestinal tract** revealed diffuse, hyperechoic fogging or overlay throughout the small intestine as well as areas of mucosal striations and speckling. This striation + fogging effect appeared to exclusively affect the mucosal layer with the submucosa, muscularis and serosa left in-tact. An obstructive clumping of soft shadowing material was noted in the small intestine measuring 1.4 cm x 2.5 cm. The foreign matter is likely fluid absorbing, given that not a large amount of fluid was noted prior to the passing structure. Reactive mesentery was present associated with the serosa indicative of active inflammation. This is most consistent with protein losing enteropathy/lymphangectasia. Full thickness biopsies or endoscopy guided biopsies would be ideal to confirm. No obstructive disease or obvious suspicion of neoplasia. Slight areas of free fluid noted. The stomach was empty.

## ***Pancreas***

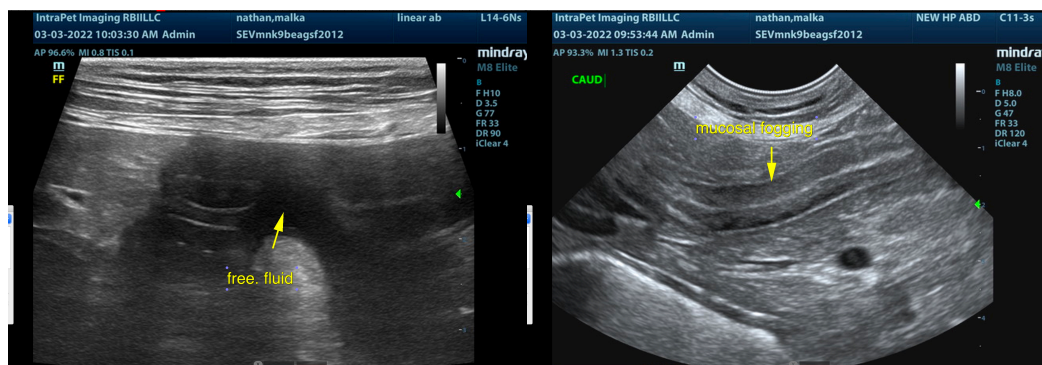
The base and limbs of the **pancreas** were observed to be largely isoechoic to surrounding omental fat. Some parenchymal remodeling, however, with mild deviation from curvilinear normalcy was observed. Pancreatic duct and capsular irregularities were present consistent with age related changes. If pain upon imaging (+ Murphy sign) was present or if the patient is focally painful in subxyphoid palpation then low-grade smoldering chronic pancreatitis should be suspected.

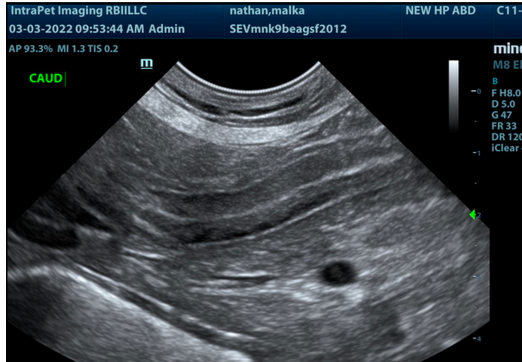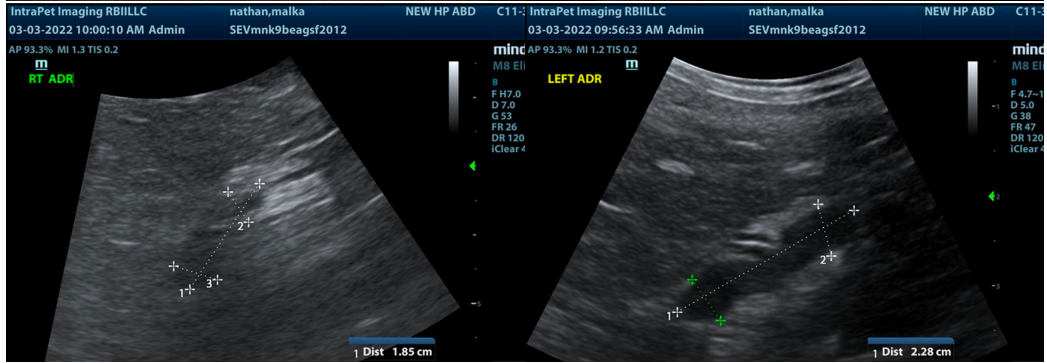
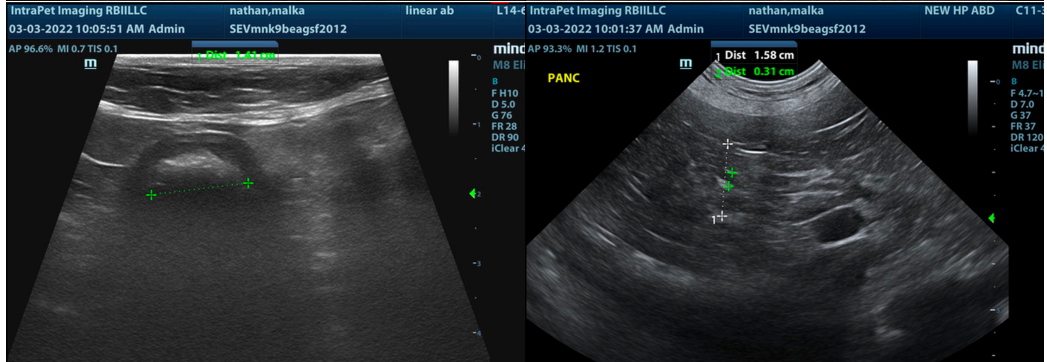
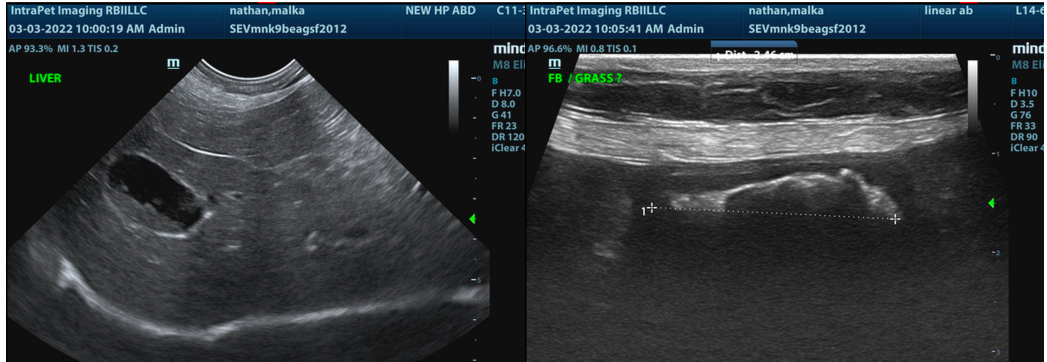
## **ULTRASONOGRAPHIC FINDINGS**

- Soft shadowing small intestinal foreign matter (distal small intestinal position) with areas of mucosal fogging in the small intestine, no evidence of neoplasia

## **INTERPRETATION OF THE FINDINGS & FURTHER RECOMMENDATIONS**

Recommend exploratory surgery with expectation of liberating the foreign matter, inspecting the cause of free fluid, as well as obtaining intestinal biopsies. I strongly recommend immediate sonogram just prior to surgery to ensure that the material has not passed into the colon with medical management. However, underlying GI disease is suspected and reactive mesentery and localized peritonitis best describes the immediate pattern.





**The information and recommendations provided are based on the images presented by the referring veterinarian. No evaluation can be communicated regarding pathology that was not visible in the image/video clips provided.**

Thank you for this referral. If the clinical or image interpretation does not parallel your findings or if I can be of any further assistance please contact me.

**Eric Lindquist**, DMV, DABVP, Cert. IVUSS, CEO of SonoPath.com  
[info@SonoPath.com](mailto:info@SonoPath.com)