

PATIENT

Blade Riley

PRESENTING CLINICAL SIGNS

Limited exam - recheck prostate on Finasteride 1mg 1 tab daily
Abnormal PE/Chem/CBC/UA Results: previous AUS attached - BPH prostate 4.33 cm

SPECIES

Canine

LIMITED ULTRASONOGRAPHIC EXAMINATION

Urinary System

BREED

Shepherd X

The urinary bladder, trigone, and pelvic urethra presented normal thicknesses and normal tone. The ureters were not visible which is normal. No uroliths or sediment were visualized and anechoic urine was present. No evidence of inflammatory or neoplastic changes were noted. Ureteral papillae were normal.

SEX

Intact Male

The prostate revealed persistent heterogeneous parenchymal changes with a maximum width of 4.6 cm. The prostate appears to be stable, yet no significant improvement compared to the prior sonogram. No inflammation present.

AGE

5 Years

The kidneys revealed normal size and structure, corticomedullary definition and ratio for this age. The cortices presented largely uniform texture with normal echogenic relationship to liver and spleen. Medullary structure differed distinctly from the cortex and no evidence of pelvic dilation was present. The capsules were acceptably uniform without significant irregularities. Similar to prior sonogram.

WEIGHT

105 Pounds

ULTRASONOGRAPHIC FINDINGS

- Persistent BPH prostate - appears stable.

INTERPRETATION OF THE FINDINGS & FURTHER RECOMMENDATIONS

INTERPRETED BY

Eric Lindquist, DMV
DABVP, Cert IVUSS

Essentially similar to prior sonogram. Subjectively reduced inflammatory pattern. If the patient is non-clinical, then recommend continuation of the current protocol and recheck sonogram in 6 months, earlier if clinical signs initiate.

IMAGING PERFORMED BY

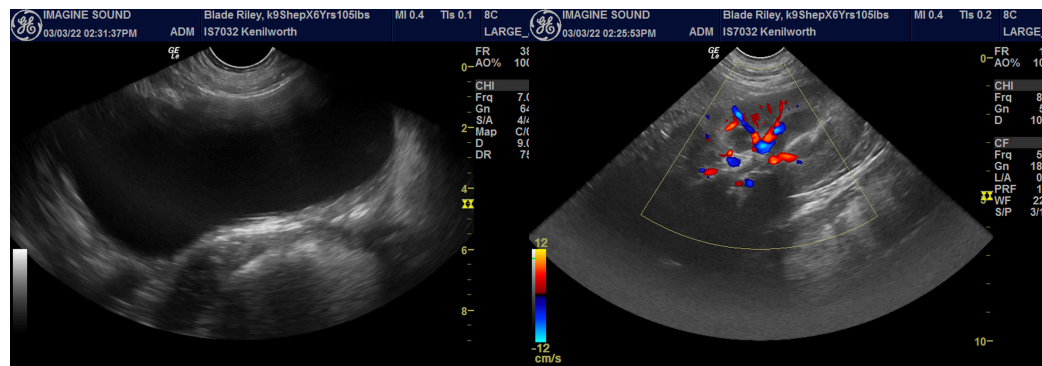
Denise Bruno, LVT,
RDMS

HOSPITAL NAME

Kenilworth AH

REFERRING VET

Dr. Mansour

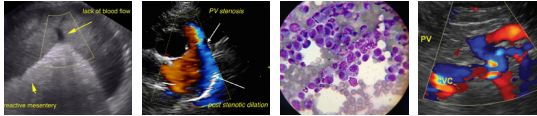


INVOICE

35904

DATE

3/3/22



PATIENT

Blade Riley

SPECIES

Canine

BREED

Shepherd X

SEX

Intact Male

AGE

5 Years

WEIGHT

105 Pounds

INTERPRETED BY

Eric Lindquist, DMV
DABVP, Cert IVUSS

IMAGING PERFORMED BY

Denise Bruno, LVT,
RDMS

HOSPITAL NAME

Kenilworth AH

REFERRING VET

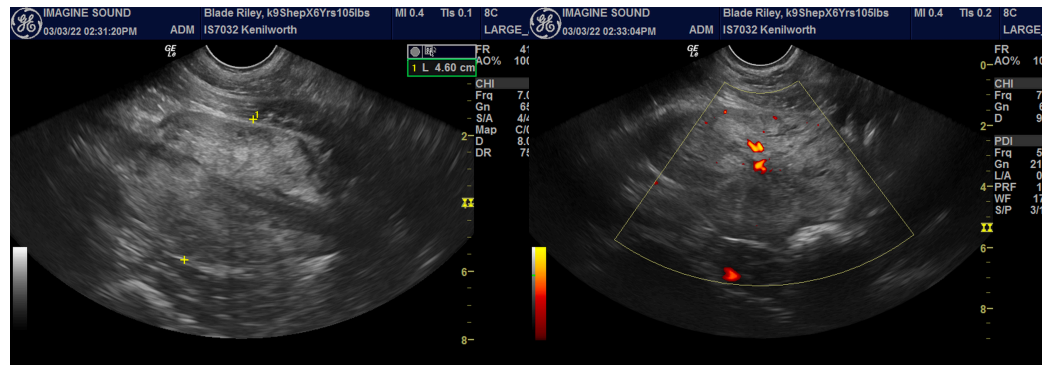
Dr. Mansour

INVOICE

35904

DATE

3/3/22



The information and recommendations provided are based on the images presented by the referring veterinarian/sonographer. No evaluation can be communicated regarding pathology that was not visible in the image/video clips provided.

Thank you for this referral. If the clinical or image interpretation does not parallel your findings or if I can be of any further assistance please contact me.

Eric Lindquist, DMV, DABVP, Cert. IVUSS, CEO of SonoPath.com

info@SonoPath.com