



PATIENT PRESENTING CLINICAL SIGNS

Trip Lassig Recheck sonogram.

SPECIES ULTRASONOGRAPHIC EXAMINATION

Canine

Gastrointestinal

BREED

Miniature Pinscher Mix

Persistent gastric foreign body was noted and continued from the pylorus into the small intestine with tethered intestine with rapid turns and contour. Reactive surrounding mesentery was noted. Unhealthy bowel was noted with various thickening and early loss of detail. Regional reactive mesentery was noted throughout the upper gastrointestinal tract.

SEX

Neutered male

ULTRASONOGRAPHIC FINDINGS

Definitive dilated bowel followed by empty small bowel creating an obstructive pattern.

AGE

9 years

INTERPRETATION OF THE FINDINGS & FURTHER RECOMMENDATIONS

I recommend immediate exploratory surgery with expectations towards gastrotomy, enterotomy, GI biopsies and abdominal lavage. Liver biopsy is indicated at that time, yet is likely reactive. This is a surgical emergency.

WEIGHT

16 lbs

INTERPRETED BY

Eric Lindquist, DMV
DABVP, Cert. IVUSS

IMAGING PERFORMED BY

Dr. Jagger

HOSPITAL NAME

VCA Parkway aH

REFERRING VET

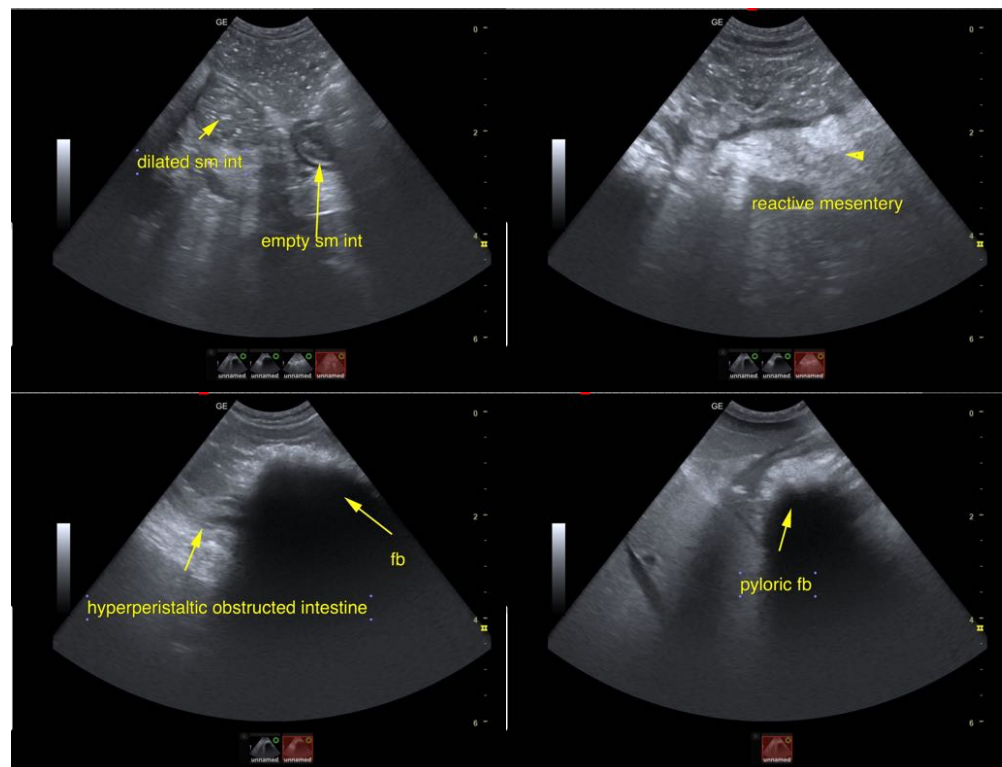
Dr. Jagger

INVOICE

43615

DATE

3/29/23





PATIENT

Trip Lassig

SPECIES

Canine

BREED

Miniature Pinscher Mix

SEX

Neutered male

AGE

9 years

WEIGHT

16 lbs

INTERPRETED BY

Eric Lindquist, DMV
DABVP, Cert. IVUSS

**IMAGING
PERFORMED BY**

Dr. Jagger

HOSPITAL NAME

VCA Parkway aH

REFERRING VET

Dr. Jagger

INVOICE

43615

DATE

3/29/23

The information and recommendations provided are based on the images presented by the referring veterinarian/sonographer. No evaluation can be communicated regarding pathology that was not visible in the image/video clips provided.

Thank you for this referral. If the clinical or image interpretation does not parallel your findings or if I can be of any further assistance please contact me.

Eric Lindquist, DMV, DABVP, Cert. IVUSS, CEO of SonoPath.com
info@SonoPath.com