



PATIENT PRESENTING CLINICAL SIGNS

Yoda Arico
Crackles/wheezes on thoracic auscultation (chronic, >1 yr hx of consolidated R middle lung lobe) - 3/6 Sternal systolic heart murmur - History of self trauma to digits when not on Prednisolone - Hind limb weakness/lameness, improving since started on pain meds (Gabapentin, Buprenex) - Lumbosacral chronic intervertebral disc degeneration with spondylosis deformans

SPECIES

Feline

BREED

DSH

SEX

Neutered Male

AGE

12 Years

WEIGHT

13.6 Pounds

INTERPRETED BY

Eric Lindquist, DMV

DABVP, Cert. IVUSS

IMAGING PERFORMED BY

Sara Hansen

HOSPITAL NAME

Eastgate Vet Clinic

REFERRING VET

Dr. Herdener

INVOICE

36544

DATE

3/29/22

ULTRASONOGRAPHIC EXAMINATION OF THE HEART

FELINE CARDIAC PARAMETERS	BODY WEIGHT (kg)	HR (BPM)	IVSd (cm)	LVIDd (cm)	LVWd (cm)	FS (%)	EF (%)
NORMAL PARAMETER	-----	150-240	0.3-0.6	1.0-2.1	0.25-0.6	35-67	80-100
PATIENT		182	0.39	1.52	0.37	28	57
FELINE CARDIAC PARAMETERS	LA/AO (Boon)	LA/AO HEART BASE (Sisson)	LA 2D 4-chamber long axis AS to FW (Sisson) (cm)		LVOT VEL. (m/s)	RVOT VEL. (m/s)	IVRT (m/)
NORMAL PARAMETER	<1.5	0.88-1.79	0.7-1.7		<1.6	<1.3	40-60
PATIENT	1.5	1.6	1.8		--	0.7	NM
Adapted from June Boon, Veterinary Echocardiography, 1998 Sisson D et al. JVIM 1991; 5: 232, Jacobs et al. Am J Vet Res 1985; 46:1705							

Cardiac Presentation

The cardiac presentation revealed adequate contractility and improved left and right-sided volume. Right atrial size has normalized. Minor mitral and tricuspid insufficiency noted.

ULTRASONOGRAPHIC FINDINGS

- Stable cardiomyopathy

INTERPRETATION OF THE FINDINGS & FURTHER RECOMMENDATIONS

Recommend continuation of current protocol. Recheck echo in 1-3 months depending on if any clinical signs are present. The respiratory signs are non-cardiogenic in this patient, as the heart appears compensated.



PATIENT

Yoda Arico

SPECIES

Feline

BREED

DSH

SEX

Neutered Male

AGE

12 Years

WEIGHT

13.6 Pounds

INTERPRETED BY

Eric Lindquist, DMV
DABVP, Cert. IVUSS

IMAGING PERFORMED BY

Sara Hansen

HOSPITAL NAME

Eastgate Vet Clinic

REFERRING VET

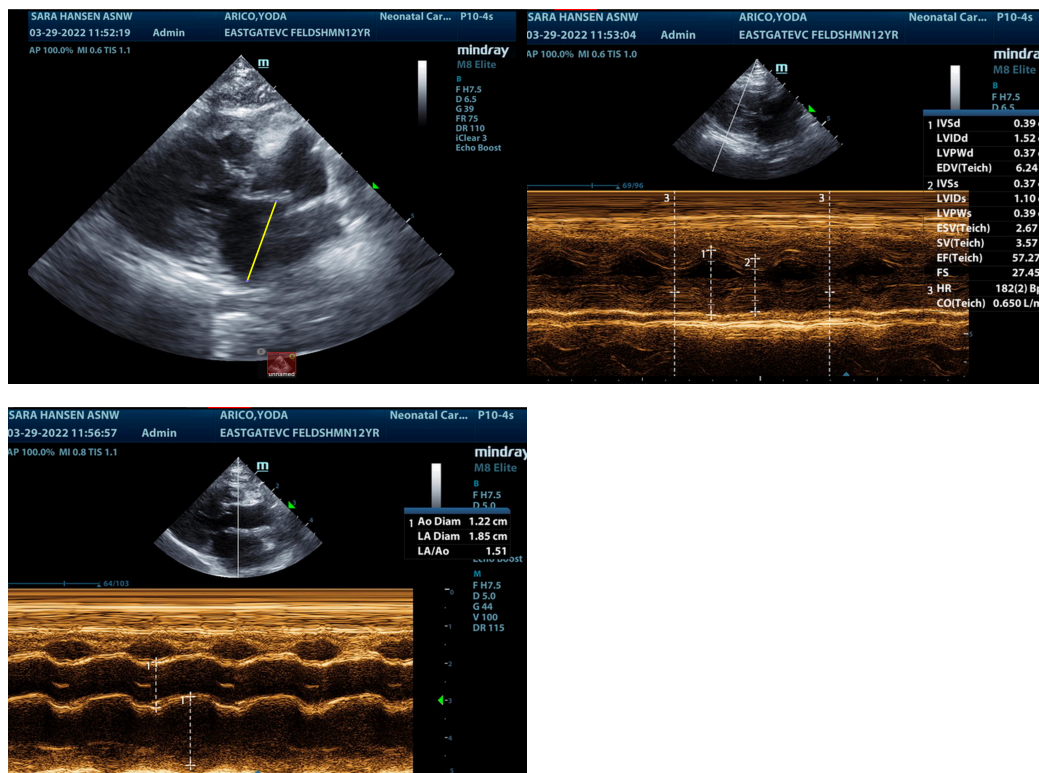
Dr. Herdener

INVOICE

36544

DATE

3/29/22



The information and recommendations provided are based on the images presented by the referring veterinarian/sonographer. No evaluation can be communicated regarding pathology that was not visible in the image/video clips provided.

Thank you for this referral. If the clinical or image interpretation does not parallel your findings or if I can be of any further assistance please contact me.

Eric Lindquist, DMV, DABVP, Cert. IVUSS, CEO of SonoPath.com

info@SonoPath.com