

PATIENT PRESENTING CLINICAL SIGNS

PATIENT Libby Yeager
SPECIES Feline
BREED DSH
SEX Spayed Female
AGE 14 Years
WEIGHT 5.2 Pounds

ADR, Not eating, Losing weight, pu/pd, lethargic, previously diagnosed with hyperthyroidism Current Medications Methimazole TDG
 Abnormal PE/Chem/CBC/UA Results: In clinic electrolytes panel ran this morning 3/29/22 @ 8:25am Sodium - 132 (range 147-156 mEq/l) Potassium - 3.8 (range 3.4 - 5.3 mEq/l) Chloride - 87 (range 107-125 mEq/l) Na/K Ratio 35

ULTRASONOGRAPHIC EXAMINATION OF THE ABDOMEN

Urinary System

The **urinary bladder**, trigone, and pelvic urethra presented normal thicknesses and normal tone. The ureters were not visible which is normal. No uroliths or sediment were visualized and anechoic urine was present. No evidence of inflammatory or neoplastic changes were noted. Ureteral papillae were normal. The pelvic urethra was imaged 2.0 cm beyond the cystourethral junction.

The **kidneys** presented a relatively uniform cortical hyperechogenicity when compared to the renal medulla, spleen and liver. No overt masses were noted. Corticomedullary definition was nebulous and the ratio favored the cortex slightly. The ureters were not visible and assumed to be normal. These changes are most consistent with chronic interstitial nephritis yet infiltrative disease could not be entirely ruled out without biopsy though neoplasia is not suspected. The left kidney measured 4.03 cm. The right kidney measured 3.9 cm.

Adrenal Glands

Both **adrenal glands** were visualized and recognized as having normal shape, size, position and echogenicity for this breed. The phrenic vasculature, glandular echogenicity and detail were unremarkable. Capsule, cortex, and medullary definition were normal for this age patient. The right adrenal gland measured 0.40 cm. The left adrenal gland measured 0.38 cm.

Spleen

The **spleen** presented a smooth homogeneous parenchyma hyperechoic to liver and renal cortical parenchyma. The capsule was smooth without noticeable expansion or deviation from within the spleen or adjacent pathology. The splenic vasculature demonstrated normal volume without signs of congestion or thrombosis. No sonographic evidence of acute or chronic inflammatory, neoplastic, or infarctual changes were noted.

Liver

The **liver** images submitted revealed subjectively normal liver size, contour, and structure. Parenchymal echogenicity was naturally coarse and hypoechoic to the spleen. Vascular and biliary tracts were of normal volume with no evidence of congestion. The gallbladder presented acceptably thin walls with primarily anechoic content. The cystic and common bile ducts were normal. No pathological hepatic lymphadenopathy was evident. No overt structural evidence of inflammatory, infiltrative or regenerative pathology was evident.

Gastrointestinal

The **gastrointestinal** presentation revealed mild uniform prominence of the gastric mucosa as well as areas of "ropey" small intestinal wall with 1:1 muscularis/mucosal ratio. Intestinal wall thickness measured up to 0.36 cm. The intestinal submucosa was slightly irregular, thickened and hyperechoic

INTERPRETED BY

Eric Lindquist, DMV
 DABVP, Cert. IVUSS

IMAGING PERFORMED BY

Jenna Walsh, CVT

HOSPITAL NAME

West Salem AC

REFERRING VET

Dr. Crane

INVOICE

36546

DATE

3/29/22



PATIENT

Libby Yeager

SPECIES

Feline

BREED

Pancreas

DSH

SEX

Spayed Female

AGE

14 Years

WEIGHT

5.2 Pounds

INTERPRETED BY

Eric Lindquist, DMV

DABVP, Cert. IVUSS

IMAGING PERFORMED BY

Jenna Walsh, CVT

HOSPITAL NAME

West Salem AC

REFERRING VET

Dr. Crane

INVOICE

36546

DATE

3/29/22

suggestive of low grade, chronic disease. A minor amount of retained chyme was noted in the gastric fundus. The pyloric outflow was free of evidence pathology. Curvilinear patterns were maintained throughout the GI tract. No concerning lymphadenopathy was visible. No evidence of obstruction was present. Chronic inflammatory bowel disease is likely with a low possibility of an early neoplastic event such as lymphoma. Full thickness tissue biopsies via open laparotomy, ideally guided by intraoperative ultrasound in order to obtain the most representative mural sample, would be necessary to rule out this possibility.

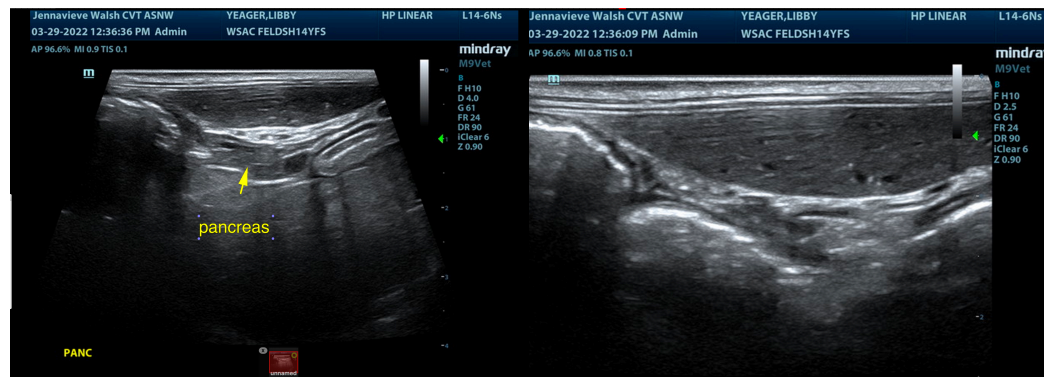
The base and limbs of the **pancreas** were observed to be largely isoechoic to surrounding omental fat. Some parenchymal remodeling, however, with mild deviation from curvilinear normalcy was observed. Pancreatic duct and capsular irregularities were present consistent with age related changes. If pain upon imaging (+ Murphy sign) was present or if the patient is focally painful in subxyphoid palpation then low-grade smoldering chronic pancreatitis should be suspected.

ULTRASONOGRAPHIC FINDINGS

- Minor gastric stasis and minor muscularis hypertrophy in the distal small intestine
- Mild chronic interstitial nephrosis pattern

INTERPRETATION OF THE FINDINGS & FURTHER RECOMMENDATIONS

Mild gastritis suspected. Chronic inflammatory bowel with malassimilation of nutrients or occult neoplasia outside of the abdomen are possibilities. No overt evidence of neoplasia. Maldigestion panel, three view chest radiographs and full CNS examination is recommended to examine for occult disease that could be responsible for the weight loss. Evaluation for competitive eating environments should also be considered.





PATIENT

Libby Yeager

SPECIES

Feline

BREED

DSH

SEX

Spayed Female

AGE

14 Years

WEIGHT

5.2 Pounds

INTERPRETED BY

Eric Lindquist, DMV
DABVP, Cert. IVUSS

IMAGING PERFORMED BY

Jenna Walsh, CVT

HOSPITAL NAME

West Salem AC

REFERRING VET

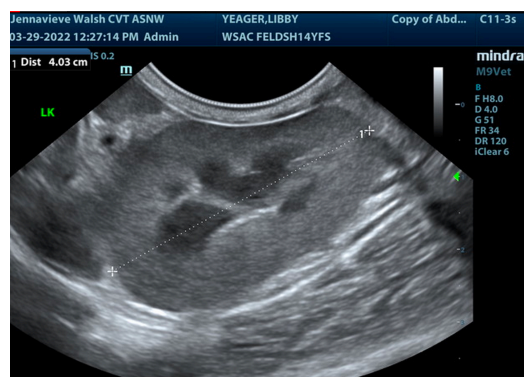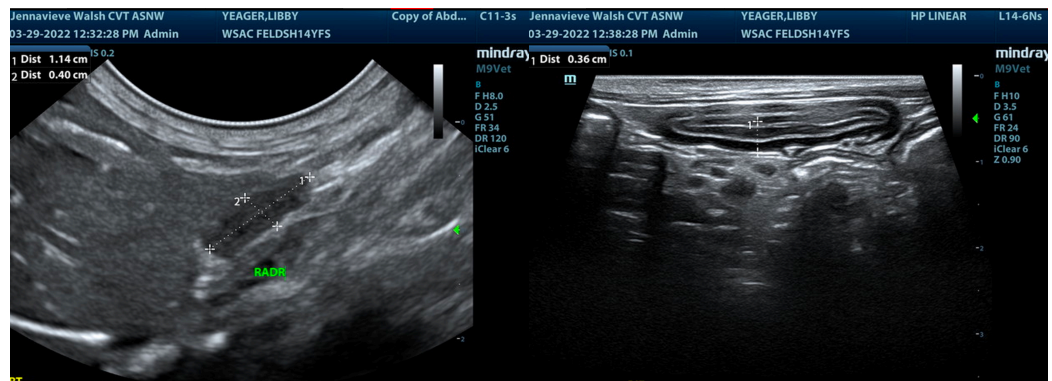
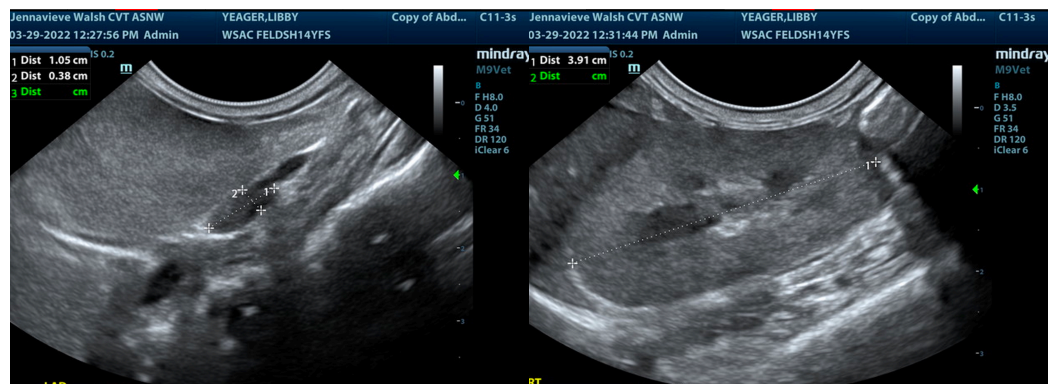
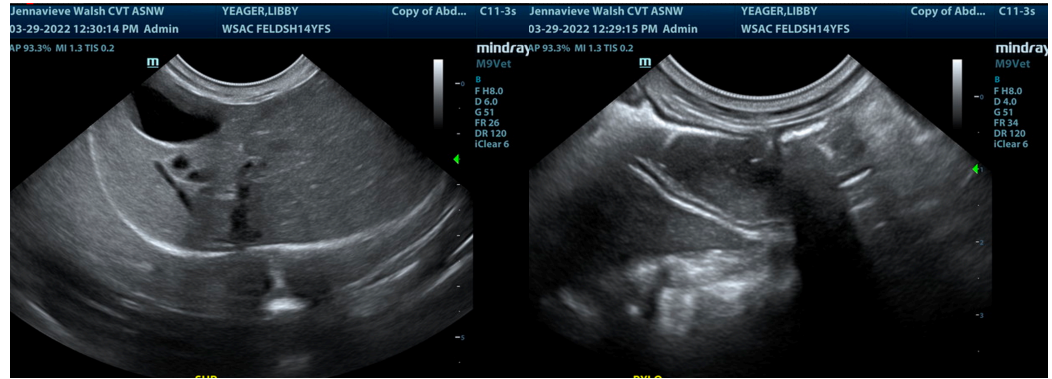
Dr. Crane

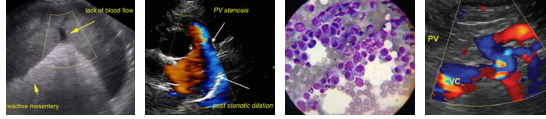
INVOICE

36546

DATE

3/29/22





PATIENT

Libby Yeager

SPECIES

Feline

BREED

DSH

SEX

Spayed Female

AGE

14 Years

WEIGHT

5.2 Pounds

INTERPRETED BY

Eric Lindquist, DMV
DABVP, Cert. IVUSS

**IMAGING
PERFORMED BY**

Jenna Walsh, CVT

HOSPITAL NAME

West Salem AC

REFERRING VET

Dr. Crane

INVOICE

36546

DATE

3/29/22

The information and recommendations provided are based on the images presented by the referring veterinarian/sonographer. No evaluation can be communicated regarding pathology that was not visible in the image/video clips provided.

Thank you for this referral. If the clinical or image interpretation does not parallel your findings or if I can be of any further assistance please contact me.

Eric Lindquist, DMV, DABVP, Cert. IVUSS, CEO of SonoPath.com

info@SonoPath.com