

IMAGING PERFORMED BY

IntraPet.com



DATE PRESENTING CLINICAL SIGNS

3/29/22

Cushing's. Hyperparathyroidism.
Current Medications: Vetoryl 30mg SID, Lasix 20mg BID, Apoquel 16mg ½ SID.
Lab Results: See attached.

PATIENT

Harley Lankford

Date of Previous IntraPet Ultrasound:
Sedation: Patient sedated with Ketamine/Valium.
Stat Report: Not requested.
Imaging Performed By: Andi Parkinson, RDMS.

SPECIES

Canine

BREED

Mix

SEX

Neutered male

AGE

2/10/10

WEIGHT

31.8 lbs

INTERPRETED BY

Eric Lindquist, DMV
DABVP, Cert. IVUSS

HOSPITAL NAME

Chadwell AH

REFERRING VET

Dr. Gold

INVOICE

97929

ULTRASONOGRAPHIC EXAMINATION OF THE THYROID

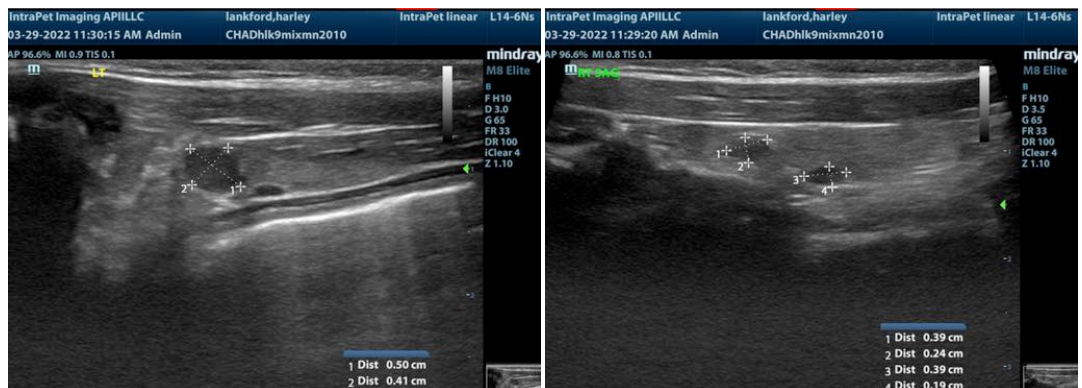
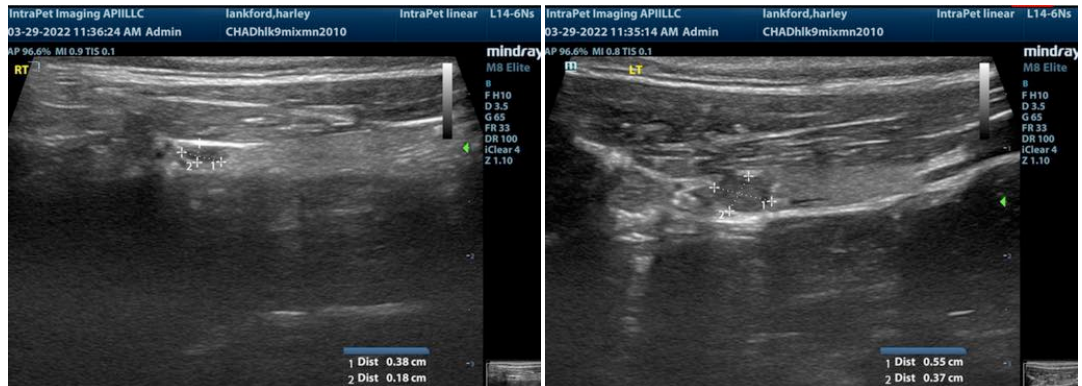The largest parathyroid was 0.38 cm. The thyroid glands were uniform. The cranial pole of the left thyroid gland revealed a 0.55 cm expansive parathyroid nodule that is consistent with adenoma. Other parathyroids were normal. The right thyroid lobe measured 2.14 x 0.37 cm. The left thyroid lobe measured 2.8 x 0.65 cm. The views provided of the trachea, salivary glands and esophagus were normal.

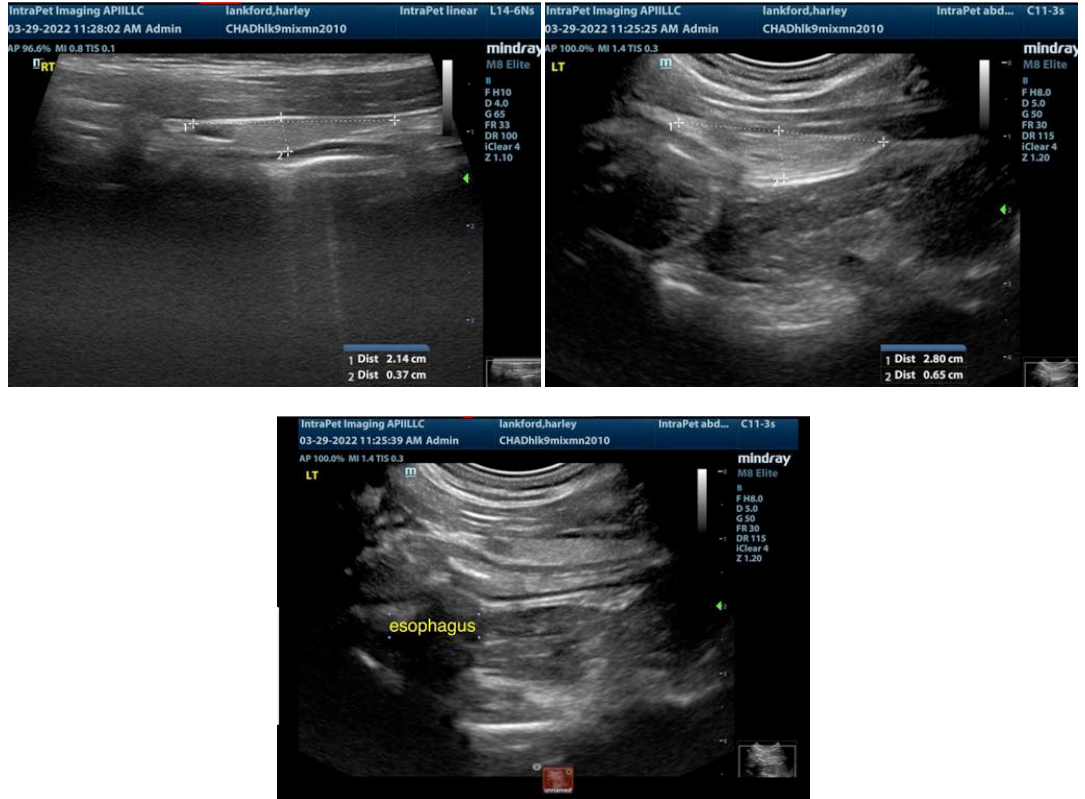
ULTRASONOGRAPHIC FINDINGS

Left cranial parathyroid adenoma.
Normal parathyroids and thyroid glands and regional tissues otherwise.

INTERPRETATION OF THE FINDINGS & FURTHER RECOMMENDATIONS

Surgical removal is recommended.





The information and recommendations provided are based on the images presented by the referring veterinarian. No evaluation can be communicated regarding pathology that was not visible in the image/video clips provided.

Thank you for this referral. If the clinical or image interpretation does not parallel your findings or if I can be of any further assistance please contact me.

Eric Lindquist, DMV, DABVP, Cert. IVUSS, CEO of SonoPath.com
Eric.Lindquist@SonoPath.com