

PATIENT PRESENTING CLINICAL SIGNS

Bernie McClatchy History: Continued hyporexia. Prev U/S 2/24/22 Limited study of stomach

SPECIES ULTRASONOGRAPHIC EXAMINATION OF THE ABDOMEN

Canine The gastric wall was moderately thickened and measured up to 2.6 cm with some loss of mural detail. Minor gastric luminal fluid was noted. The upper duodenum was also mildly thickened. The submucosal layer was thickened. The muscularis and serosa were unremarkable. However, irregular mucosal changes were noted.

BREED

Bernese Mountain Dog

ULTRASONOGRAPHIC FINDINGS

SEX

Chronic gastritis pattern with possibility of emerging gastric neoplasia.

Neutered male

AGE

INTERPRETATION OF THE FINDINGS & FURTHER RECOMMENDATIONS

8 years

Endoscopy is warranted or full thickness gastric biopsies. Sampling is essential either through endoscopy or full thickness biopsies given the mucosal and submucosal changes. There was no evidence of foreign bodies.

WEIGHT

141 lbs

INTERPRETED BY

Eric Lindquist, DMV DABVP, Cert. IVUSS

IMAGING PERFORMED BY

Dr. Rodriguez

HOSPITAL NAME

Foxfield VS

REFERRING VET

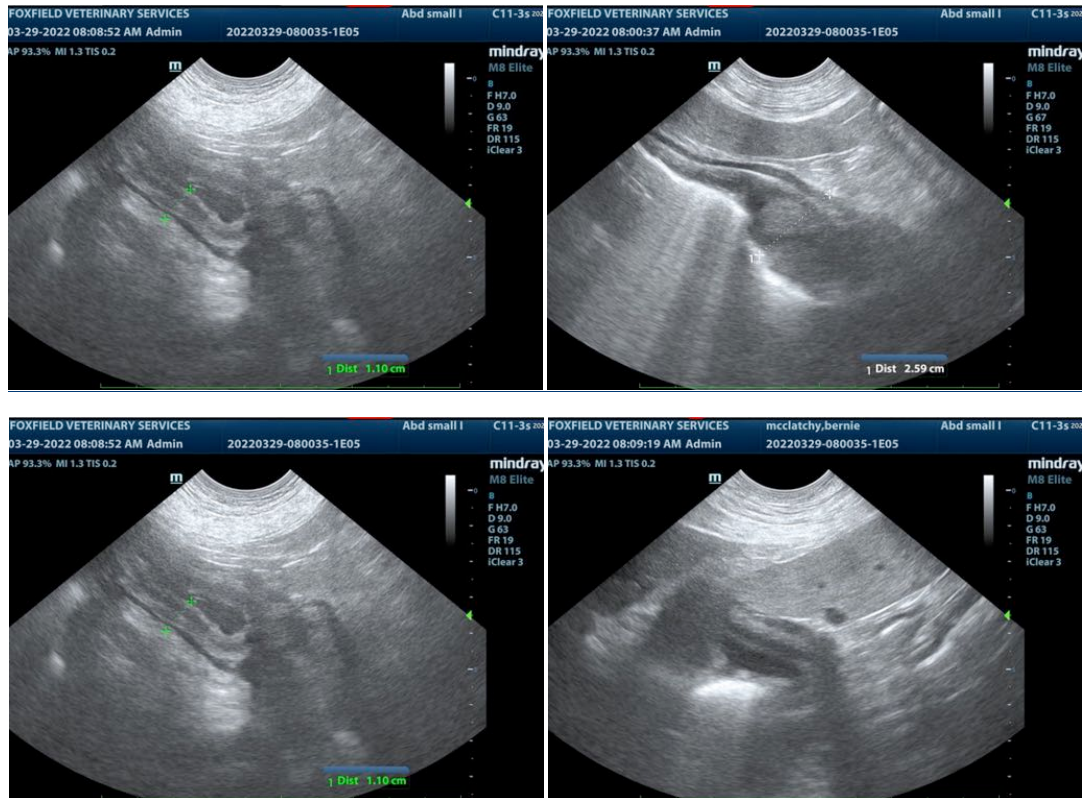
Dr. Rodriguez

INVOICE

97871

DATE

3/25/22





PATIENT

Bernie McClatchy

The information and recommendations provided are based on the images presented by the referring veterinarian/sonographer. No evaluation can be communicated regarding pathology that was not visible in the image/video clips provided.

SPECIES

Canine

Thank you for this referral. If the clinical or image interpretation does not parallel your findings or if I can be of any further assistance please contact me.

BREED

Bernese Mountain Dog

Eric Lindquist, DMV, DABVP, Cert. IVUSS, CEO of SonoPath.com
info@SonoPath.com

SEX

Neutered male

AGE

8 years

WEIGHT

141 lbs

INTERPRETED BY

Eric Lindquist, DMV
DABVP, Cert. IVUSS

**IMAGING
PERFORMED BY**

Dr. Rodriguez

HOSPITAL NAME

Foxfield VS

REFERRING VET

Dr. Rodriguez

INVOICE

97871

DATE

3/25/22