



PATIENT **PRESENTING CLINICAL SIGNS**

Romeo McCready History: possible bladder stones idiopathic cystitis

SPECIES **ULTRASONOGRAPHIC EXAMINATION OF THE ABDOMEN**

Feline

Urinary System

BREED

Domestic Shorthair

The **urinary bladder**, trigone, and pelvic urethra presented normal thicknesses and normal tone. The pelvic urethra was imaged 2.0 cm beyond the cystourethral junction and appeared normal. Two separate polyps were noted and measured 0.58 cm at the cranial pole and 0.51 cm at the caudal pole. These may represent the ureteral papillae secondary to passage of calculi. They appear to be stable. The proximal urethra was unremarkable. The ureters were not visible which is normal.

SEX

Neutered male

The **kidneys** revealed largely normal size and structure, corticomedullary definition and ratio (cortex 1/3 of medulla) were essentially maintained with some age-related loss of curvilinear patterns regarding the capsule and C/M junction. The cortices presented largely uniform texture with some increased echogenicity expected for his age patient. Medullary structure differed distinctly from that of the cortex and no evidence of pelvic dilation was present. Mineralization was noted in the kidneys. The right kidney measured 4.29 cm. The left kidney measured 4.32 cm.

AGE

11 years

WEIGHT

16.9 lbs

Adrenal Glands

Both **adrenal glands** were visualized and recognized as having normal shape, size, position and echogenicity for this breed. The phrenic vasculature, glandular echogenicity and detail were unremarkable. Capsule, cortex, and medullary definition were normal for this age patient.

INTERPRETED BY

Eric Lindquist, DMV
DABVP, Cert. IVUSS

Spleen

IMAGING PERFORMED BY

Jenn

The **spleen** presented a smooth homogeneous parenchyma hyperechoic to liver and renal cortical parenchyma. The capsule was smooth without noticeable expansion or deviation from within the spleen or adjacent pathology. The splenic vasculature demonstrated normal volume without signs of congestion or thrombosis. No sonographic evidence of acute or chronic inflammatory, neoplastic, or infarctual changes was noted.

HOSPITAL NAME

Rockaway AH

Liver

REFERRING VET

Dr. Maniar

The **liver** was mildly hyperechoic to the falciform fat. The gallbladder and common bile duct were unremarkable.

INVOICE

43534

Gastrointestinal

DATE

3/27/23

Examination of the **gastrointestinal tract** revealed a stomach and intestine free of stasis, of normal wall thickness, acceptable curvilinear mural detail, and peristaltic activity. Small and large intestine demonstrated normal luminal chyme and stool consistency respectively. No obstructive or overt infiltrative disease was noted. No associated abnormal lymphatic activity was noted.



PATIENT

Romeo McCready

SPECIES

Feline

BREED

Domestic Shorthair

SEX

Neutered male

AGE

11 years

WEIGHT

16.9 lbs

INTERPRETED BY

Eric Lindquist, DMV
DABVP, Cert. IVUS

IMAGING PERFORMED BY

Jenn

HOSPITAL NAME

Rockaway AH

REFERRING VET

Dr. Maniar

INVOICE

43534

DATE

3/27/23

Pancreas

The base and limbs of the **pancreas** were observed to be largely isoechoic to surrounding omental fat. Pancreatic duct and capsular contour were acceptably normal and parenchyma respected normal curvilinear patterns. No overt evidence of active inflammatory or neoplastic disease was noted.

ULTRASONOGRAPHIC FINDINGS

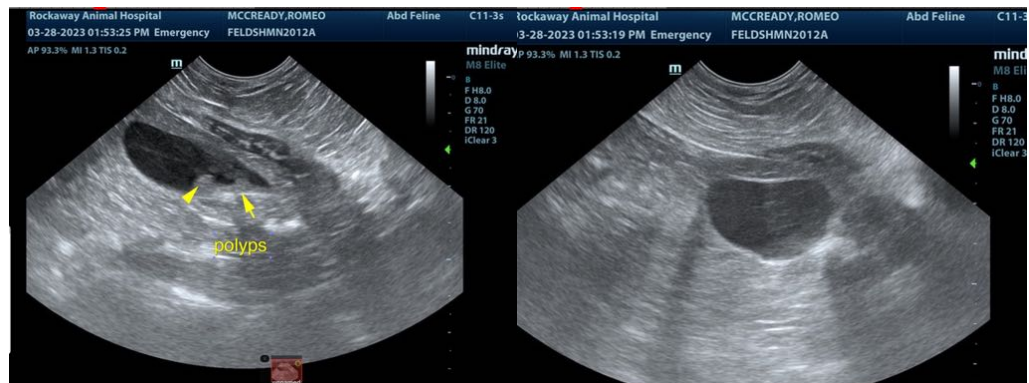
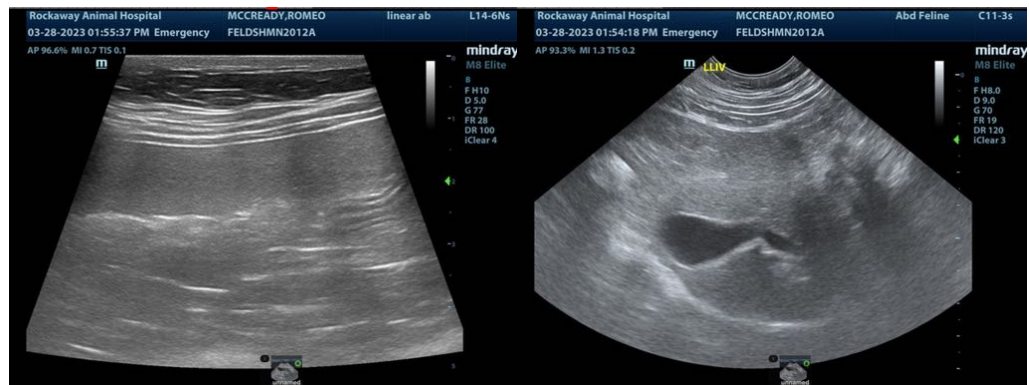
Age related renal changes with slight mineralization.

Prominent urethral papillae or polyps, appears stable.

Otherwise, age related abdominal changes.

INTERPRETATION OF THE FINDINGS & FURTHER RECOMMENDATIONS

There was no evidence of significant disease.





PATIENT

Romeo McCreedy

SPECIES

Feline

BREED

Domestic Shorthair

SEX

Neutered male

AGE

11 years

WEIGHT

16.9 lbs

INTERPRETED BY

Eric Lindquist, DMV
DABVP, Cert. IVUSS

**IMAGING
PERFORMED BY**

Jenn

HOSPITAL NAME

Rockaway AH

REFERRING VET

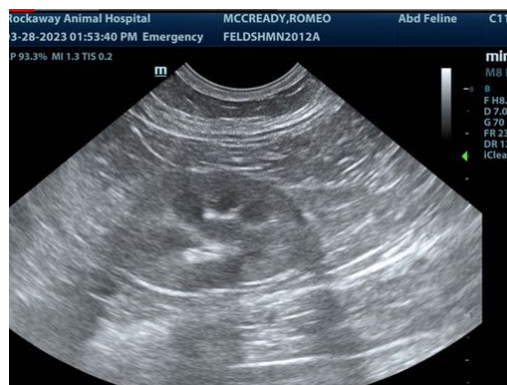Dr. Maniar

INVOICE

43534

DATE

3/27/23



The information and recommendations provided are based on the images presented by the referring veterinarian/sonographer. No evaluation can be communicated regarding pathology that was not visible in the image/video clips provided.

Thank you for this referral. If the clinical or image interpretation does not parallel your findings or if I can be of any further assistance please contact me.

Eric Lindquist, DMV, DABVP, Cert. IVUSS, CEO of SonoPath.com
info@SonoPath.com