



PATIENT

Phoebe Nieves

SPECIES

Canine

BREED

Mini Schnauzer

SEX

Spayed female

AGE

10 years

WEIGHT

11.7 lbs

INTERPRETED BY

Eric Lindquist, DMV
DABVP, Cert. IVUSS

IMAGING PERFORMED BY

Christina

HOSPITAL NAME

Animal Health VC

REFERRING VET

Dr. Rodriguez

INVOICE

43500

DATE

3/28/23

PRESENTING CLINICAL SIGNS

History: P has presented for decreased appetite, no V/D, P had radiographs with a loss of definition present around liver/spleen area.

Abnormal PE/Chem/CBC/UA Results: PCV - 19.6%, WBC - 22,000 (predominantly neutrophils), Plt ct - 137, AlkP - 323, all other chem values WNL

ULTRASONOGRAPHIC EXAMINATION OF THE ABDOMEN

Urinary System

The **urinary bladder**, trigone, and pelvic urethra presented normal thicknesses and normal tone. The ureters were not visible which is normal. No uroliths or sediment were visualized and anechoic urine was present. No evidence of inflammatory or neoplastic changes was noted. Ureteral papillae were normal.

The **kidneys** revealed largely normal size and structure, corticomedullary definition and ratio (cortex 1/3 of medulla) were essentially maintained with some age-related loss of curvilinear patterns regarding the capsule and C/M junction. The cortices presented largely uniform texture with some increased echogenicity expected for his age patient. Medullary structure differed distinctly from that of the cortex and no evidence of pelvic dilation was present. Slight mineralization was noted. The left kidney measured 4.84 cm. The right kidney measured 5.01 cm.

Adrenal Glands

Both **adrenal glands** were visualized and recognized as having normal shape, size, position and echogenicity for this breed. The phrenic vasculature, glandular echogenicity and detail were unremarkable. Capsule, cortex, and medullary definition were normal for this age patient. The left adrenal gland measured 0.32 cm at the cranial pole and 0.51 cm at the caudal pole. The right adrenal gland measured 0.7 cm.

Spleen

The **spleen** in this patient revealed a complex, mixed, hypoechoic mass. A separate parenchymal mass was noted at the mid body measuring 3.0 cm.

Liver

The **liver** was riddled with multiple, metastatic type masses that deviated the gallbladder. The liver masses measured up to 4.0 cm with surrounding free fluid.

Gastrointestinal

Examination of the **gastrointestinal tract** revealed a stomach and intestine free of stasis, of normal wall thickness, acceptable curvilinear mural detail, and peristaltic activity. Small and large intestine



PATIENT

demonstrated normal luminal chyme and stool consistency respectively. No obstructive or overt infiltrative disease was noted. No associated abnormal lymphatic activity was noted.

Phoebe Nieves

SPECIES

Pancreas

Canine

The base and limbs of the **pancreas** were observed to be largely isoechoic to surrounding omental fat. Pancreatic duct and capsular contour were acceptably normal and parenchyma respected normal curvilinear patterns. No overt evidence of active inflammatory or neoplastic disease was noted.

BREED

Mini Schnauzer

Free Abdomen

SEX

Free fluid was noted in the abdomen. Given the anemia hemorrhage is suspected.

Spayed female

ULTRASONOGRAPHIC FINDINGS

AGE

Multi-centric neoplasia. Splenic and hepatic masses with secondary free fluid.

10 years

INTERPRETATION OF THE FINDINGS & FURTHER RECOMMENDATIONS

WEIGHT

Chronic bleeding and reabsorption is likely an issue as the amount of fluid is fairly minor. Multi-centric hemangiosarcoma or similar is likely. The prognosis is poor. Humane euthanasia should be considered.

11.7 lbs

INTERPRETED BY

Eric Lindquist, DMV
DABVP, Cert. IVUS

IMAGING PERFORMED BY

Christina

HOSPITAL NAME

Animal Health VC

REFERRING VET

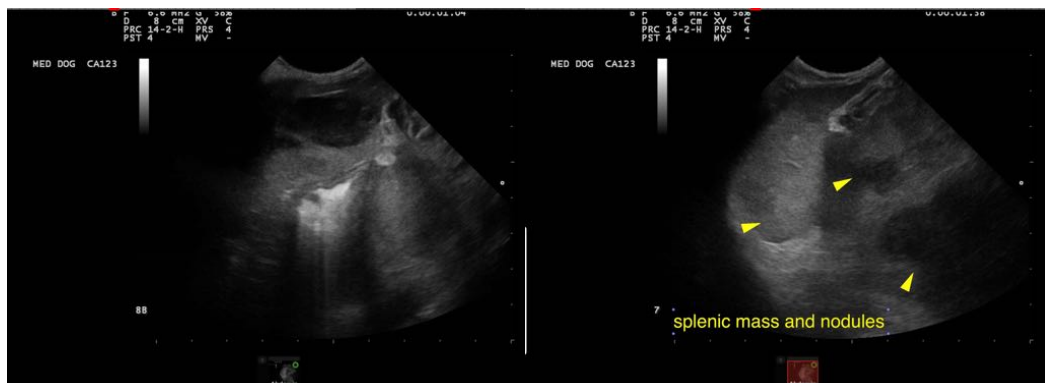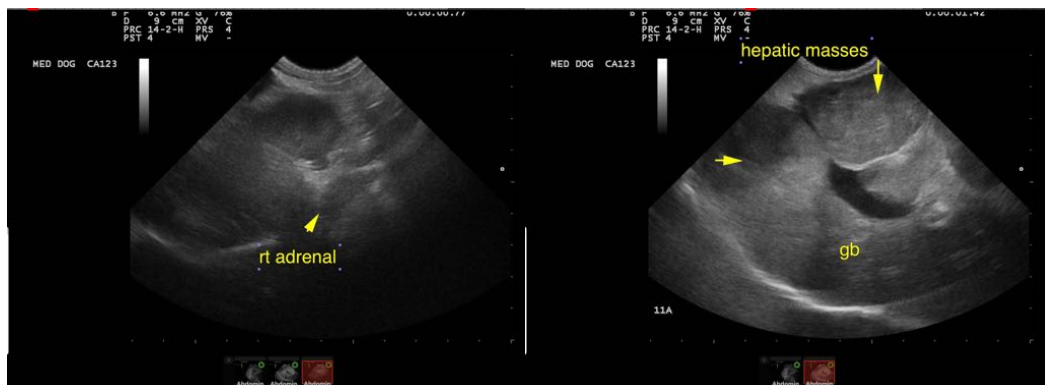Dr. Rodriguez

INVOICE

43500

DATE

3/28/23





PATIENT

Phoebe Nieves

SPECIES

Canine

BREED

Mini Schnauzer

SEX

Spayed female

AGE

10 years

WEIGHT

11.7 lbs

INTERPRETED BY

Eric Lindquist, DMV
DABVP, Cert. IVUSS

IMAGING PERFORMED BY

Christina

HOSPITAL NAME

Animal Health VC

REFERRING VET

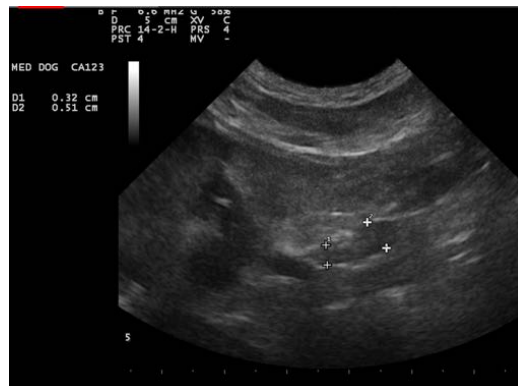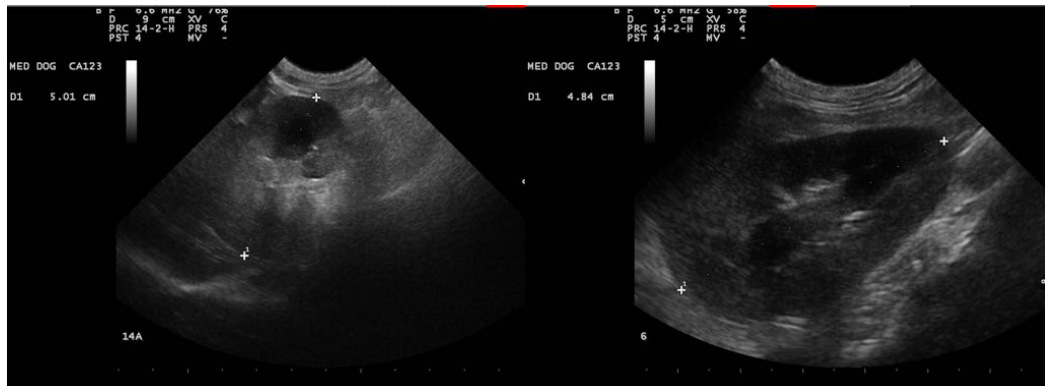
Dr. Rodriguez

INVOICE

43500

DATE

3/28/23



The information and recommendations provided are based on the images presented by the referring veterinarian/sonographer. No evaluation can be communicated regarding pathology that was not visible in the image/video clips provided.

Thank you for this referral. If the clinical or image interpretation does not parallel your findings or if I can be of any further assistance please contact me.

Eric Lindquist, DMV, DABVP, Cert. IVUSS, CEO of SonoPath.com
info@SonoPath.com