



PATIENT

Baci Stoddard

SPECIES

Feline

BREED

Domestic Shorthair

SEX

Spayed female

AGE

14 years

WEIGHT

7.8 lbs

INTERPRETED BY

Eric Lindquist, DMV
DABVP, Cert. IVUSS

IMAGING PERFORMED BY

Jenn

HOSPITAL NAME

Rockaway AH

REFERRING VET

Dr. Maniar

INVOICE

43537

DATE

3/28/23

PRESENTING CLINICAL SIGNS

History: hx of diabetes anorexia weight loss

ULTRASONOGRAPHIC EXAMINATION OF THE ABDOMEN

Urinary System

The **urinary bladder**, trigone, and pelvic urethra presented normal thicknesses and normal tone. The ureters were not visible which is normal. No uroliths or sediment were visualized and anechoic urine was present. No evidence of inflammatory or neoplastic changes was noted. Ureteral papillae were normal.

The **kidneys** revealed largely normal size and structure, corticomedullary definition and ratio (cortex 1/3 of medulla) were essentially maintained with some age-related loss of curvilinear patterns regarding the capsule and C/M junction. The cortices presented largely uniform texture with some increased echogenicity expected for his age patient. Medullary structure differed distinctly from that of the cortex and no evidence of pelvic dilation was present. The right kidney measured 3.78 cm. The left kidney measured 3.5 cm.

Adrenal Glands

Both **adrenal glands** were visualized and recognized as having normal shape, size, position and echogenicity for this breed. The phrenic vasculature, glandular echogenicity and detail were unremarkable. Capsule, cortex, and medullary definition were normal for this age patient.

Spleen

The **spleen** was mildly enlarged with uniform, but subtly micronodular parenchyma, and undulating capsular contour. Hyperechoic lipogranulomatous changes were noted. This is consistent with reactive spleen owing to immune stimulus or early infiltrative disease such as mast cell disease or lymphoma. 25-gauge FNA would be ideal if weight loss is an issue to differentiate early round cell neoplasia versus splenitis or reactive spleen all of which can present in this manner. The spleen measured 0.9 cm.

Liver

The **liver** images from right and left intercostal as well as subcostal views revealed subjectively normal liver size, contour, and structure. Some age-related parenchymal remodeling was noted but likely not clinically significant at this time. Vascular and biliary tracts were of normal volume and no evidence of congestion was noted. The gallbladder presented some dependent debris with essentially normal contour. The cystic and common bile ducts were normal. No overt evidence of active inflammatory, infiltrative or regenerative pathology was noted but should be paired with current or past LE elevations regarding any clinical significance to this presentation. The hepatic lymph nodes were unremarkable.

Gastrointestinal

Examination of the **gastrointestinal tract** revealed a stomach free of stasis, of normal wall thickness, acceptable curvilinear mural detail, and peristaltic activity. Diffuse intestinal thickening without



PATIENT

neoplastic criteria. Reactive mesentery was noted around the small intestine and colon. This is suggestive for subacute on chronic inflammation.

Baci Stoddard

Pancreas

SPECIES

The base and limbs of the **pancreas** were observed to be largely isoechoic to surrounding omental fat. Some parenchymal remodeling, however, with mild deviation from curvilinear normalcy was observed. Pancreatic duct and capsular irregularities were present consistent with age related changes. If pain upon imaging (+ Murphy sign) was present or if the patient is focally painful in subxiphoid palpation then low-grade smoldering chronic pancreatitis should be suspected.

Feline

BREED

Domestic Shorthair

SEX

Enteritis/subacute on chronic inflammatory bowel.

Spayed female

Reactive spleen.

AGE

Likely concurrent pancreatitis.

14 years

INTERPRETATION OF THE FINDINGS & FURTHER RECOMMENDATIONS

WEIGHT

FNA of the spleen is recommended. Subxiphoid palpation is recommended to assess for pain in the region of the pancreas.

7.8 lbs

Potential Causes of Diabetic Dysregulation

INTERPRETED BY

This is a suggestive checkoff list when faced with an unregulated diabetic patient:

Eric Lindquist, DMV
DABVP, Cert. IVUSS

UTI

IMAGING PERFORMED BY

Dietary indiscretion/intolerance

Jenn

Pancreatitis

HOSPITAL NAME

Hyperthyroidism/hypothyroidism

Rockaway AH

Exogenous steroids (including topical eye meds)

Cushing's

REFERRING VET

Acromegaly

Dr. Maniar

Owner compliance

Insulin quality issues

INVOICE

Antibodies to insulin

43537

Underlying Neoplasia

Diffuse liver disease

DATE

3/28/23



PATIENT

Baci Stoddard

SPECIES

Feline

BREED

Domestic Shorthair

SEX

Spayed female

AGE

14 years

WEIGHT

7.8 lbs

INTERPRETED BY

Eric Lindquist, DMV
DABVP, Cert. IVUS

IMAGING PERFORMED BY

Jenn

HOSPITAL NAME

Rockaway AH

REFERRING VET

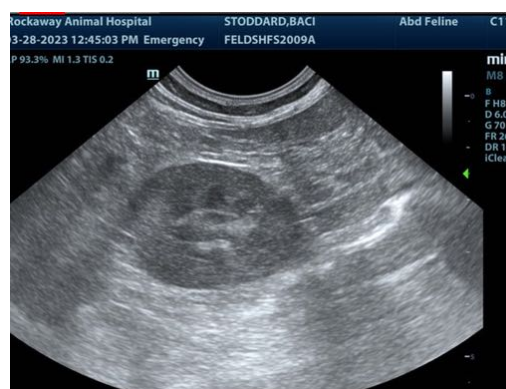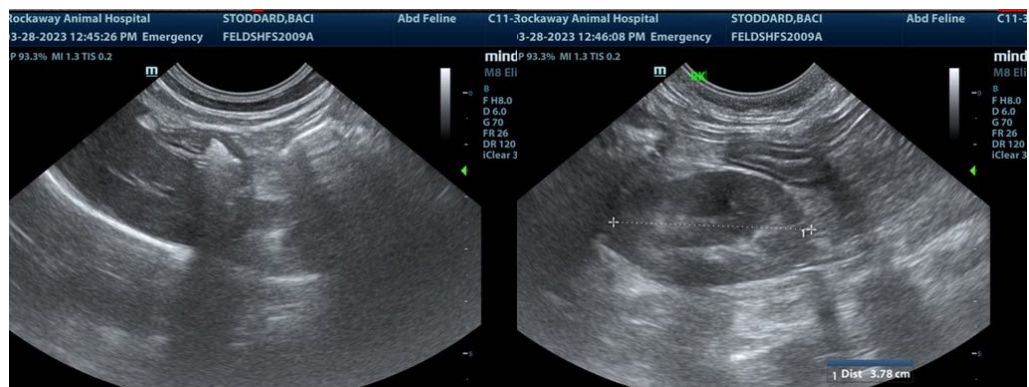
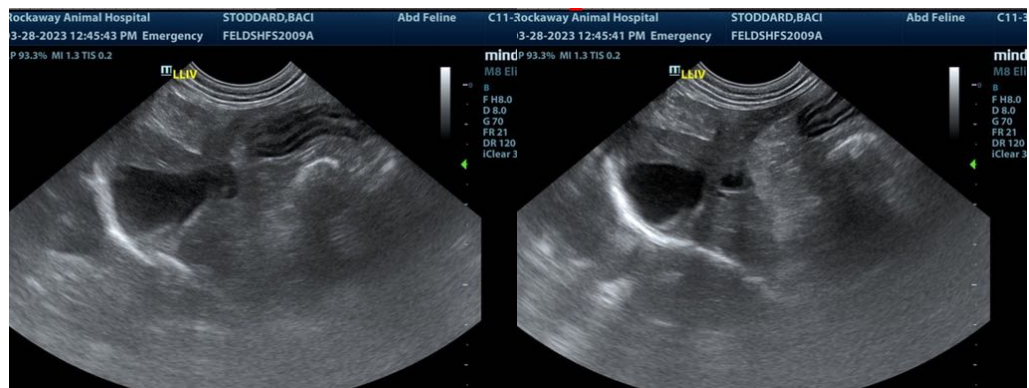
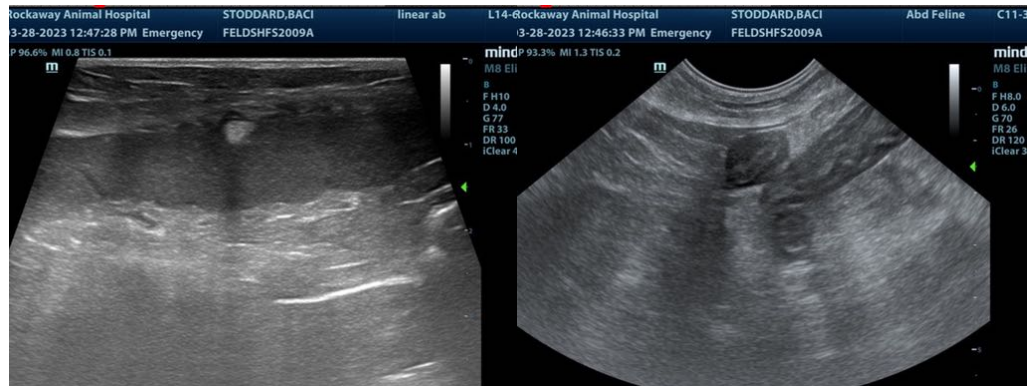
Dr. Maniar

INVOICE

43537

DATE

3/28/23





PATIENT

Baci Stoddard

The information and recommendations provided are based on the images presented by the referring veterinarian/sonographer. No evaluation can be communicated regarding pathology that was not visible in the image/video clips provided.

SPECIES

Feline

Thank you for this referral. If the clinical or image interpretation does not parallel your findings or if I can be of any further assistance please contact me.

BREED

Domestic Shorthair

Eric Lindquist, DMV, DABVP, Cert. IVUSS, CEO of SonoPath.com
info@SonoPath.com

SEX

Spayed female

AGE

14 years

WEIGHT

7.8 lbs

INTERPRETED BY

Eric Lindquist, DMV
DABVP, Cert. IVUSS

**IMAGING
PERFORMED BY**

Jenn

HOSPITAL NAME

Rockaway AH

REFERRING VET

Dr. Maniar

INVOICE

43537

DATE

3/28/23