



PATIENT

Zach Francioli

PRESENTING CLINICAL SIGNS

Hx of diabetes not eating vomiting clear liquid with tinge of red

SPECIES

Feline

ULTRASONOGRAPHIC EXAMINATION OF THE ABDOMEN

Urinary System

The **urinary bladder**, trigone, and pelvic urethra presented normal thicknesses and normal tone. The ureters were not visible which is normal. No uroliths or sediment were visualized and anechoic urine was present. No evidence of inflammatory or neoplastic changes were noted. Ureteral papillae were normal. The pelvic urethra was imaged 1.0 cm beyond the cystourethral junction.

BREED

DSH

SEX

Neutered Male

The **kidneys** revealed largely normal size and structure, corticomedullary definition and ratio (cortex 1/3 of medulla) were essentially maintained with some age-related loss of curvilinear patterns regarding the capsule and C/M junction. The cortices presented largely uniform texture with some increased echogenicity expected for his age patient. Medullary structure differed distinctly from that of the cortex and no evidence of pelvic dilation was present. The right kidney measured 5.04 cm. The left kidney measured 4.27 cm. Corticomedullary mineralization present, non-obstructive.

AGE

12 Years

Adrenal Glands

The regions of the **adrenal glands** were unremarkable.

WEIGHT

19.5 Pounds

Spleen

The **spleen** presented a smooth homogeneous parenchyma hyperechoic to liver and renal cortical parenchyma. The capsule was smooth without noticeable expansion or deviation from within the spleen or adjacent pathology. The splenic vasculature demonstrated normal volume without signs of congestion or thrombosis. No sonographic evidence of acute or chronic inflammatory, neoplastic, or infarctual changes were noted.

INTERPRETED BY

Eric Lindquist, DMV

DABVP, Cert. IVUSS

Liver

The **liver** presented diffusely hyperechoic parenchyma. The gallbladder and common bile duct were unremarkable. This is most consistent with hepatic lipidosis.

IMAGING PERFORMED BY

Jenn

Gastrointestinal

Examination of the **gastrointestinal tract** revealed a stomach and intestine free of stasis, of normal wall thickness, acceptable curvilinear mural detail, and peristaltic activity. Small and large intestine demonstrated normal luminal chyme and stool consistency respectively. No obstructive or overt infiltrative disease was noted. No associated abnormal lymphatic activity was noted.

HOSPITAL NAME

Rockaway AH

Pancreas

The **pancreas** was hypoechoic and irregular with enhanced surrounding mesentery.

REFERRING VET

Dr. Maniar

ULTRASONOGRAPHIC FINDINGS

INVOICE

36524

- Minor pancreatitis pattern
- Lipidosis pattern
- Age related renal changes with mineralization

DATE

3/28/22

INTERPRETATION OF THE FINDINGS & FURTHER RECOMMENDATIONS

Supportive care should prove effective.



PATIENT

Zach Francioli **Potential Causes of Diabetic Dysregulation**

SPECIES

Feline

BREED

DSH

SEX

Neutered Male

AGE

12 Years

WEIGHT

19.5 Pounds

This is a suggestive checkoff list when faced with an unregulated diabetic patient:

UTI

Dietary indiscretion/intolerance

Pancreatitis

Hyperthyroidism/hypothyroidism

Exogenous steroids (including topical eye meds)

Cushing's

Acromegaly

Owner compliance

Insulin quality issues

Antibodies to insulin

Underlying Neoplasia

Diffuse liver disease

INTERPRETED BY

Eric Lindquist, DMV

DABVP, Cert. IVUSS

IMAGING PERFORMED BY

Jenn

HOSPITAL NAME

Rockaway AH

REFERRING VET

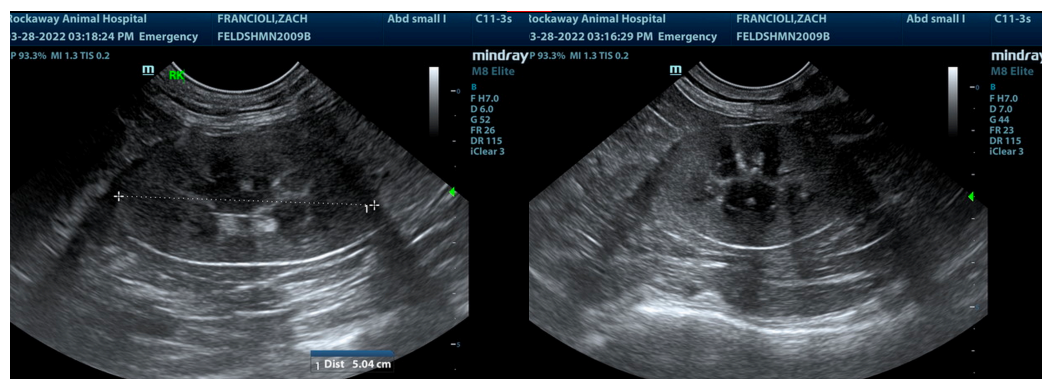
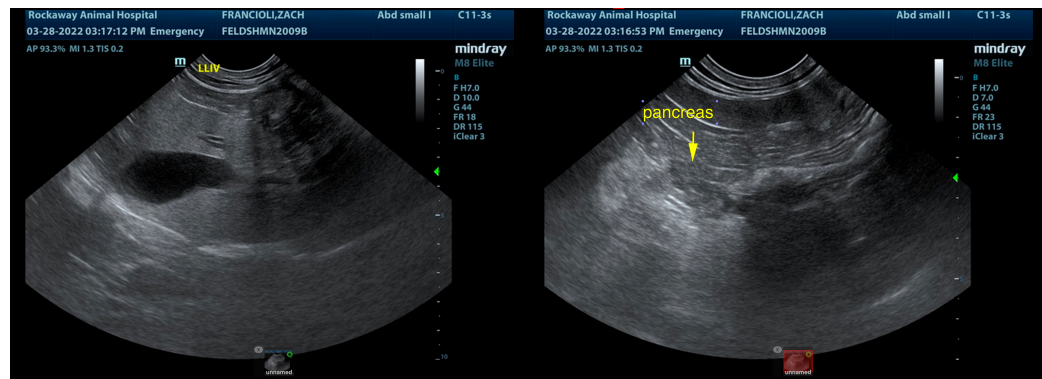
Dr. Maniar

INVOICE

36524

DATE

3/28/22





PATIENT

Zach Francioli

SPECIES

Feline

BREED

DSH

SEX

Neutered Male

AGE

12 Years

WEIGHT

19.5 Pounds

INTERPRETED BY

Eric Lindquist, DMV

DABVP, Cert. IVUSS

**IMAGING
PERFORMED BY**

Jenn

HOSPITAL NAME

Rockaway AH

REFERRING VET

Dr. Maniar

INVOICE

36524

DATE

3/28/22

The information and recommendations provided are based on the images presented by the referring veterinarian/sonographer. No evaluation can be communicated regarding pathology that was not visible in the image/video clips provided.

Thank you for this referral. If the clinical or image interpretation does not parallel your findings or if I can be of any further assistance please contact me.

Eric Lindquist, DMV, DABVP, Cert. IVUSS, CEO of SonoPath.com

info@SonoPath.com