



**PATIENT**

Sunny Hamas

**PRESENTING CLINICAL SIGNS**

History: Vomiting since last Saturday. Current meds: IVFs, Cerenia, famotidine, Unasyn.  
Abnormal PE/Chem/CBC/UA Results: Low Ca+, hypoproteinemia.

**SPECIES**

Feline

**ULTRASONOGRAPHIC EXAMINATION OF THE ABDOMEN**

**Urinary System**

**BREED**

Domestic Shorthair

The **urinary bladder**, trigone, and pelvic urethra presented normal thicknesses and normal tone. The ureters were not visible which is normal. No uroliths or sediment were visualized and anechoic urine was present. No evidence of inflammatory or neoplastic changes was noted. Ureteral papillae were normal.

**SEX**

Neutered male

The **kidneys** revealed normal size and structure, corticomedullary definition and ratio for this age. The cortices presented largely uniform texture with normal echogenic relationship to liver and spleen. Medullary structure differed distinctly from the cortex and no evidence of pelvic dilation was present. The capsules were acceptably uniform without significant irregularities. The right kidney measured 4.48 cm. The left kidney measured 3.58 cm.

**AGE**

7 years

**WEIGHT**

9.3 lbs

**Adrenal Glands**

Both **adrenal glands** were visualized and recognized as having normal shape, size, position and echogenicity for this breed. The phrenic vasculature, glandular echogenicity and detail were unremarkable. Capsule, cortex, and medullary definition were normal for this age patient.

**INTERPRETED BY**

Eric Lindquist, DMV,  
DABVP, Cert. IVUSS,  
CEO of SonoPath.com

**Spleen**

The **spleen** presented a smooth homogeneous parenchyma hyperechoic to liver and renal cortical parenchyma. The capsule was smooth without noticeable expansion or deviation from within the spleen or adjacent pathology. The splenic vasculature demonstrated normal volume without signs of congestion or thrombosis. No sonographic evidence of acute or chronic inflammatory, neoplastic, or infarctual changes was noted.

**IMAGING PERFORMED BY**

Kelly Vazquez, CVT

**HOSPITAL NAME**

Westwood Regional  
VH

**Liver**

The **liver** images submitted revealed subjectively normal liver size, contour, and structure. Parenchymal echogenicity was naturally coarse and hypoechoic to the spleen. Vascular and biliary tracts were of normal volume with no evidence of congestion. The gallbladder presented acceptably thin walls with primarily anechoic content. The cystic and common bile ducts were normal. No pathological hepatic lymphadenopathy was evident. No overt structural evidence of inflammatory, infiltrative or regenerative pathology was evident.

**REFERRING VET**

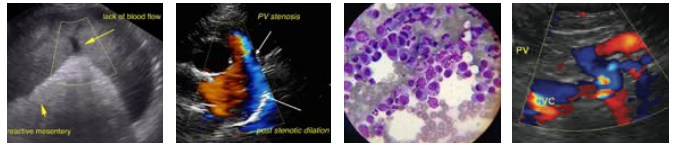
Dr. Goldman

**INVOICE**

97863

**DATE**

3/24/22



**PATIENT**

**Gastrointestinal**

Sunny Hamas

The **gastrointestinal** presentation revealed mild uniform prominence of the gastric mucosa as well as areas of "ropey" small intestinal wall. The muscularis layer was hypertrophied inverting the normal ratio (1:3). The intestinal submucosa was slightly irregular, thickened and hyperechoic suggestive of low grade, chronic inflammation. No evidence of obstruction was present. Chronic inflammatory bowel disease is probable with a low possibility of an early neoplastic event such as lymphoma or, less likely, dry form FIP can at times be found on biopsy of these presentations. Full thickness tissue biopsies via open laparotomy, ideally guided by intraoperative ultrasound in order to obtain the most representative mural sample, would be necessary to rule more significant disease than IBD. Mesenteric lymph node was enlarged and reactive measuring 1.19 x 0.45 cm.

**SPECIES**

Feline

**BREED**

Domestic Shorthair

**SEX**

**Pancreas**

Neutered male

The base and limbs of the **pancreas** were observed to be largely isoechoic to surrounding omental fat. Pancreatic duct and capsular contour were acceptably normal and parenchyma respected normal curvilinear patterns. No overt evidence of active inflammatory or neoplastic disease was noted.

**AGE**

7 years

**ULTRASONOGRAPHIC FINDINGS**

**WEIGHT**

Diffuse inflammatory bowel type presentation with idiopathic muscularis hypertrophy.

9.3 lbs

**INTERPRETATION OF THE FINDINGS & FURTHER RECOMMENDATIONS**

**INTERPRETED BY**

Full thickness gastric and intestinal biopsies would be ideal in this patient for further definition. There is a minor potential for round cell neoplasia, yet no overt neoplastic criteria is present. Low-protein can be a flag for emerging round cell neoplasia based on our research. Otherwise, empirical trial of the following may prove effective. Prednisolone can be utilized empirically, but technically it may suppress an emerging neoplastic presentation.

Eric Lindquist, DMV,  
DABVP, Cert. IVUSS,  
CEO of SonoPath.com

**IMAGING PERFORMED BY**

**Triaditis/Pancreatitis protocol**

Kelly Vazquez, CVT

Part or all of this protocol may be considered based on your clinical impression of the patient:

**HOSPITAL NAME**

Recommend pain management when anorexic with **Buprenorphine** (0.01-0.02 mg/kg IM or SC), clinical trial of **Zithromax** (50 mg sid/cat x 10 days, 3 weeks if bartonella +), **Prednisolone** (0.5-2 mg/kg tapering over 1 week to minimal effective dose), and **B12 injections** if weight loss (Cyanobalamine 250 mcg sub-q once-weekly x six weeks, then every other week for six weeks and then once-monthly, long-term if necessary), **novel-protein or hydrolyzed diet** (*Hydrolyzed diets have been shown to be more effective in dietary intolerance case management compared to hypoallergenic diets*) or the **magical Purina DM** (changing protein source is crucial and may need rotation every 6 months if clinical signs recur) Diet trials is a whatever works phenomenon. If vomiting becomes a persistent issue then endoscopy would be warranted and/or recheck sonogram to assess more emerging disease. One diet does not work for all patients so different trials may be necessary or protein source rotation every 6 months as new sensitivities develop.

Westwood Regional  
VH

**REFERRING VET**

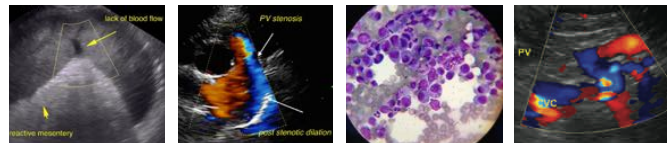
Dr. Goldman

**INVOICE**

97863

**DATE**

3/24/22



**PATIENT**

Sunny Hamas

**SPECIES**

Feline

**BREED**

Domestic Shorthair

**SEX**

Neutered male

**AGE**

7 years

**WEIGHT**

9.3 lbs

**INTERPRETED BY**

Eric Lindquist, DMV,  
DABVP, Cert. IVUSS,  
CEO of SonoPath.com

**IMAGING PERFORMED BY**

Kelly Vazquez, CVT

**HOSPITAL NAME**

Westwood Regional  
VH

**REFERRING VET**

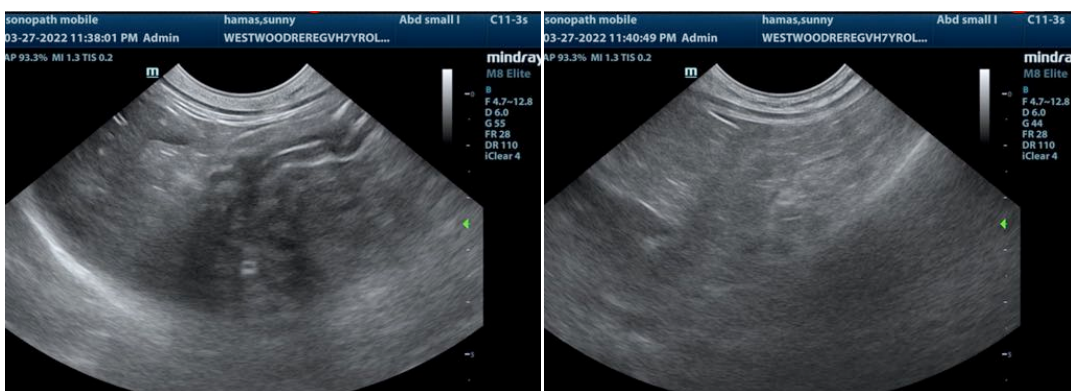
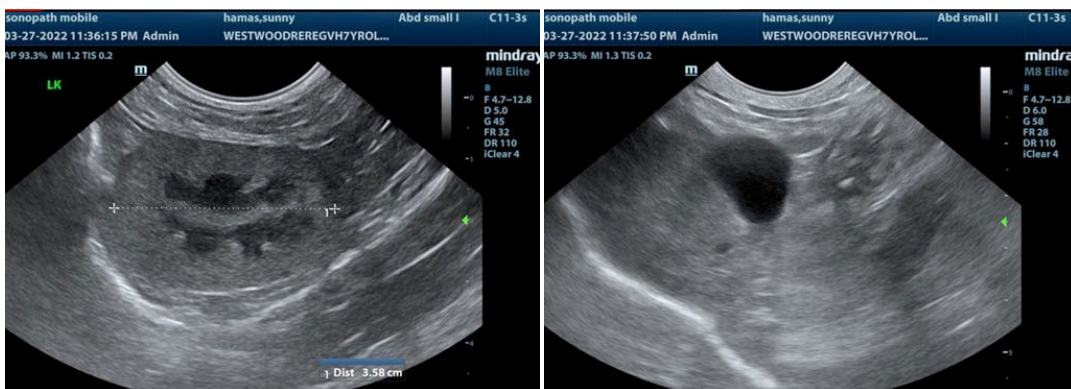
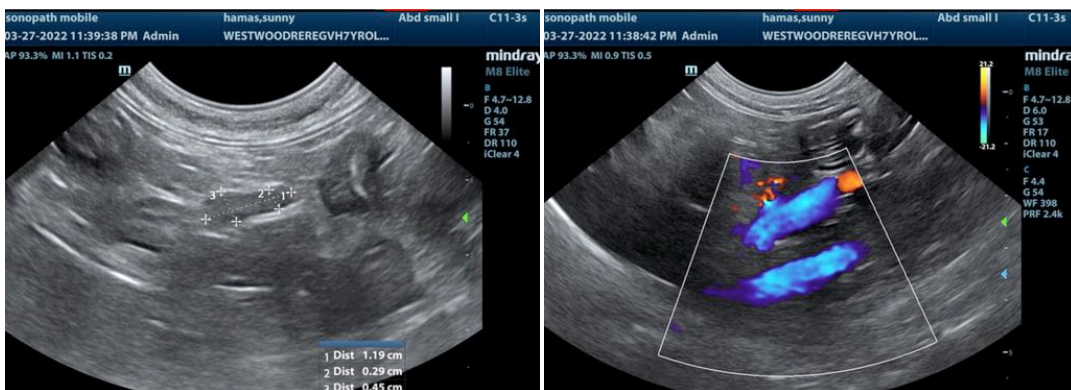
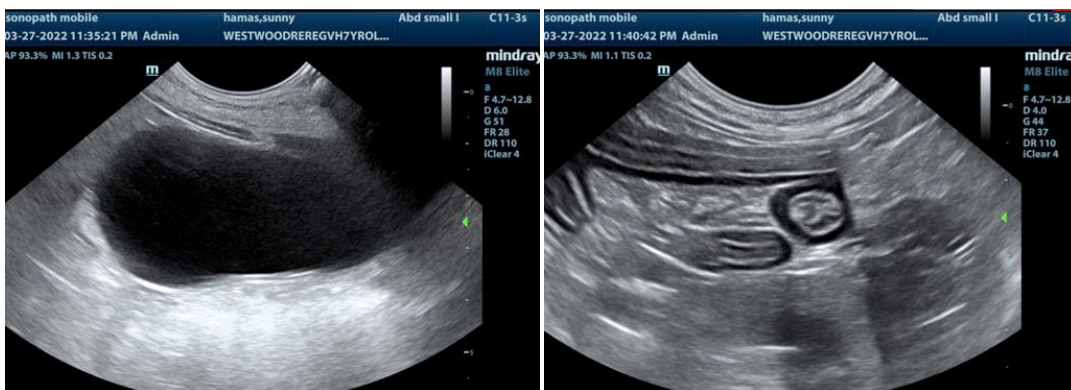
Dr. Goldman

**INVOICE**

97863

**DATE**

3/24/22





**PATIENT**

Sunny Hamas

The information and recommendations provided are based on the images presented by the referring veterinarian/sonographer. No evaluation can be communicated regarding pathology that was not visible in the image/video clips provided.

**SPECIES**

Feline

Thank you for this referral. If the clinical or image interpretation does not parallel your findings or if I can be of any further assistance please contact me.

**Eric Lindquist, DMV, DABVP, Cert. IVUSS, CEO of SonoPath.com**

Info@SonoPath.com

**BREED**

Domestic Shorthair

**SEX**

Neutered male

**AGE**

7 years

**WEIGHT**

9.3 lbs

**INTERPRETED BY**

**Eric Lindquist, DMV,  
DABVP, Cert. IVUSS,  
CEO of SonoPath.com**

**IMAGING  
PERFORMED BY**

Kelly Vazquez, CVT

**HOSPITAL NAME**

Westwood Regional  
VH

**REFERRING VET**

Dr. Goldman

**INVOICE**

97863

**DATE**

3/24/22