



PATIENT

Benny Moore

PRESENTING CLINICAL SIGNS

lethargic pu/pd
Abnormal PE/Chem/CBC/UA Results: alt/sap increased

SPECIES

Canine

ULTRASONOGRAPHIC EXAMINATION OF THE ABDOMEN

Urinary System

BREED

Chihuahua

The **urinary bladder**, trigone, and pelvic urethra presented normal thicknesses and normal tone. The ureters were not visible which is normal. No uroliths or sediment were visualized and anechoic urine was present. No evidence of inflammatory or neoplastic changes were noted. Ureteral papillae were normal. The pelvic urethra was imaged 1.0 cm beyond the cystourethral junction.

SEX

Male

The **kidneys** revealed normal size and structure, corticomedullary definition and ratio for this age. The cortices presented largely uniform texture with normal echogenic relationship to liver and spleen. Medullary structure differed distinctly from the cortex and no evidence of pelvic dilation was present. The capsules were acceptably uniform without significant irregularities. The left kidney measured 3.5 cm. The right kidney measured 4.01 cm.

AGE

7 Years

Adrenal Glands

Both **adrenal glands** were visualized and recognized as having normal shape, size, position and echogenicity for this breed. The phrenic vasculature, glandular echogenicity and detail were unremarkable. Capsule, cortex, and medullary definition were normal for this age patient. The left adrenal gland measured 0.50 cm. The right adrenal gland measured 0.60 cm.

WEIGHT

4.8 Pounds

Spleen

The **spleen** presented a smooth homogeneous parenchyma hyperechoic to liver and renal cortical parenchyma. The capsule was smooth without noticeable expansion or deviation from within the spleen or adjacent pathology. The splenic vasculature demonstrated normal volume without signs of congestion or thrombosis. No sonographic evidence of acute or chronic inflammatory, neoplastic, or infarctual changes were noted.

INTERPRETED BY

Eric Lindquist, DMV

DABVP, Cert. IVUSS

IMAGING PERFORMED BY

Evanna

Liver

The **liver** was diffusely hyperechoic to falciform fat, consistent with lipidosis or vacuolar hepatopathy. The gallbladder and common bile duct were unremarkable. FNA warranted for further definition.

HOSPITAL NAME

ACC Flanders

Gastrointestinal

Some stasis was noted in the stomach, consistent with chyme. Duodenal spasming noted.

REFERRING VET

Dr. Weagley

Pancreas

The pancreas was hypoechoic and irregular with enhanced surrounding mesentery.

ULTRASONOGRAPHIC FINDINGS

INVOICE

36514

- Pancreatitis pattern
- Lipidosis/vacuolar hepatopathy pattern

INTERPRETATION OF THE FINDINGS & FURTHER RECOMMENDATIONS

DATE

3/28/22

The liver enzyme elevations are likely secondary to the primary pancreatic pathology in the right base. Ultrasound guided FNA of the pancreas and liver warranted for further definition after coagulation



PATIENT

Benny Moore

panel. IV fluid support, GI protectants, broad-spectrum antibiotics warranted in the meantime. Guarded prognosis depending upon cytology results.

SPECIES

Canine

BREED

Chihuahua

SEX

Male

AGE

7 Years

WEIGHT

4.8 Pounds

INTERPRETED BY

Eric Lindquist, DMV

DABVP, Cert. IVUSS

IMAGING PERFORMED BY

Evanna

HOSPITAL NAME

ACC Flanders

REFERRING VET

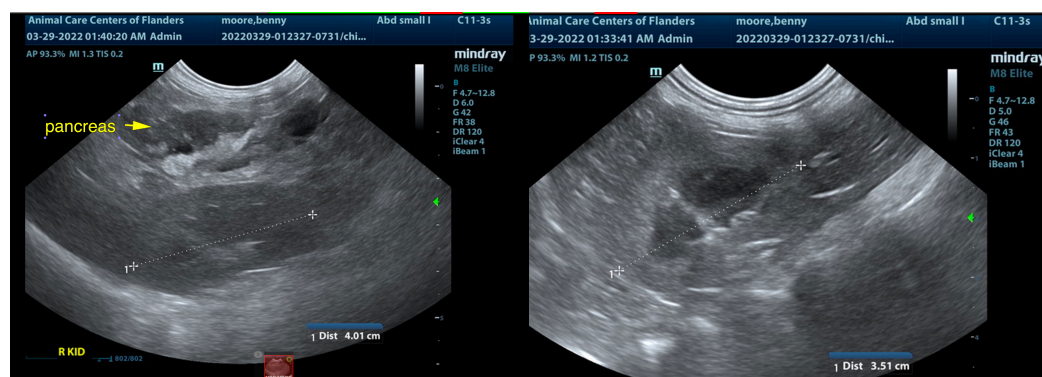
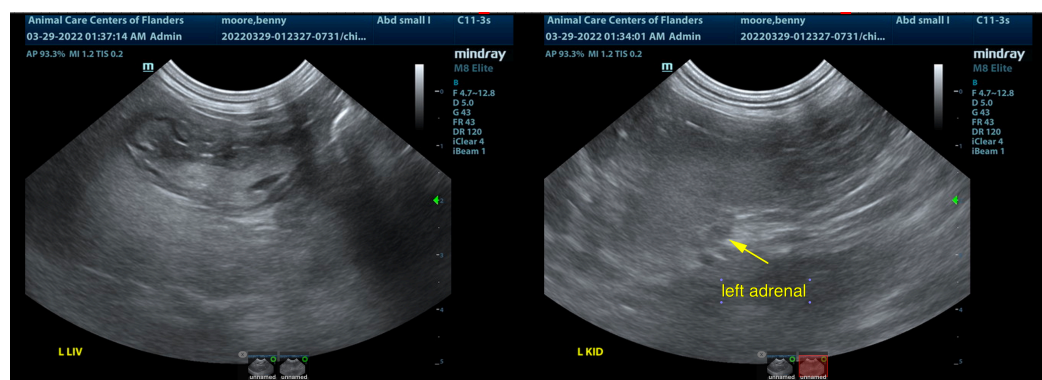
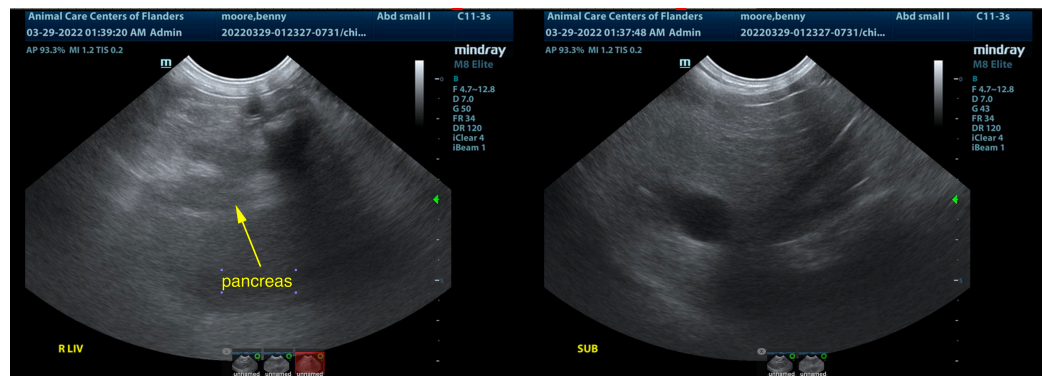
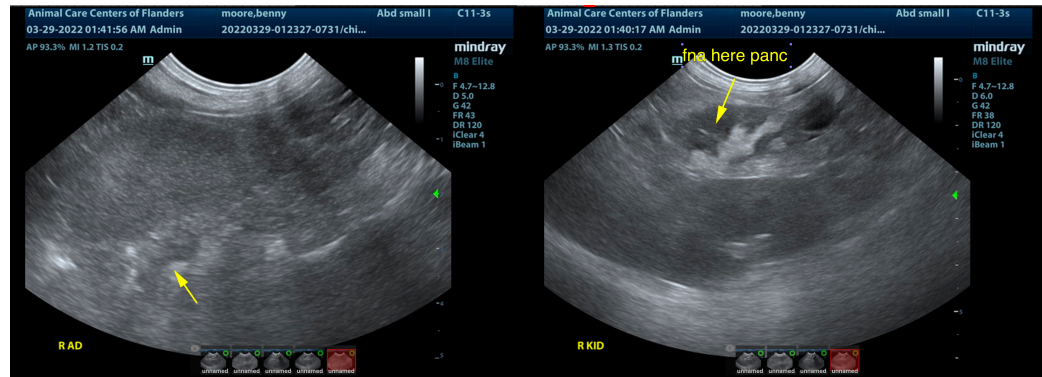
Dr. Weagley

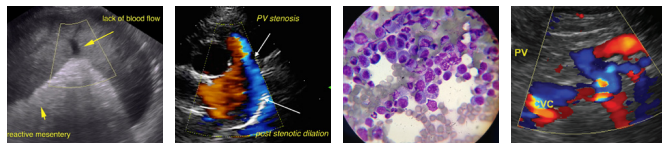
INVOICE

36514

DATE

3/28/22





PATIENT

Benny Moore

The information and recommendations provided are based on the images presented by the referring veterinarian/sonographer. No evaluation can be communicated regarding pathology that was not visible in the image/video clips provided.

SPECIES

Canine

Thank you for this referral. If the clinical or image interpretation does not parallel your findings or if I can be of any further assistance please contact me.

Eric Lindquist, DMV, DABVP, Cert. IVUSS, CEO of SonoPath.com

info@SonoPath.com

BREED

Chihuahua

SEX

Male

AGE

7 Years

WEIGHT

4.8 Pounds

INTERPRETED BY

Eric Lindquist, DMV

DABVP, Cert. IVUSS

IMAGING PERFORMED BY

Evanna

HOSPITAL NAME

ACC Flanders

REFERRING VET

Dr. Weagley

INVOICE

36514

DATE

3/28/22