



PATIENT

Magnus Preston

SPECIES

Canine

BREED

Pitbull

SEX

Neutered male

AGE

7 years

WEIGHT

93.6 lbs

INTERPRETED BY

Eric Lindquist, DMV
DABVP, Cert. IVUSS

IMAGING PERFORMED BY

Laura Klaassen

HOSPITAL NAME

Animal Care Group of
Lake Oswego

REFERRING VET

Dr. Wisniewski

INVOICE

78362

DATE

3/27/26

PRESENTING CLINICAL SIGNS

- New heart murmur
- Grade 1/6 R systolic murmur

ULTRASONOGRAPHIC EXAMINATION OF THE HEART

The echocardiogram in this patient demonstrated normal **left atrial** size based on 3 separate methods of LA evaluation. The cranial and caudal **mitral** valve leaflets presented normal linear structure, extension in systole, and union in diastole with normal kinesis. The **left ventricle** presented thicknesses with linear contour and was not dilated nor restricted. The **myocardium** presented normal echogenicity without subjective evidence of significant fibrotic or ischemic disease. **Contractility** of the ventricular walls was adequate and in normal range for this patient evidenced by the fractional shortening measurement and subjective evaluation of the different regions of the myocardium. The **left ventricular outflow** tract demonstrated normal laminar flow and subjective structural integrity. The **right atrium** and auricle revealed normal size, structure and content. No evidence of masses was noted. **Tricuspid** valvular assessment demonstrated adequate linear morphology and kinesis. The **right ventricle** was of normal size (1/3 diameter of LV), chordae structure, myocardial echogenicity and thickness. **Pulmonary outflow** tract assessment revealed normal valve structure, laminar flow, and diameter (approx.1:1 pa/ao ratio). No visible **pericardial** or free pleura fluid was noted. The cranial **mediastinum and pericardial and extra-cardiac regions** were free of masses in the visible window.

CANINE CARDIAC PARAMETERS	MR VMAX (m/s)	TR VMAX (m/s)	LA/AO	LA/AO (Heart Base)	FS (%)	EF (%)	EPSS (cm)
NORMAL PARAMETER	4.5-5.5	<2.7	1.3	<1.6	28-40	40-100	<0.6
PATIENT	None	None	1.1	1.4	30	NM	0.1
CANINE CARDIAC PARAMETERS	HR (BPM)	AV VMAX (m/s)	PV MAX (m/s)	BODY WEIGHT (kg)	LA 2D short axis Base view (cm)	LVIDd Avg; 2D and m-mode short axis (cm)	LVIDs Avg; 2D and m-mode short axis (cm)
NORMAL PARAMETER	50-100	0.7-1.7	0.7-1.6	BELOW	BELOW	BELOW	BELOW
PATIENT	80	NM	NM	93.6 lbs	4.2	4.1	

ULTRASONOGRAPHIC FINDINGS

Normal echocardiogram, likely flow murmur.



PATIENT

Magnus Preston

SPECIES

Canine

BREED

Pitbull

SEX

Neutered male

AGE

7 years

WEIGHT

93.6 lbs

INTERPRETED BY

Eric Lindquist, DMV
DABVP, Cert. IVUS

IMAGING PERFORMED BY

Laura Klaassen

HOSPITAL NAME

Animal Care Group of
Lake Oswego

REFERRING VET

Dr. Wisniewski

INVOICE

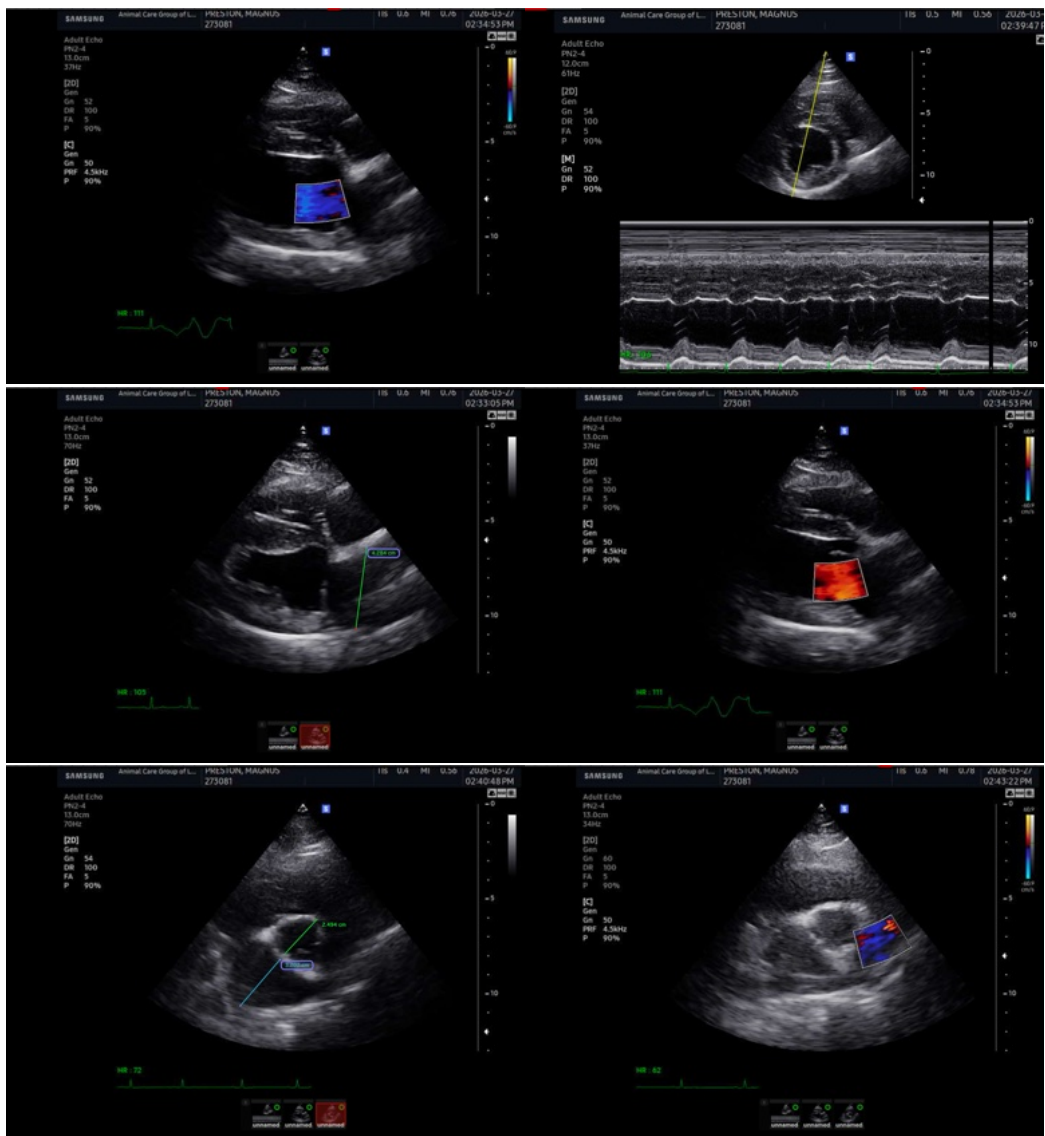
78362

DATE

3/27/26

INTERPRETATION OF THE FINDINGS & FURTHER RECOMMENDATIONS

There is no evidence of appreciable turbulence noted. Laminar flow was evident. The cause of the murmur is unclear. There is no evidence of secondary changes in the heart owing to flow turbulence. Spectral Doppler velocities of the left and right ventricular outflow tract would be ideal to assess if there is an idiopathic benign flow murmur that often happens in the left ventricular outflow tract. However, there was no evidence of structural or functional disease and no contraindication to anesthetic procedure.



The information and recommendations provided are based on the images presented by the



PATIENT

Magnus Preston

SPECIES

Canine

BREED

Pitbull

SEX

Neutered male

AGE

7 years

WEIGHT

93.6 lbs

INTERPRETED BY

Eric Lindquist, DMV
DABVP, Cert. IVUSS

IMAGING PERFORMED BY

Laura Klaassen

HOSPITAL NAME

Animal Care Group of
Lake Oswego

REFERRING VET

Dr. Wisniewski

INVOICE

78362

DATE

3/27/26

referring veterinarian/sonographer. No evaluation can be communicated regarding pathology that was not visible in the image/video clips provided.

Thank you for this referral. If the clinical or image interpretation does not parallel your findings or if I can be of any further assistance please contact me.

Eric Lindquist, DMV, DABVP (CFM), Cert. IVUSS, CEO of SonoPath.com

info@SonoPath.com