



PATIENT

Leo Zarif

SPECIES

Feline

BREED

Scottish Fold

SEX

Male

AGE

6 Years

WEIGHT

4.27 kg

INTERPRETED BY

Eric Lindquist, DMV,
DABVP (Canine &
Feline), Cert. IVUSS

IMAGING PERFORMED BY

Dr. Samad Khan

HOSPITAL NAME

The Veterinary Surgery

REFERRING VET

Dr. Samad Khan

INVOICE

36414

DATE

3/27/26

PRESENTING CLINICAL SIGNS

Low energy and voice changes, few months back saddle thrombus, on xrays enlarged heart, globoid

ULTRASONOGRAPHIC EXAMINATION OF THE HEART

Cardiac Presentation

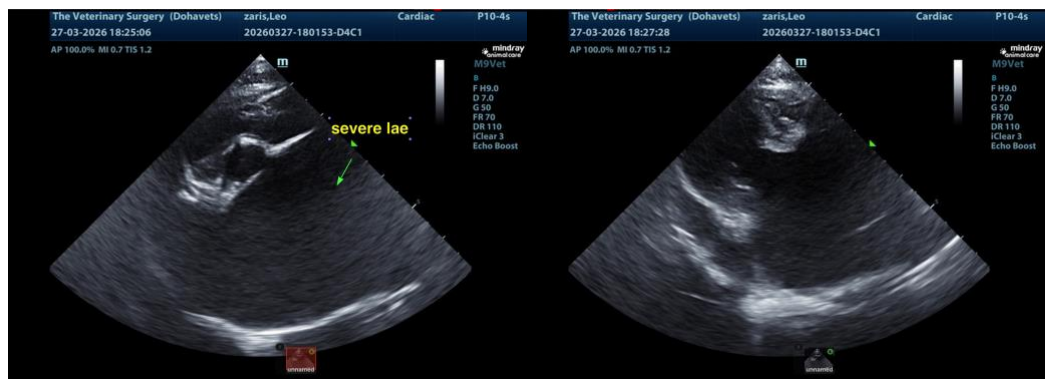
The cardiac presentation in this patient presented severe volume overload of the left atrium with tachyarrhythmia. Concentric left ventricular hypertrophy was noted. Mitral insufficiency was noted. "Smoke" was noted in the left atrium. Left atrial size was >4.0 cm. A clot was noted in the left atrium.

ULTRASONOGRAPHIC FINDINGS

- Severe volume overload of the left heart with concentric left ventricular hypertrophy- suspect congenital lesion, however, this cannot be defined.
- Mitral insufficiency
- Clot in left atrium

INTERPRETATION OF THE FINDINGS & FURTHER RECOMMENDATIONS

Prognosis is extremely poor. Empirically, Lasix could be utilized at a dose of 12.5 mg BID, as well as pimobendan (off label) at a dose of 0.3 mg/kg BID, and Plavix therapy at a dose of 16.25 mg SID. However, further imaging would be necessary to define this cardiac presentation, yet I suspect a complex congenital lesion. This patient is at risk for fail or sudden death.





PATIENT

Leo Zarif

SPECIES

Feline

BREED

Scottish Fold

SEX

Male

AGE

6 Years

WEIGHT

4.27 kg

INTERPRETED BY

Eric Lindquist, DMV,
DABVP (Canine &
Feline), Cert. IVUSS

IMAGING PERFORMED BY

Dr. Samad Khan

HOSPITAL NAME

The Veterinary Surgery

REFERRING VET

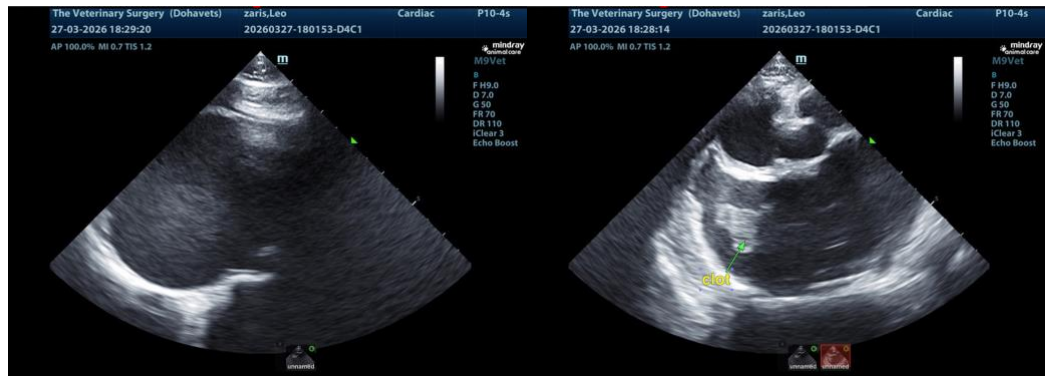
Dr. Samad Khan

INVOICE

36414

DATE

3/27/26



The information and recommendations provided are based on the images presented by the referring veterinarian/sonographer. No evaluation can be communicated regarding pathology that was not visible in the image/video clips provided.

Thank you for this referral. If the clinical or image interpretation does not parallel your findings or if I can be of any further assistance please contact me.

Eric Lindquist, DMV, DABVP(CFM), Cert. IVUSS,
CEO, Owner, Founder -- SonoPath.com
info@SonoPath.com