



**PATIENT**

Lacey Santora

**SPECIES**

Canine

**BREED**

Chihuahua

**SEX**

Spayed Female

**AGE**

10 Years 11 Months

**WEIGHT**

24 Pounds

**INTERPRETED BY**

Eric Lindquist, DMV,  
DABVP (Canine & Feline), Cert. IVUSS

**IMAGING PERFORMED BY**

Rebecca Hamilton

**HOSPITAL NAME**

Montville AH

**REFERRING VET**

Rebecca Hamilton

**INVOICE**

36407

**DATE**

3/27/26

**PRESENTING CLINICAL SIGNS**

- Monitoring MVD - previous echo w/ Sonopath March 2025.
- Would like comparison to last years measurements
- Abnormal PE/Chem/CBC/UA Results: WNL

**ULTRASONOGRAPHIC EXAMINATION OF THE HEART**

CANINE CARDIAC PARAMETERS	MR VMAX (m/s)	TR VMAX (m/s)	LA/AO (M-Mode)	LA/AO (Heart Base; Swe)	FS (%)	EF (%)	EPSS (cm)
<b>NORMAL PARAMETER</b>	4.5-5.5	<2.7	1.3	Up to 1.6	28-40	40-100	<0.6
<b>PATIENT</b>	5.0	2.43	1.0	1.2	59	90	NM
CANINE CARDIAC PARAMETERS	HR (BPM)	AV VMAX (m/s)	PV MAX (m/s)	BODY WEIGHT (lbs)	LAD LA MAX 4 Chamber	LVIDd Avg; 2D and m-mode short axis (cm)	LVIDs Avg; 2D and m-mode short axis (cm)
<b>NORMAL PARAMETER</b>	50-100	0.7-1.7	0.7-1.6				
<b>PATIENT</b>	132	1.90	1.22	25 lbs	2.6	2.9	--

E-wave velocity: 0.7

**Cardiac Presentation**

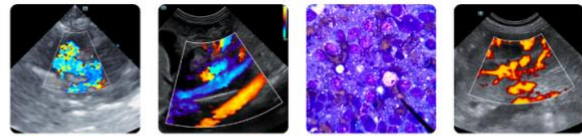
The cardiac presentation in this patient presented normal chamber volumes in all four chambers. Contractility was adequate. Left atrial size was normal on all three measurements. Mitral (mild to moderate and eccentric) and tricuspid insufficiency were noted. Aortic and pulmonic outflow velocities were normal. Pericardial and pleural spaces were unremarkable. Arrhythmogenic activity was noted.

**ULTRASONOGRAPHIC FINDINGS**

- Stage B-1 valvular disease with arrhythmia to define

**INTERPRETATION OF THE FINDINGS & FURTHER RECOMMENDATIONS**

Blood pressures and EKG or Holter monitor are indicated, which may be obtained from out office. No progression from the prior echocardiogram.



**PATIENT**

Lacey Santora

**SPECIES**

Canine

**BREED**

Chihuahua

**SEX**

Spayed Female

**AGE**

10 Years 11 Months

**WEIGHT**

24 Pounds

**INTERPRETED BY**

Eric Lindquist, DMV,  
 DABVP (Canine & Feline), Cert. IVUSS

**IMAGING PERFORMED BY**

Rebecca Hamilton

**HOSPITAL NAME**

Montville AH

**REFERRING VET**

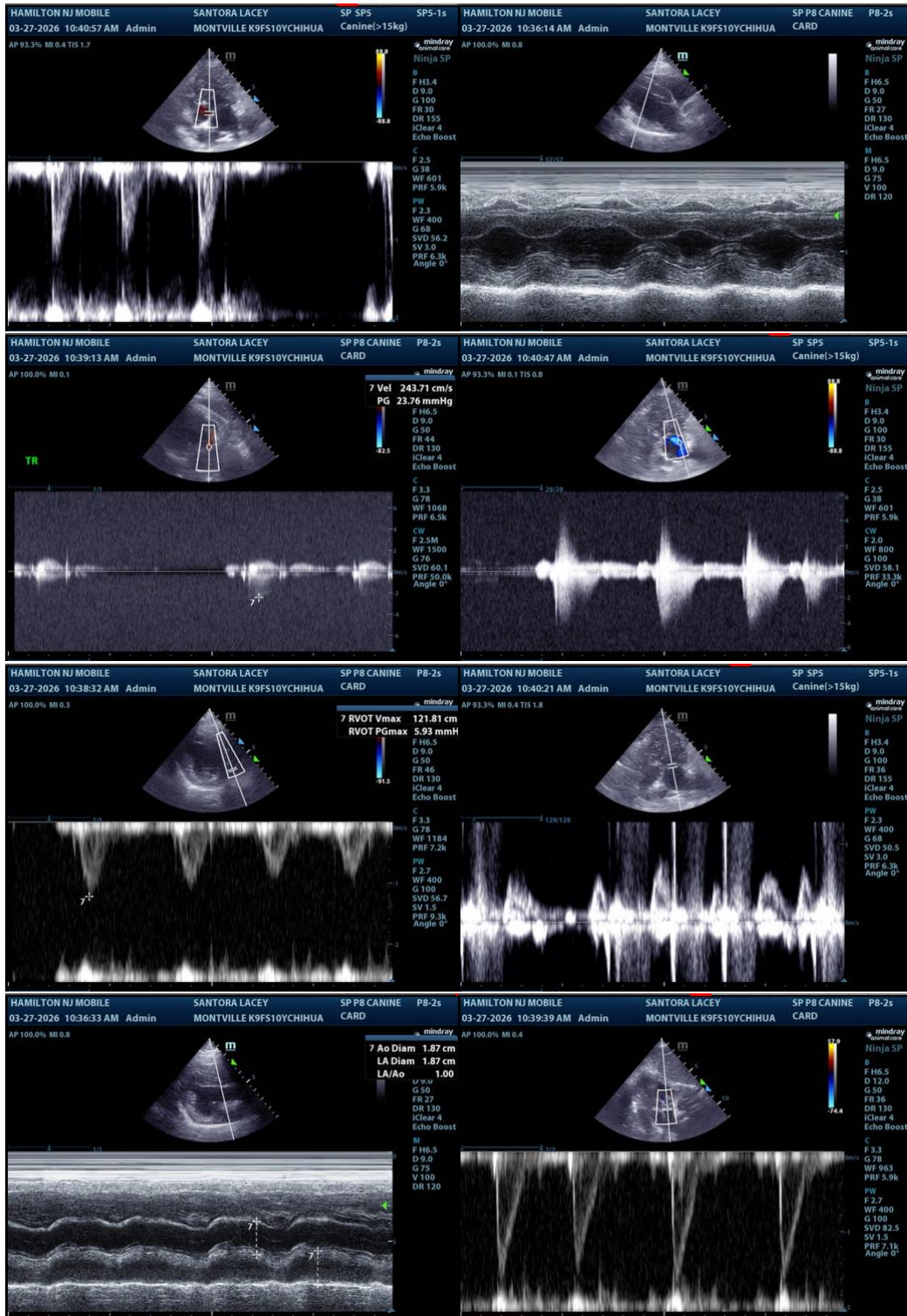
Rebecca Hamilton

**INVOICE**

36407

**DATE**

3/27/26





**PATIENT**

Lacey Santora

**SPECIES**

Canine

**BREED**

Chihuahua

**SEX**

Spayed Female

**AGE**

10 Years 11 Months

**WEIGHT**

24 Pounds

**INTERPRETED BY**

Eric Lindquist, DMV,  
 DABVP (Canine &  
 Feline), Cert. IVUSS

**IMAGING PERFORMED BY**

Rebecca Hamilton

**HOSPITAL NAME**

Montville AH

**REFERRING VET**

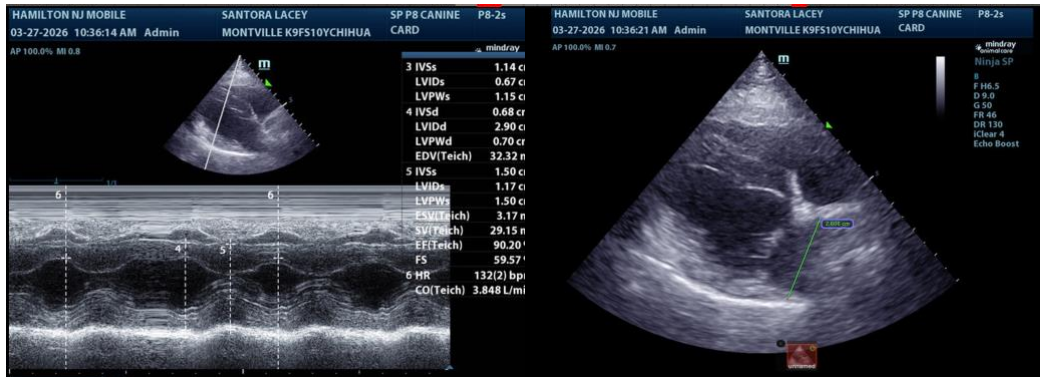
Rebecca Hamilton

**INVOICE**

36407

**DATE**

3/27/26



The information and recommendations provided are based on the images presented by the referring veterinarian/sonographer. No evaluation can be communicated regarding pathology that was not visible in the image/video clips provided.

Thank you for this referral. If the clinical or image interpretation does not parallel your findings or if I can be of any further assistance please contact me.

**Eric Lindquist, DMV, DABVP(CFM), Cert. IVUSS,**  
 CEO, Owner, Founder -- SonoPath.com  
[info@SonoPath.com](mailto:info@SonoPath.com)