

PATIENT PRESENTING CLINICAL SIGNS

Grayton Eisenlohr

- BCS 6/9

SPECIES

Canine

- Prophylactic double cavity u/s
- Testicles asymmetrical-first noted July 2024 (R teste smaller than left)

BREED

Golden Retriever

- No heart murmur
- No current meds

SEX

Intact Male

- Abnormal PE/Chem/CBC/UA Results: WNL; UA: not performed

AGE

5 Years 8 Months

WEIGHT

87 Pounds

ULTRASONOGRAPHIC EXAMINATION OF THE HEART & ABDOMEN

INTERPRETED BY

Eric Lindquist, DMV,
 DABVP (Canine &
 Feline), Cert. IVUSS

CANINE CARDIAC PARAMETERS	MR VMAX (m/s)	TR VMAX (m/s)	LA/AO (M-Mode)	LA/AO (Heart Base; Swe)	FS (%)	EF (%)	EPSS (cm)
NORMAL PARAMETER	4.5-5.5	<2.7	1.3	Up to 1.6	28-40	40-100	<0.6
PATIENT	--	--	1.1	--	30	58	0.3
CANINE CARDIAC PARAMETERS	HR (BPM)	AV VMAX (m/s)	PV MAX (m/s)	BODY WEIGHT (lbs)	LAD LA MAX 4 Chamber	LVIDd Avg; 2D and m-mode short axis (cm)	LVIDs Avg; 2D and m-mode short axis (cm)
NORMAL PARAMETER	50-100	0.7-1.7	0.7-1.6				
PATIENT	168	1.57	1.00	87 lbs	--	3.4	--

IMAGING PERFORMED BY

Shari Reffi, CVT

HOSPITAL NAME

Black River VH

E-wave velocity: 0.8

Cardiac Presentation

REFERRING VET

Dr. Abby Earl

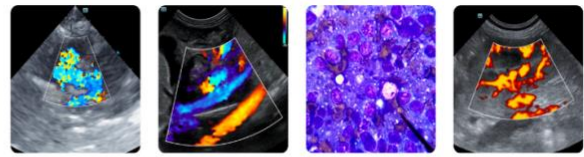
The echocardiogram in this patient demonstrated normal **left atrial** size based on 3 separate methods of LA evaluation. The cranial and caudal **mitral** valve leaflets presented normal linear structure, extension in systole, and union in diastole with normal kinesis. The **left ventricle** presented thicknesses with linear contour and was not dilated nor restricted. The **myocardium** presented normal echogenicity without subjective evidence of significant fibrotic or ischemic disease. **Contractility** of the ventricular walls was adequate and in normal range for this patient evidenced by the fractional shortening measurement and subjective evaluation of the different regions of the myocardium. The **left ventricular outflow** tract demonstrated normal laminar flow and subjective structural integrity. The **right atrium** and auricle revealed normal size, structure and content. No evidence of masses was noted. **Tricuspid** valvular assessment demonstrated adequate linear morphology and kinesis. The **right ventricle** was of normal size (1/3 diameter of LV), chordae structure, myocardial echogenicity and thickness. **Pulmonary outflow** tract assessment revealed normal valve structure, laminar flow, and

INVOICE

36408

DATE

3/27/26



PATIENT

Grayton Eisenlohr

SPECIES

Canine

BREED

Golden Retriever

SEX

Intact Male

AGE

5 Years 8 Months

WEIGHT

87 Pounds

INTERPRETED BY

Eric Lindquist, DMV,
DABVP (Canine &
Feline), Cert. IVUSS

IMAGING PERFORMED BY

Shari Reffi, CVT

HOSPITAL NAME

Black River VH

REFERRING VET

Dr. Abby Earl

INVOICE

36408

DATE

3/27/26

diameter (approx.1:1 pa/ao ratio). No visible **pericardial** or free pleura fluid was noted. The cranial **mediastinum and pericardial and extra-cardiac regions** were free of masses in the visible window.

Urinary System

The **urinary bladder**, trigone, and pelvic urethra presented normal thicknesses and normal tone. The ureters were not visible which is normal. No uroliths or sediment were visualized and anechoic urine was present. No evidence of inflammatory or neoplastic changes were noted. Ureteral papillae were normal.

The **prostate** was uniformly enlarged (4.1 cm) with lobar swelling appeared to impinge upon the urethra and mildly deviate the descending colon. The prostatic tissue was hyperechoic containing focal areas of decreased echogenicity. These changes are suggestive of either chronic inflammatory episodes, benign cystic pathology or both. Underlying neoplasia cannot be completely ruled out but is lower on the differential list. This presentation is most consistent with benign prostatic hyperplasia with possible active prostatitis. Neutering or off-label Finasteride (Propecia) (0.1-0.5 mg/kg Sid) treatment is indicated +/- FNA or prostatic wash cytology and culture. This is a mild change. Slight edema lines were noted in this patient, and mild swelling.

The **testicles** were imaged and revealed normal contour and parenchymal patterns. The right testicle measured 2.5 cm. The left testicle measured 4.38 cm.

The **kidneys** revealed normal size and structure, corticomedullary definition and ratio for this age. The cortices presented largely uniform texture with normal echogenic relationship to liver and spleen. Medullary structure differed distinctly from the cortex and no evidence of pelvic dilation was present. The capsules were acceptably uniform without significant irregularities. The left kidney measured 6.35 cm. The right kidney measured 6.35 cm.

Adrenal Glands

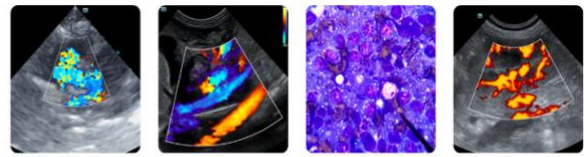
Both **adrenal glands** were visualized and recognized as having normal shape, size, position and echogenicity for this breed. The phrenic vasculature, glandular echogenicity and detail were unremarkable. Capsule, cortex, and medullary definition were normal for this age patient. The left adrenal gland measured 0.47 cm at the cranial pole and 0.47 cm at the caudal pole. The right adrenal gland measured 1.5 cm at the cranial pole and 0.86 cm at the caudal pole.

Spleen

The **spleen** presented a smooth homogeneous parenchyma hyperechoic to liver and renal cortical parenchyma. The capsule was smooth without noticeable expansion or deviation from within the spleen or adjacent pathology. The splenic vasculature demonstrated normal volume without signs of congestion or thrombosis. No sonographic evidence of acute or chronic inflammatory, neoplastic, or infarctual changes were noted. Cranial and caudal folding of the spleen was noted, normal positional variant.

Liver

The **liver** images submitted revealed subjectively normal liver size, contour, and structure. Parenchymal echogenicity was naturally coarse and hypoechoic to the spleen. Vascular and biliary tracts were of normal volume with no evidence of congestion. The gallbladder presented acceptably thin walls with primarily anechoic content. The cystic and common bile ducts were normal. No



PATIENT

Grayton Eisenlohr

SPECIES

Canine

BREED

Golden Retriever

SEX

Intact Male

AGE

5 Years 8 Months

WEIGHT

87 Pounds

INTERPRETED BY

Eric Lindquist, DMV,
DABVP (Canine &
Feline), Cert. IVUSS

IMAGING PERFORMED BY

Shari Reffi, CVT

HOSPITAL NAME

Black River VH

REFERRING VET

Dr. Abby Earl

INVOICE

36408

DATE

3/27/26

pathological hepatic lymphadenopathy was evident. No overt structural evidence of inflammatory, infiltrative or regenerative pathology was evident.

Gastrointestinal

Examination of the **gastrointestinal tract** revealed a stomach and intestine free of stasis, of normal wall thickness, acceptable curvilinear mural detail, and peristaltic activity. Small and large intestine demonstrated normal luminal chyme and stool consistency respectively. No obstructive or overt infiltrative disease was noted. No associated abnormal lymphatic activity was noted.

Pancreas

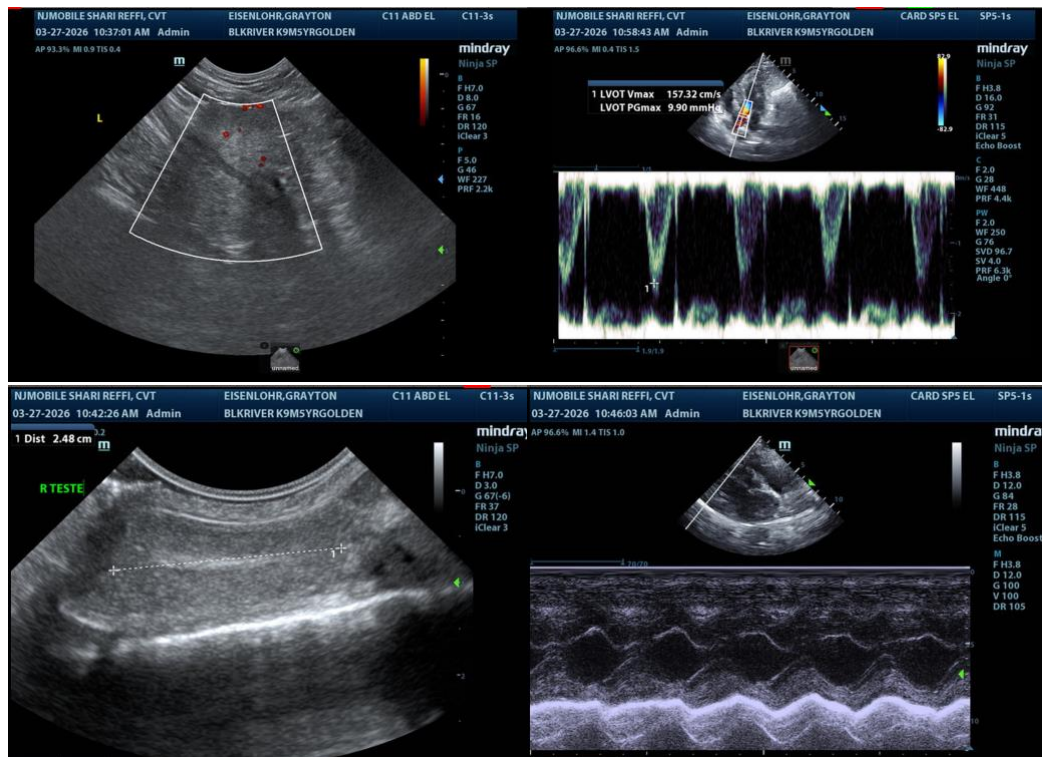
The base and limbs of the **pancreas** were observed to be largely isoechoic to surrounding omental fat. Pancreatic duct and capsular contour were acceptably normal and parenchyma respected normal curvilinear patterns. No overt evidence of active inflammatory or neoplastic disease was noted.

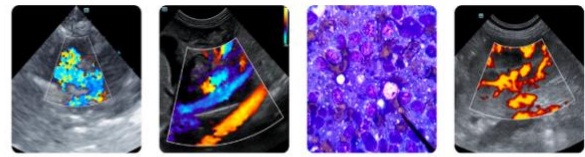
ULTRASONOGRAPHIC FINDINGS

- Structurally unremarkable abdomen and heart
- BPH prostate/minor prostatitis pattern
- Subnormal right testicle, normal variant
- Cranial and caudal splenic folding, normal positional variant

INTERPRETATION OF THE FINDINGS & FURTHER RECOMMENDATIONS

No evidence of pathology.





PATIENT

Grayton Eisenlohr

SPECIES

Canine

BREED

Golden Retriever

SEX

Intact Male

AGE

5 Years 8 Months

WEIGHT

87 Pounds

INTERPRETED BY

Eric Lindquist, DMV,
 DABVP (Canine &
 Feline), Cert. IVUSS

IMAGING PERFORMED BY

Shari Reffi, CVT

HOSPITAL NAME

Black River VH

REFERRING VET

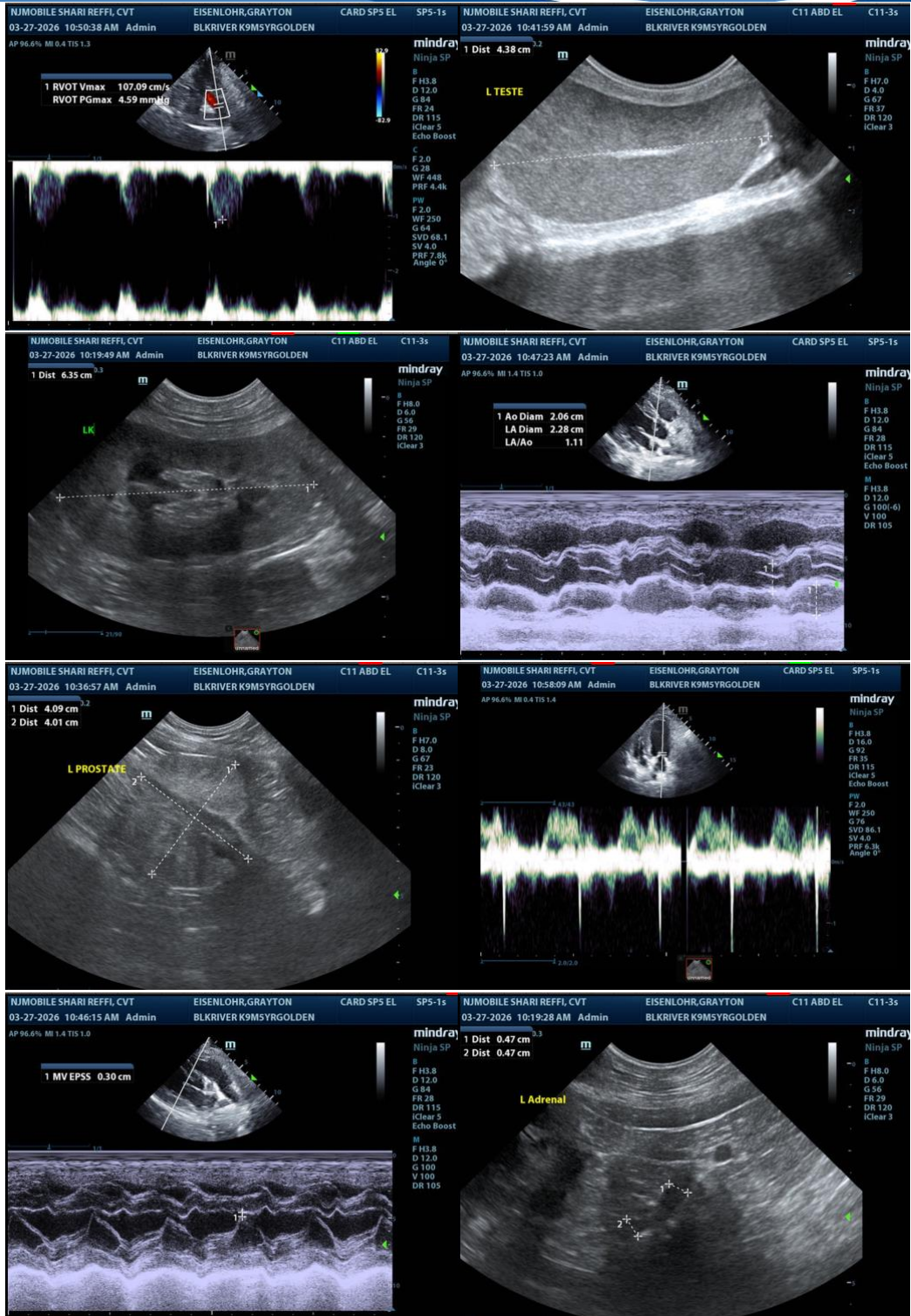
Dr. Abby Earl

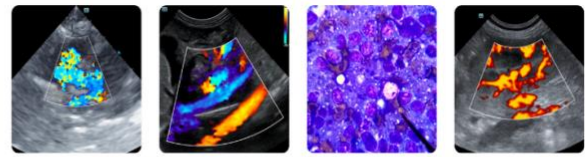
INVOICE

36408

DATE

3/27/26





PATIENT

Grayton Eisenlohr

SPECIES

Canine

BREED

Golden Retriever

SEX

Intact Male

AGE

5 Years 8 Months

WEIGHT

87 Pounds

INTERPRETED BY

Eric Lindquist, DMV,
 DABVP (Canine &
 Feline), Cert. IVUSS

IMAGING PERFORMED BY

Shari Reffi, CVT

HOSPITAL NAME

Black River VH

REFERRING VET

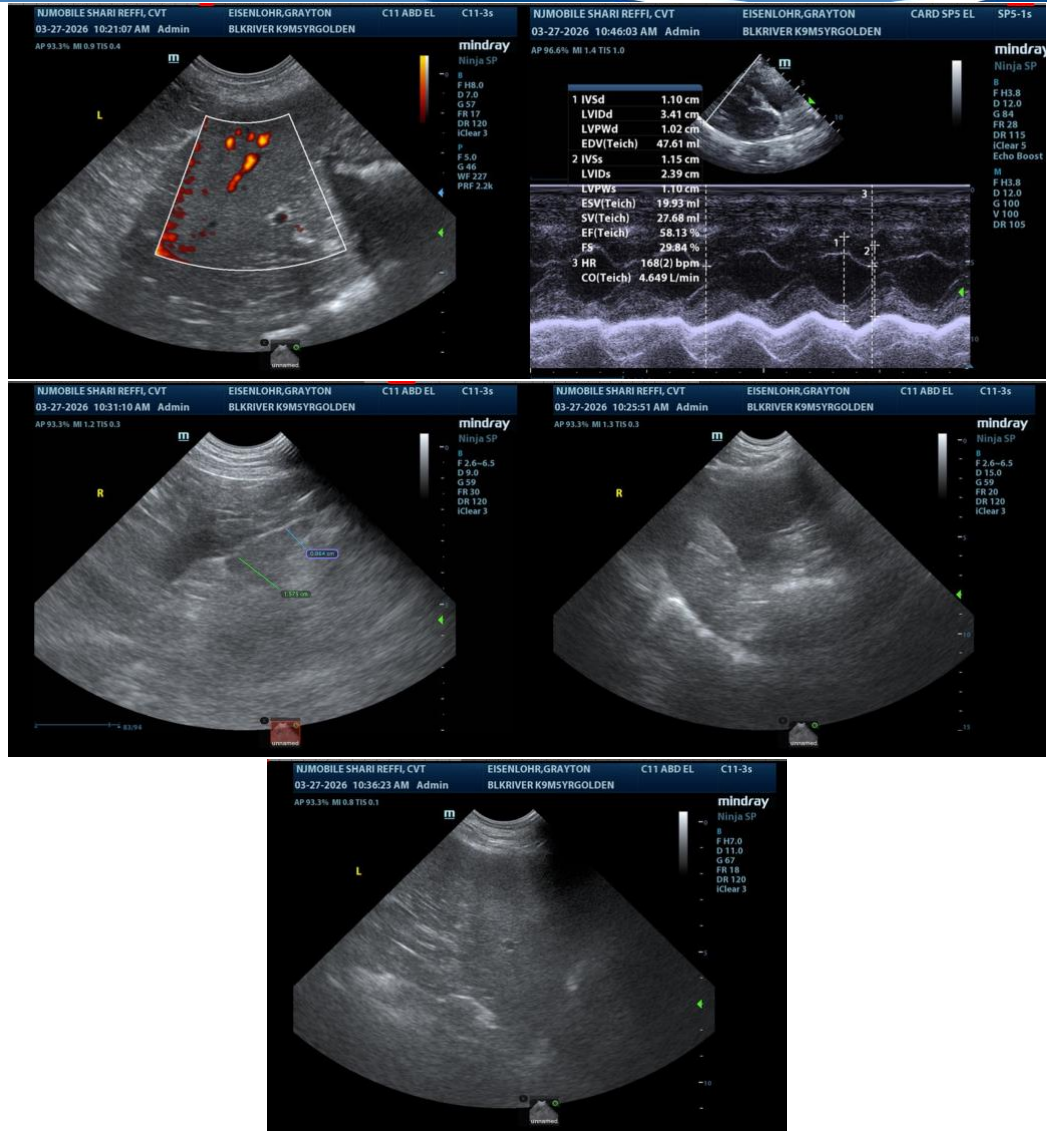
Dr. Abby Earl

INVOICE

36408

DATE

3/27/26



The information and recommendations provided are based on the images presented by the referring veterinarian/sonographer. No evaluation can be communicated regarding pathology that was not visible in the image/video clips provided.

Thank you for this referral. If the clinical or image interpretation does not parallel your findings or if I can be of any further assistance please contact me.

Eric Lindquist, DMV, DABVP(CFM), Cert. IVUSS,
 CEO, Owner, Founder -- SonoPath.com
info@SonoPath.com