



PATIENT

Chex Panak

SPECIES

Feline

BREED

DSH

SEX

Spayed Female

AGE

7 Years

WEIGHT

13.8 pounds

INTERPRETED BY

Eric Lindquist, DMV,
DABVP(CFM), Cert.
IVUSS

IMAGING PERFORMED BY

Chloe Lowe CVT

HOSPITAL NAME

Harmony Animal
Hospital

REFERRING VET

Dr. Gruber

INVOICE

14664

DATE

03/27/26

PRESENTING CLINICAL SIGNS

- Diane's caused by pleural effusion
- transferred from Barton Heights
- gabapentin PO BID, clopidogrel 1/4 tab PO q 2 hours, benazepril 1/2 tab POq 2 hours, furosemide PO BID

Abnormal PE/Chem/CBC/UA Results: BNP abnormal Decreased ALP, otherwise cbc/chem WNL

ULTRASONOGRAPHIC EXAMINATION OF THE HEART

FELINE CARDIAC PARAMETERS	BODY WEIGHT (lbs)	HR (BPM)	IVSd (cm)	LVIDd (cm)	LVWd (cm)	FS (%)	EF (%)
NORMAL PARAMETER	-----	150-240	0.3-0.6	1.0-2.1	0.25-0.6	35-67	80-100
PATIENT	13.8	NM	0.47	2.0	0.47	15	--
FELINE CARDIAC PARAMETERS	LA/AO (M-mode)	LA/AO HEART BASE (Sisson)	LAD LA MAX 4 Chamber	LVOT VEL. (m/s)	RVOT VEL. (m/s)	IVRT (m/)	
NORMAL PARAMETER	<1.5	1.6	0.7-1.7	<1.6	<1.3	40-60	
PATIENT	2.5	--	1.8	0.9	1.0	NM	

Adapted from June Boon, Veterinary Echocardiography, 1998
Sisson D et al. JVIM 1991; 5: 232, Jacobs et al. Am J Vet Res 1985; 46:1705

EPSS: 0.7 // MR: 5.0 m/s // TR: 3.0 m/s

Cardiac Presentation

Cardiac presentation in this patient presented with volume overload of all four chambers. Myocardial thinning and hypocontractility. Both left and right-sided heart failure present with slight pericardial effusion and pleural effusion with hepatic vein dilation. EPSS was excessive consistent with DCM.

ULTRASONOGRAPHIC FINDINGS

- DCM type presentation with left/right-sided heart failure- possible myocarditis or nutritional cardiomyopathy.

INTERPRETATION OF THE FINDINGS & FURTHER RECOMMENDATIONS

Recommend Taurine supplementation and level assessment. LASIX at 12.5 mg BID diminishing to minimal effective dose over the next 40-72 hours. Plavix therapy at 16.25 mg SID, Pimobendan off-label 0.3 mg/kg BID, and ACE inhibitor 0.5 mg/kg SID. Recheck echo in 10 to 14 days. I recommend continuation of the Benazepril and Furosemide, yet likely necessary increase to 12.5 mg BID depending on the current dose. Recommend adding Pimobendan 0.3 mg/kg BID. Infectious agents should be considered as myocarditis can present in this type of presentation. Prognosis is guarded. Heat and oxygen support is likely necessary in this patient.



PATIENT

Chex Panak

SPECIES

Feline

BREED

DSH

SEX

Spayed Female

AGE

7 Years

WEIGHT

13.8 pounds

INTERPRETED BY

Eric Lindquist, DMV,
 DABVP(CFM), Cert.
 IVUSS

IMAGING PERFORMED BY

Chloe Lowe CVT

HOSPITAL NAME

Harmony Animal
 Hospital

REFERRING VET

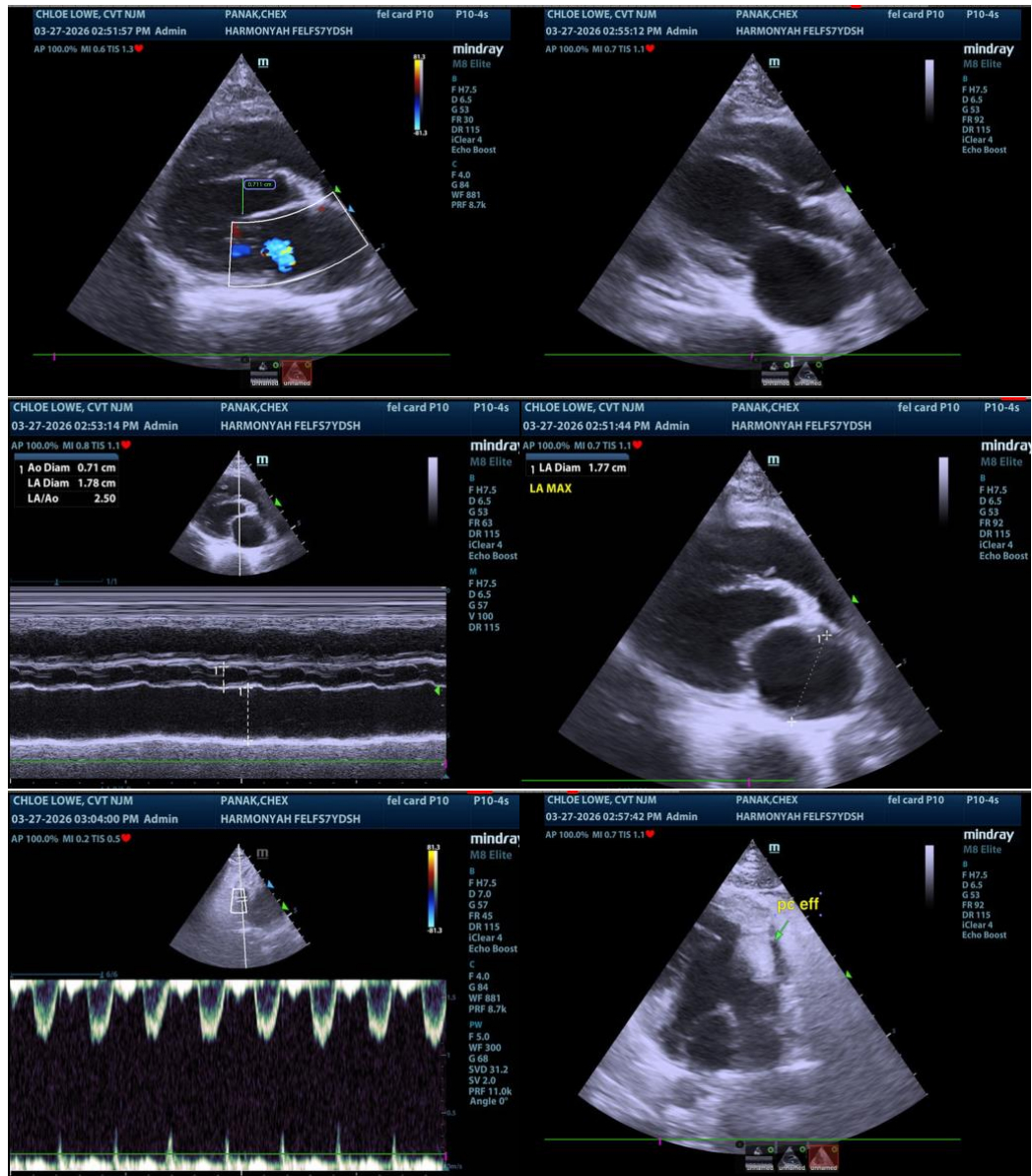
Dr. Gruber

INVOICE

14664

DATE

03/27/26





PATIENT

Chex Panak

SPECIES

Feline

BREED

DSH

SEX

Spayed Female

AGE

7 Years

WEIGHT

13.8 pounds

INTERPRETED BY

Eric Lindquist, DMV,
 DABVP(CFM), Cert.
 IVUSS

IMAGING PERFORMED BY

Chloe Lowe CVT

HOSPITAL NAME

Harmony Animal
 Hospital

REFERRING VET

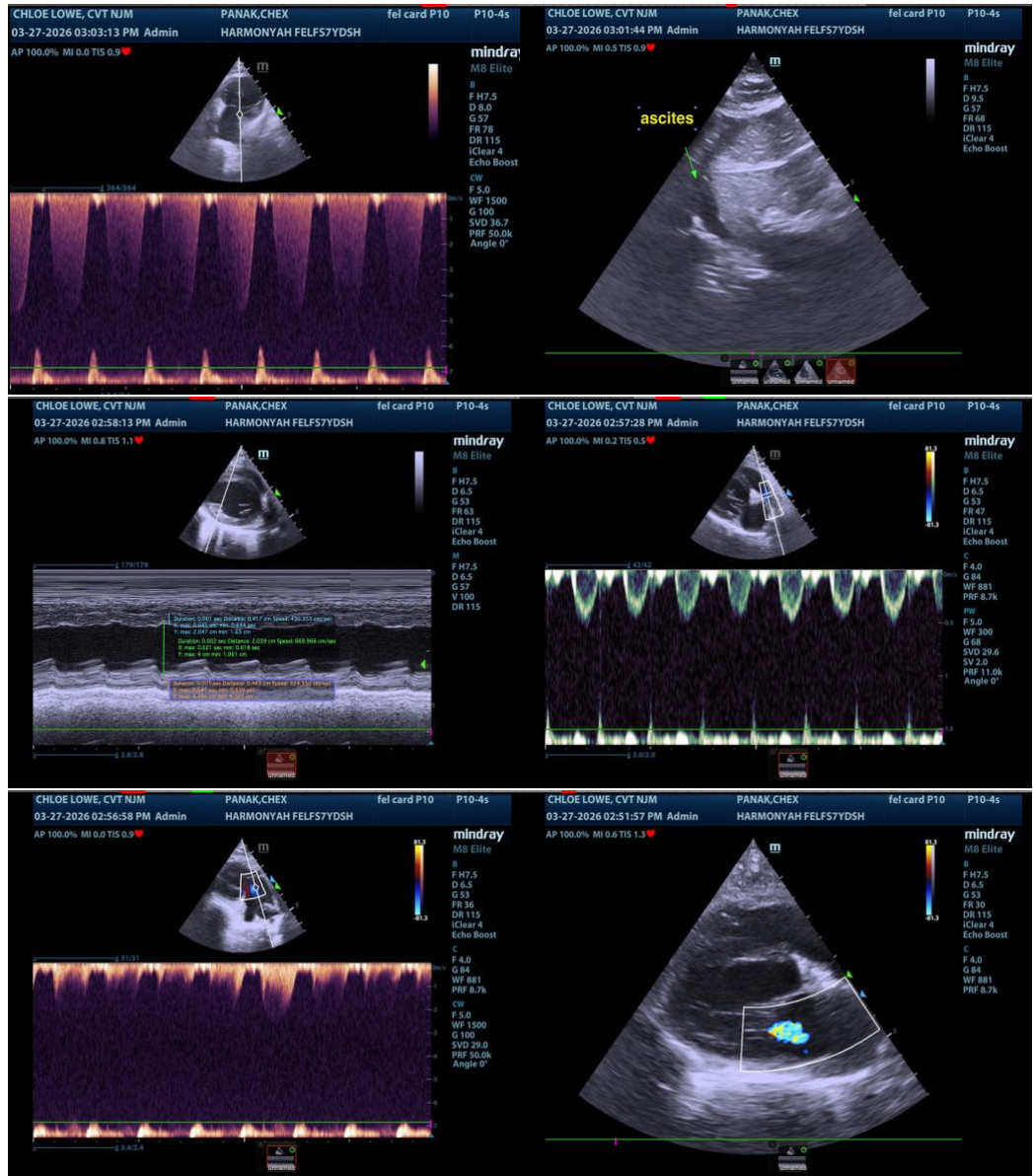
Dr. Gruber

INVOICE

14664

DATE

03/27/26



The information and recommendations provided are based on the images presented by the referring veterinarian/sonographer. No evaluation can be communicated regarding pathology that was not visible in the image/video clips provided.

Thank you for this referral. If the clinical or image interpretation does not parallel your findings or if I can be of any further assistance, please contact me.

Eric Lindquist, DMV, DABVP(CFM), Cert. IVUSS,

CEO, Owner, Founder -- SonoPath.com

info@SonoPath.com



PATIENT

Chex Panak

SPECIES

Feline

BREED

DSH

SEX

Spayed Female

AGE

7 Years

WEIGHT

13.8 pounds

INTERPRETED BY

Eric Lindquist, DMV,
DABVP(CFM), Cert.
IVUSS

**IMAGING
PERFORMED BY**

Chloe Lowe CVT

HOSPITAL NAME

Harmony Animal
Hospital

REFERRING VET

Dr. Gruber

INVOICE

14664

DATE

03/27/26