



**PATIENT**

Bogoo Alvarez

**SPECIES**

Canine

**BREED**

Dachshund

**SEX**

Neutered Male

**AGE**

15 Years

**WEIGHT**

16.12 Pounds

**INTERPRETED BY**

Eric Lindquist, DMV,  
 DABVP (Canine & Feline), Cert. IVUSS

**IMAGING PERFORMED BY**

Vincent Ravancho,  
 CVT

**HOSPITAL NAME**

Vetco Hackensack

**REFERRING VET**

Dr. Jammes

**INVOICE**

36411

**DATE**

3/27/26

**PRESENTING CLINICAL SIGNS**

- Recheck U/S; last scanned 3/6/2026
- Started medications after last echo - Vetmedin 1.25mg - 1.5 tab q12hrs, Furosemide 12.5mg 1 tab AM, 1/1 tab PM

**ULTRASONOGRAPHIC EXAMINATION OF THE HEART**

| CANINE CARDIAC PARAMETERS | MR VMAX (m/s) | TR VMAX (m/s) | LA/AO (M-Mode) | LA/AO (Heart Base; Swe) | FS (%)               | EF (%)                                   | EPSS (cm)                                |
|---------------------------|---------------|---------------|----------------|-------------------------|----------------------|--|--|
| NORMAL PARAMETER          | 4.5-5.5       | <2.7          | 1.3            | Up to 1.6               | 28-40                | 40-100                                   | <0.6                                     |
| PATIENT                   | 5.67          | 2.5           | 2.16           | 1.9                     | 40                   | 72                                       | 0.1                                      |
| CANINE CARDIAC PARAMETERS | HR (BPM)      | AV VMAX (m/s) | PV MAX (m/s)   | BODY WEIGHT (lbs)       | LAD LA MAX 4 Chamber | LVIDd Avg; 2D and m-mode short axis (cm) | LVIDs Avg; 2D and m-mode short axis (cm) |
| NORMAL PARAMETER          | 50-100        | 0.7-1.7       | 0.7-1.6        |                         |                      |  |  |
| PATIENT                   | 95            | 1.60          | .90            | 16.12 lbs               | 3.9                  | 2.88                                     | --                                       |

**Cardiac Presentation**

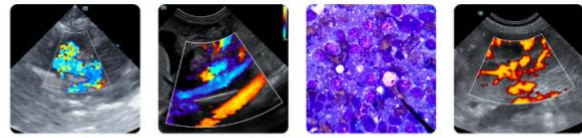
The cardiac presentation has improved in volume and contractility. Mild persistent left atrial enlargement was noted. Prolapse of the anterior mitral valve leaflet was noted. Mitral and tricuspid insufficiency were noted. No pericardial or pleural effusion were noted. The right atrium and right ventricle were unremarkable. Occasional arrhythmia was noted in this patient.

**ULTRASONOGRAPHIC FINDINGS**

- Valvular disease with persistent mild left sided volume overload – significant improvement from the prior echocardiogram.
- Tricuspid insufficiency
- Occasional arrhythmia

**INTERPRETATION OF THE FINDINGS & FURTHER RECOMMENDATIONS**

Recommend adding an ACE inhibitor to this current protocol, at a dose of 0.5 mg/kg SID, progressing to BID, then recheck echo in 6 months if stable. Monitoring blood pressure and basil respiratory rate are recommended.



**PATIENT**

Bogoo Alvarez

**SPECIES**

Canine

**BREED**

Dachshund

**SEX**

Neutered Male

**AGE**

15 Years

**WEIGHT**

16.12 Pounds

**INTERPRETED BY**

Eric Lindquist, DMV,  
 DABVP (Canine &  
 Feline), Cert. IVUSS

**IMAGING  
 PERFORMED BY**

Vincent Ravancho,  
 CVT

**HOSPITAL NAME**

Vetco Hackensack

**REFERRING VET**

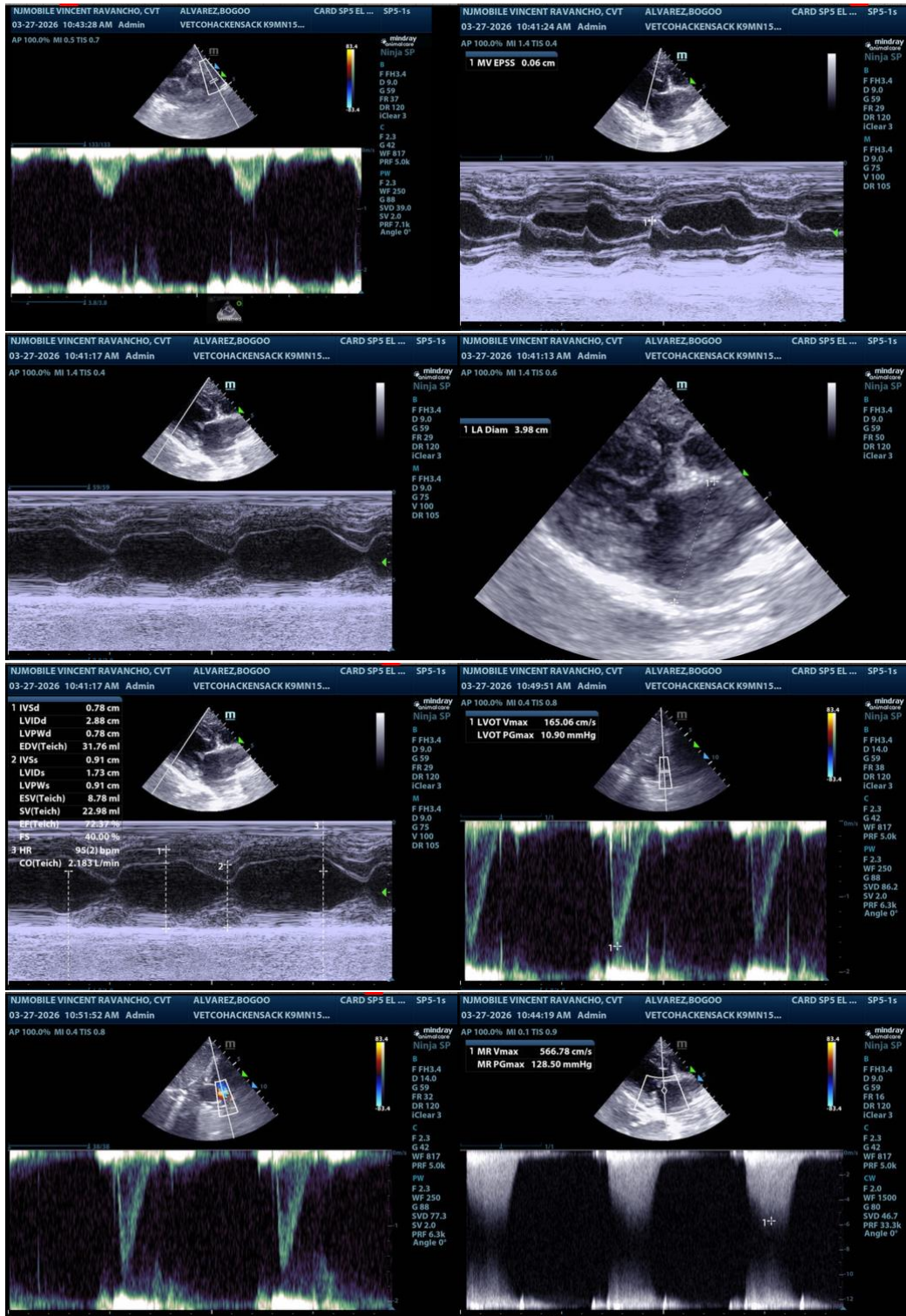
Dr. Jammes

**INVOICE**

36411

**DATE**

3/27/26





**PATIENT**

Bogoo Alvarez

**SPECIES**

Canine

**BREED**

Dachshund

**SEX**

Neutered Male

**AGE**

15 Years

**WEIGHT**

16.12 Pounds

**INTERPRETED BY**

Eric Lindquist, DMV,  
 DABVP (Canine &  
 Feline), Cert. IVUSS

**IMAGING PERFORMED BY**

Vincent Ravancho,  
 CVT

**HOSPITAL NAME**

Vetco Hackensack

**REFERRING VET**

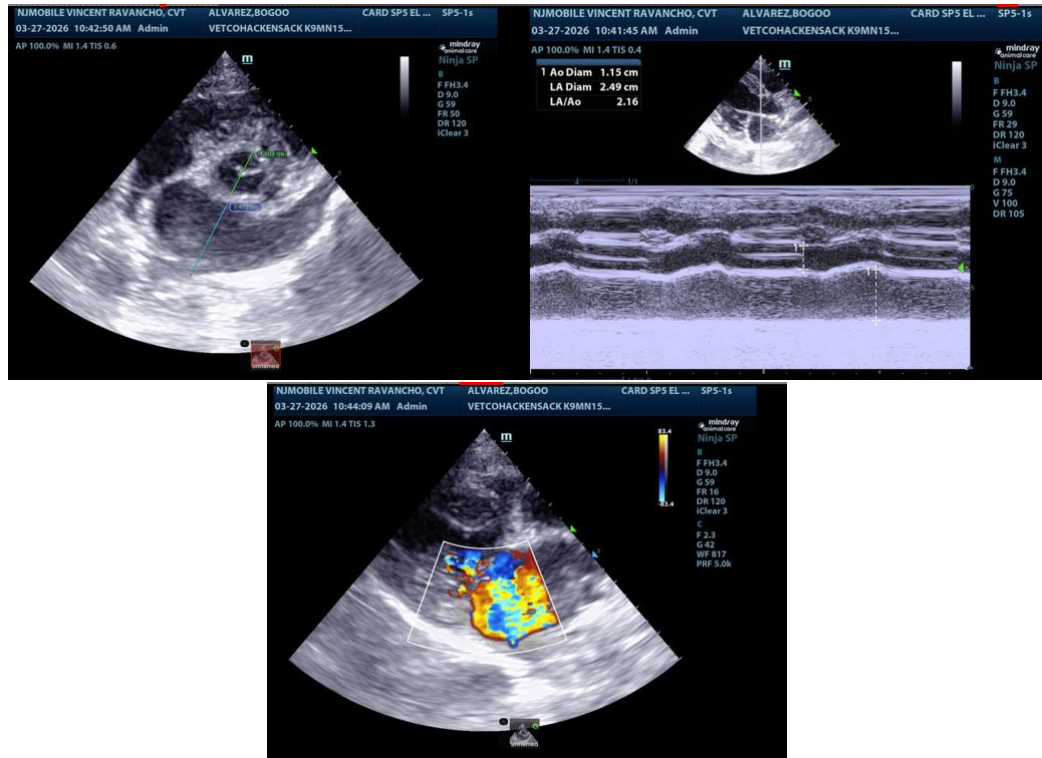
Dr. Jammes

**INVOICE**

36411

**DATE**

3/27/26



The information and recommendations provided are based on the images presented by the referring veterinarian/sonographer. No evaluation can be communicated regarding pathology that was not visible in the image/video clips provided.

Thank you for this referral. If the clinical or image interpretation does not parallel your findings or if I can be of any further assistance please contact me.

**Eric Lindquist, DMV, DABVP(CFM), Cert. IVUSS,**  
 CEO, Owner, Founder -- SonoPath.com  
[info@SonoPath.com](mailto:info@SonoPath.com)