



PATIENT PRESENTING CLINICAL SIGNS

Mouse Mays

History: Patient has new heart murmur. Patient has history of GI disease, pancreatitis, laryngeal mass, CRD and is on prednisone and maropitant long-term.

SPECIES

Abnormal PE/Chem/CBC/UA Results: I-II/VI systolic murmur. Anemia hematocrit 24.2%, Hb 7.5 g/dl. ProBNP normal 57 pmol/l Spec cPL 6.0 ug/l SDMA 21 ug/dl T4 is normal

Feline

BREED

Domestic Shorthair

SEX

Neutered male

AGE

18 years

WEIGHT

9.88 lbs

ULTRASONOGRAPHIC EXAMINATION OF THE HEART

The echocardiogram in this patient demonstrated normal **left atrial** size based on 3 separate LA measurements. The cranial and caudal **mitral** valve leaflets presented normal linear structure and kinetics. The **left ventricle** presented normal thicknesses with linear contour and was not dilated nor restricted. The **myocardium** presented normal echogenicity without subjective evidence of significant fibrotic or ischemic disease. **Contractility** of the ventricular walls was adequate and in normal range for this patient evidenced by the fractional shortening measurement and subjective evaluation of the different regions and angles of the myocardium. The **left ventricular outflow** tract demonstrated normal laminar flow and subjective structural integrity. The **right atrium** and auricle revealed normal size, structure and content. No evidence of masses was noted or chamber overload. **Tricuspid** valvular assessment demonstrated adequate linear morphology and kinetics. The **right ventricle** was of normal size (1/3 diameter of LV), chordae structure, myocardial echogenicity and thickness. **Pulmonic** tract assessment revealed normal valve structure, laminar flow, and diameter (approx. 1:1 pa/ao ratio). No visible **pericardial** or free pleura fluid was noted or extra cardiac pathology in the visible planes. The cranial **mediastinum and pericardial regions** were free of masses in the visible window.

INTERPRETED BY

Eric Lindquist, DMV
DABVP, Cert. IVUSS

IMAGING PERFORMED BY

Judy Schroeder

HOSPITAL NAME

Animal Health Associates

REFERRING VET

Dr. Schroeder

FELINE CARDIAC PARAMETERS	BODY WEIGHT (kg)	HR (BPM)	IVSd (cm)	LVIDd (cm)	LVWd (cm)	FS (%)	EF (%)
NORMAL PARAMETER	-----	150-240	0.3-0.6	1.0-2.1	0.25-0.6	35-67	80-100
PATIENT		NM	0.5	1.3	0.5	50	
FELINE CARDIAC PARAMETERS	LA/AO (Boon)	LA/AO HEART BASE (Sisson)	LA 2D 4-chamber long axis AS to FW (Sisson) (cm)	LVOT VEL. (m/s)	RVOT VEL. (m/s)	IVRT (m/)	
NORMAL PARAMETER	<1.5	0.88-1.79	0.7-1.7	<1.6	<1.3	40-60	
PATIENT	1.3	1.3	1.2 max	1.0		NM	
Adapted from June Boon, Veterinary Echocardiography, 1998 Sisson D et al. JVIM 1991; 5: 232, Jacobs et al. Am J Vet Res 1985; 46:1705							

INVOICE

43513

DATE

3/27/23



PATIENT

Mouse Mays

ULTRASONOGRAPHIC FINDINGS

Normal echocardiogram.

SPECIES

Feline

INTERPRETATION OF THE FINDINGS & FURTHER RECOMMENDATIONS

There is no evidence of pathology. There is no contraindication to anesthetic procedure if necessary. This is likely a flow murmur.

BREED

Domestic Shorthair

Benign flow murmurs are common in cats. This may be owing to volume shifts, tachycardia, benign (DRVOTO) right ventricular outflow changes, trivial turbulence in any of the valvular apparatuses, or possibly excessive stethoscope pressure against the chest according to a recent study These are physiologically benign and unrelated to specific pathology.

SEX

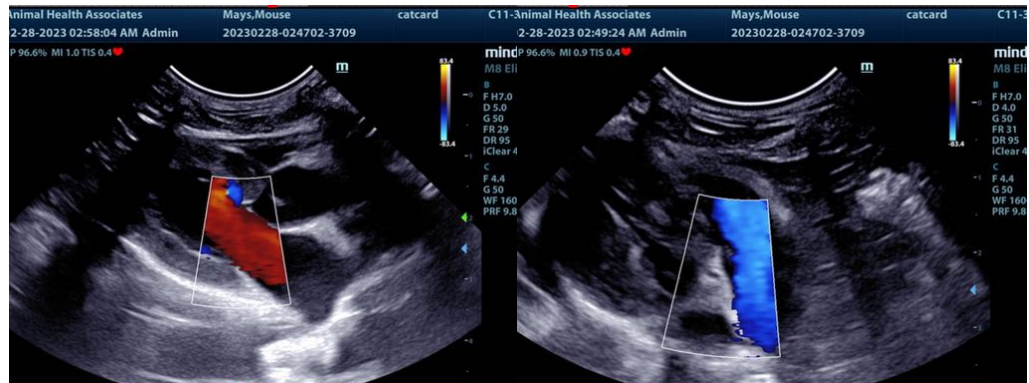
Neutered male

AGE

18 years

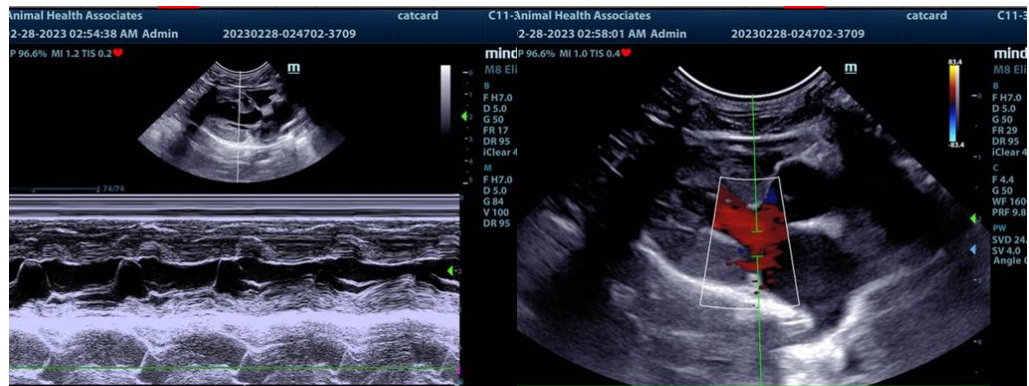
WEIGHT

9.88 lbs



INTERPRETED BY

Eric Lindquist, DMV
DABVP, Cert. IVUSS



IMAGING PERFORMED BY

Judy Schroeder

HOSPITAL NAME

Animal Health Associates

REFERRING VET

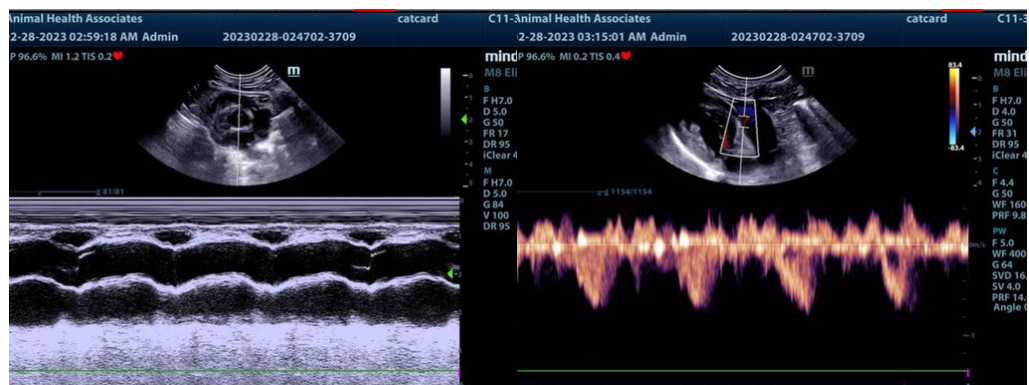
Dr. Schroeder

INVOICE

43513

DATE

3/27/23





PATIENT

Mouse Mays

SPECIES

Feline

BREED

Domestic Shorthair

SEX

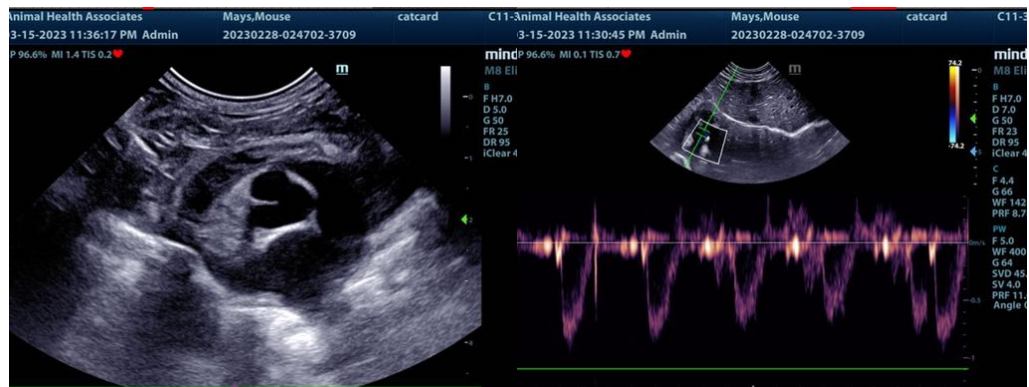
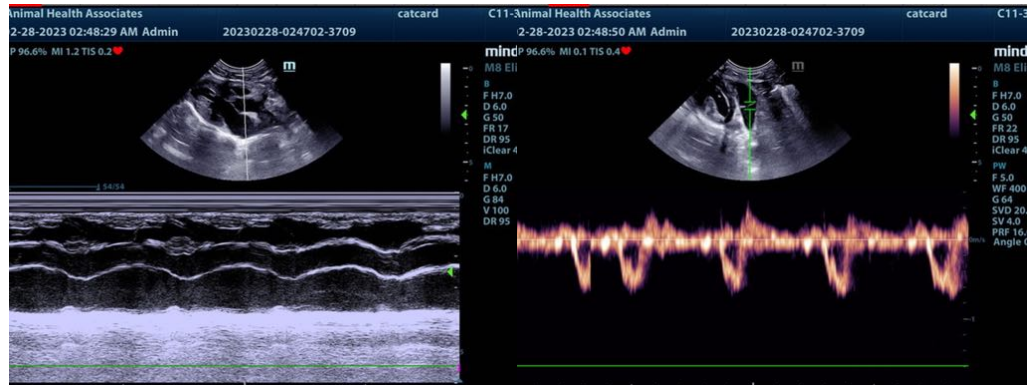Neutered male

AGE

18 years

WEIGHT

9.88 lbs



INTERPRETED BY

Eric Lindquist, DMV
DABVP, Cert. IVUSS

IMAGING PERFORMED BY

Judy Schroeder

HOSPITAL NAME

Animal Health
Associates

REFERRING VET

Dr. Schroeder

INVOICE

43513

DATE

3/27/23

The information and recommendations provided are based on the images presented by the referring veterinarian/sonographer. No evaluation can be communicated regarding pathology that was not visible in the image/video clips provided.

Thank you for this referral. If the clinical or image interpretation does not parallel your findings or if I can be of any further assistance please contact me.

Eric Lindquist, DMV, DABVP, Cert. IVUSS, CEO of SonoPath.com
info@SonoPath.com