



PATIENT

Lucy Trotter

SPECIES

Canine

BREED

Wire-haired
Dachshund

SEX

Spayed female

AGE

9 years

WEIGHT

5.4 lbs

INTERPRETED BY

Eric Lindquist, DMV
DABVP, Cert. IVUSS

**IMAGING
PERFORMED BY**

Dr. Striano Kaplan

HOSPITAL NAME

Ramsey VH

REFERRING VET

Dr. Striano Kaplan

INVOICE

43512

DATE

3/27/23

PRESENTING CLINICAL SIGNS

History: Weight loss, with good appetite. Rads performed at OAH non-remarkable. L ileal fracture secondary to trauma.

Abnormal PE/Chem/CBC/UA Results: Geriatric pending, BP: 190 today (pet stressed) 5/6/22 UA: USH 1.034; trace protein UPC 0.1 T4 2.5; Chem: Alb 3.1; Chol 164 CBC: WBC 5.1; Neut 3315 (65%); Lym 1091 (21.4%); Mono 383 (7.5%); Eos 281 (5.5%); Baso 31 (0.6%) 4Dx neg Fecal: neg Resting Cortisol: Normal

ULTRASONOGRAPHIC EXAMINATION OF THE ABDOMEN

Urinary System

The **urinary bladder**, trigone, and pelvic urethra presented normal thicknesses and normal tone. The ureters were not visible which is normal. No uroliths or sediment were visualized and anechoic urine was present. No evidence of inflammatory or neoplastic changes was noted. Ureteral papillae were normal.

The **kidneys** revealed largely normal size and structure, corticomedullary definition and ratio (cortex 1/3 of medulla) were essentially maintained with some age-related loss of curvilinear patterns regarding the capsule and C/M junction. The cortices presented largely uniform texture with some increased echogenicity expected for his age patient. Medullary structure differed distinctly from that of the cortex and no evidence of pelvic dilation was present. The left kidney measured 3.23 cm. The right kidney measured 3.27 cm.

Adrenal Glands

Both **adrenal glands** were visualized and recognized as having normal shape, size, position and echogenicity for this breed. The phrenic vasculature, glandular echogenicity and detail were unremarkable. Capsule, cortex, and medullary definition were normal for this age patient.

Spleen

The **spleen** in this patient was uniform, yet volume contracted. Hydration status should be assessed.

Liver

The **liver** images submitted revealed subjectively normal liver size, contour, and structure. Parenchymal echogenicity was naturally coarse and hypoechoic to the spleen. Vascular and biliary tracts were of normal volume with no evidence of congestion. The gallbladder presented acceptably thin walls with primarily anechoic content. The cystic and common bile ducts were normal. No pathological hepatic lymphadenopathy was evident. No overt structural evidence of inflammatory, infiltrative or regenerative pathology was evident.



PATIENT

Lucy Trotter

SPECIES

Canine

BREED

Wire-haired
Dachshund

SEX

Spayed female

AGE

9 years

WEIGHT

5.4 lbs

Gastrointestinal

The **gastrointestinal** presentation revealed mild uniform prominence of the gastric mucosa as well as areas of "ropey" small intestinal wall with slight disruption of the normal 1:3 muscularis/mucosal ratio. The intestinal submucosa was slightly irregular, thickened and hyperechoic suggestive of low grade, chronic disease. No concerning lymphadenopathy was visible. No evidence of obstruction was present. Chronic inflammatory bowel disease is likely with a low possibility of an early neoplastic event such as lymphoma. Full thickness tissue biopsies via open laparotomy, ideally guided by intraoperative ultrasound in order to obtain the most representative mural sample, would be necessary to rule out this possibility.

Pancreas

The base and limbs of the **pancreas** were observed to be largely isoechoic to surrounding omental fat. Pancreatic duct and capsular contour were acceptably normal and parenchyma respected normal curvilinear patterns. No overt evidence of active inflammatory or neoplastic disease was noted.

ULTRASONOGRAPHIC FINDINGS

Structurally unremarkable abdomen.

Minor gastrointestinal thickening.

INTERPRETATION OF THE FINDINGS & FURTHER RECOMMENDATIONS

Dietary indiscretion, food intolerance, structurally significant inflammatory bowel or occult parasitism and occult Addison's are all potentials.

INTERPRETED BY

Eric Lindquist, DMV
DABVP, Cert. IVUS

IMAGING PERFORMED BY

Dr. Striano Kaplan

HOSPITAL NAME

Ramsey VH

REFERRING VET

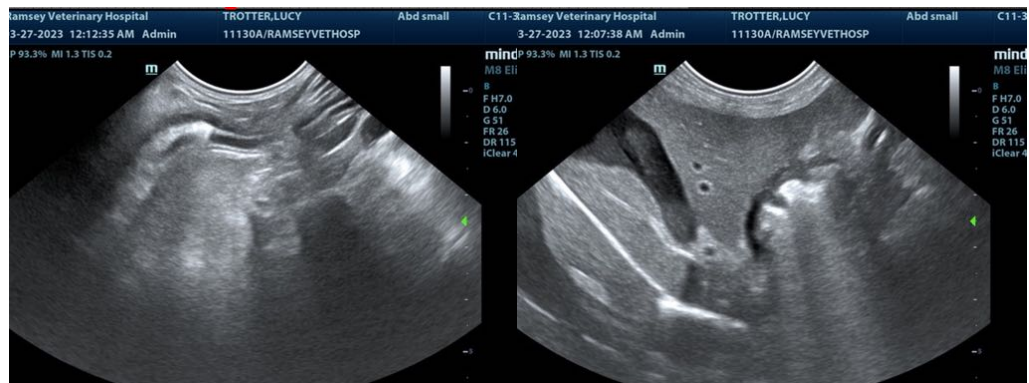
Dr. Striano Kaplan

INVOICE

43512

DATE

3/27/23





PATIENT

Lucy Trotter

SPECIES

Canine

BREED

Wire-haired
Dachshund

SEX

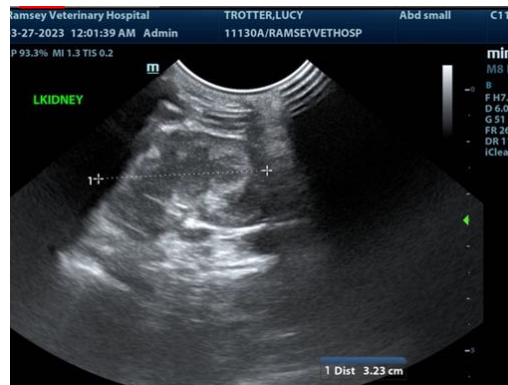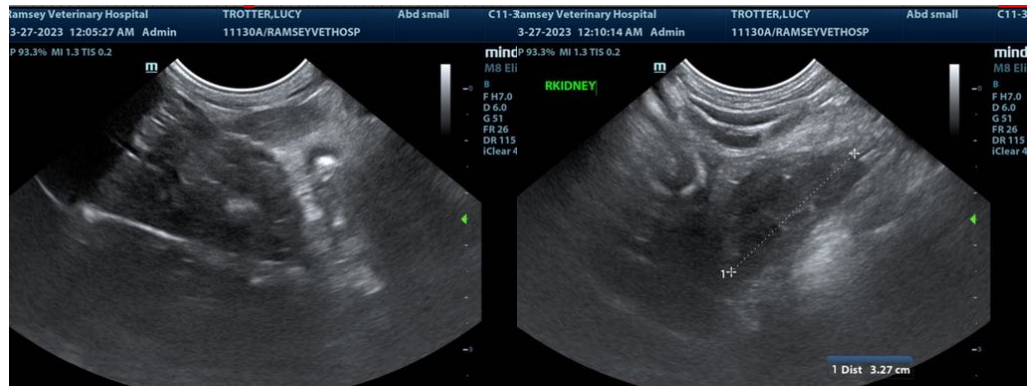
Spayed female

AGE

9 years

WEIGHT

5.4 lbs



INTERPRETED BY

Eric Lindquist, DMV
DABVP, Cert. IVUSS

IMAGING PERFORMED BY

Dr. Striano Kaplan

HOSPITAL NAME

Ramsey VH

REFERRING VET

Dr. Striano Kaplan

INVOICE

43512

DATE

3/27/23

The information and recommendations provided are based on the images presented by the referring veterinarian/sonographer. No evaluation can be communicated regarding pathology that was not visible in the image/video clips provided.

Thank you for this referral. If the clinical or image interpretation does not parallel your findings or if I can be of any further assistance please contact me.

Eric Lindquist, DMV, DABVP, Cert. IVUSS, CEO of SonoPath.com
info@SonoPath.com