



**PATIENT**

Scooby Joy

**SPECIES**

Canine

**BREED**

German Shepherd

**SEX**

Male

**AGE**

8 Months

**WEIGHT**

54 pounds

**INTERPRETED BY**

Eric Lindquist, DMV,  
 DABVP(CFM), Cert.  
 IVUSS

**IMAGING PERFORMED BY**

Vincent Ravancho CVT

**HOSPITAL NAME**

St. Georges Veterinary  
 Hospital

**REFERRING VET**

Dr. Ng

**INVOICE**

14636

**DATE**

03/26/26

**PRESENTING CLINICAL SIGNS**

- Bilateral Cryptorchid
- Assessing testicle placement for neuter
- Sedated with Torb and Dexmedetomidine

**ULTRASONOGRAPHIC EXAMINATION OF THE ABDOMEN**

**Urinary System**

The **urinary bladder**, trigone, and pelvic urethra presented normal thicknesses and normal tone. The ureters were not visible which is normal. No uroliths or sediment were visualized, and anechoic urine was present. No evidence of inflammatory or neoplastic changes were noted. Ureteral papillae were normal.

The **prostate** was uniform measuring 2.8 cm. A retained testicle was noted at the level of the cystourethral junction measuring 2.5 cm and suspected to the left testicle. A second cryptorchid was noted adjacent to the mid caudal bladder on the right side measuring 2.6 cm.

The **kidneys** revealed normal size and structure, corticomedullary definition and ratio for this age. The cortices presented largely uniform texture with normal echogenic relationship to liver and spleen. Medullary structure differed distinctly from the cortex and no evidence of pelvic dilation was present. The capsules were acceptably uniform without significant irregularities. The left kidney measured 8.33 cm in length. The right kidney measured 7.8 cm in length.

**Adrenal Glands**

Both **adrenal glands** were visualized and recognized as having normal shape, size, position and echogenicity for this breed. The phrenic vasculature, glandular echogenicity and detail were unremarkable. Capsule, cortex, and medullary definition were normal for this age patient. The left adrenal gland measured 2.32 cm x 0.74 cm width at the caudal pole and 0.67 cm width at the cranial pole. The right adrenal gland measured 2.26 cm x 0.80 cm width at the cranial pole and 0.47 cm width at the caudal pole.

**Spleen**

The **spleen** presented a smooth homogeneous parenchyma hyperechoic to liver and renal cortical parenchyma. The capsule was smooth without noticeable expansion or deviation from within the spleen or adjacent pathology. The splenic vasculature demonstrated normal volume without signs of congestion or thrombosis. No sonographic evidence of acute or chronic inflammatory, neoplastic, or infarctual changes were noted.

**Liver**

The **liver** images submitted revealed subjectively normal liver size, contour, and structure. Parenchymal echogenicity was naturally coarse and hypoechoic to the spleen. Vascular and biliary tracts were of normal volume with no evidence of congestion. The gallbladder presented acceptably thin walls with primarily anechoic content. The cystic and common bile ducts were normal. No pathological hepatic lymphadenopathy was evident. No overt structural evidence of inflammatory, infiltrative or regenerative pathology was evident.



**PATIENT**

Scooby Joy

**SPECIES**

Canine

**BREED**

German Shepherd

**SEX**

Male

**AGE**

8 Months

**WEIGHT**

54 pounds

**INTERPRETED BY**

Eric Lindquist, DMV,  
DABVP(CFM), Cert.  
IVUSS

**IMAGING  
PERFORMED BY**

Vincent Ravancho CVT

**HOSPITAL NAME**

St. Georges Veterinary  
Hospital

**REFERRING VET**

Dr. Ng

**INVOICE**

14636

**DATE**

03/26/26

***Gastrointestinal***

Examination of the **gastrointestinal tract** revealed a stomach and intestine free of stasis, of normal wall thickness, acceptable curvilinear mural detail, and peristaltic activity. Small and large intestine demonstrated normal luminal chyme and hard stool consistency respectively. No obstructive or overt infiltrative disease was noted. No associated abnormal lymphatic activity was noted.

***Pancreas***

The base and limbs of the **pancreas** were observed to be largely isoechoic to surrounding omental fat. Pancreatic duct and capsular contour were acceptably normal and parenchyma respected normal curvilinear patterns. No overt evidence of active inflammatory or neoplastic disease was noted.

***Free Abdomen***

Mesenteric **lymph nodes** were identified measuring up to 1.9 cm.

**ULTRASONOGRAPHIC FINDINGS**

- Bilateral cryptorchid with minor regional reactive mesenteric lymph nodes.

**INTERPRETATION OF THE FINDINGS & FURTHER RECOMMENDATIONS**

Abdominal exploratory orchiectomy is necessary.



**PATIENT**

Scooby Joy

**SPECIES**

Canine

**BREED**

German Shepherd

**SEX**

Male

**AGE**

8 Months

**WEIGHT**

54 pounds

**INTERPRETED BY**

Eric Lindquist, DMV,  
 DABVP(CFM), Cert.  
 IUUSS

**IMAGING PERFORMED BY**

Vincent Ravancho CVT

**HOSPITAL NAME**

St. Georges Veterinary  
 Hospital

**REFERRING VET**

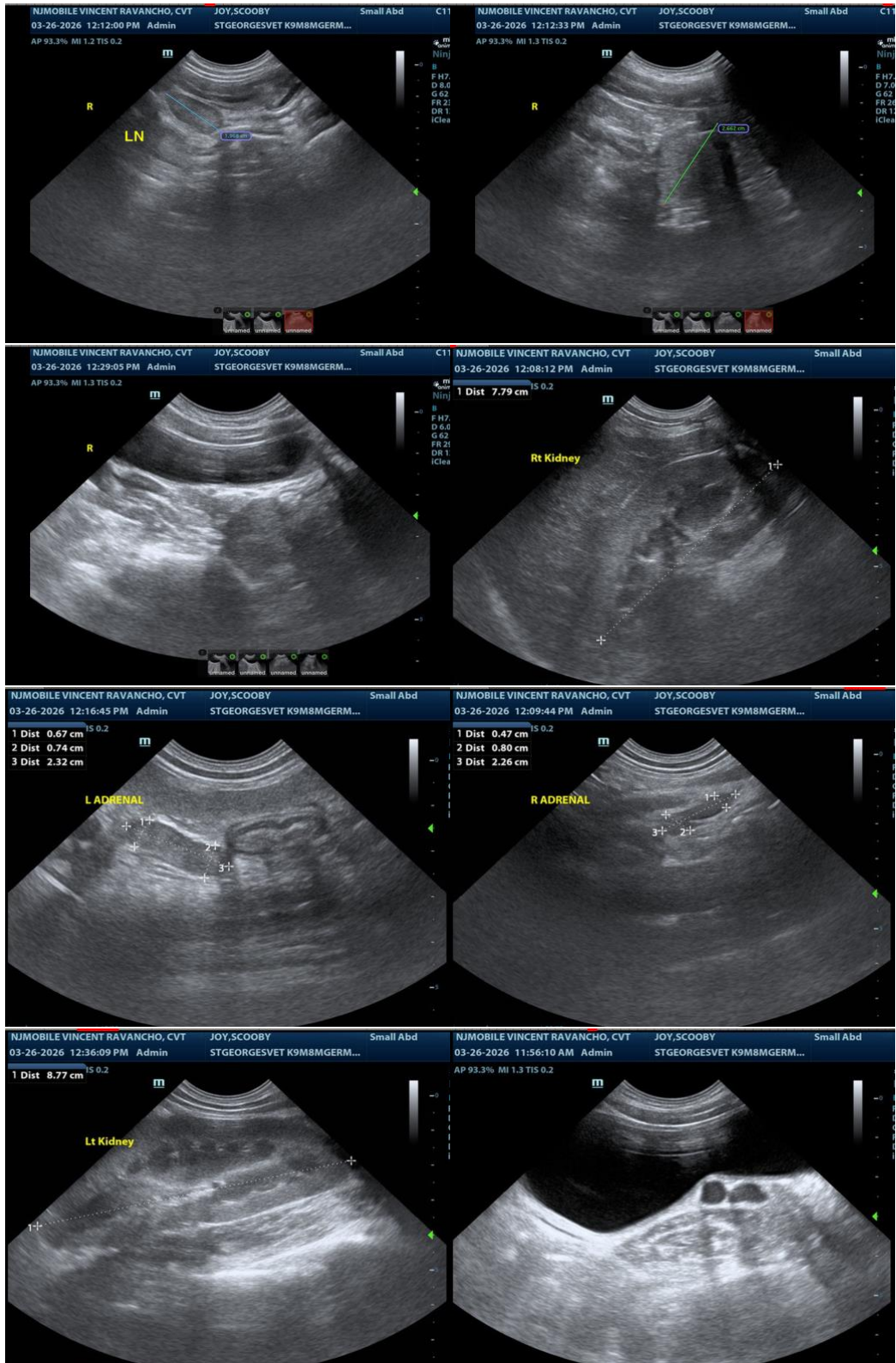
Dr. Ng

**INVOICE**

14636

**DATE**

03/26/26





**PATIENT**

Scooby Joy

**SPECIES**

Canine

**BREED**

German Shepherd

**SEX**

Male

**AGE**

8 Months

**WEIGHT**

54 pounds

**INTERPRETED BY**

Eric Lindquist, DMV,  
 DABVP(CFM), Cert. IVUSS

**IMAGING PERFORMED BY**

Vincent Ravancho CVT

**HOSPITAL NAME**

St. Georges Veterinary  
 Hospital

**REFERRING VET**

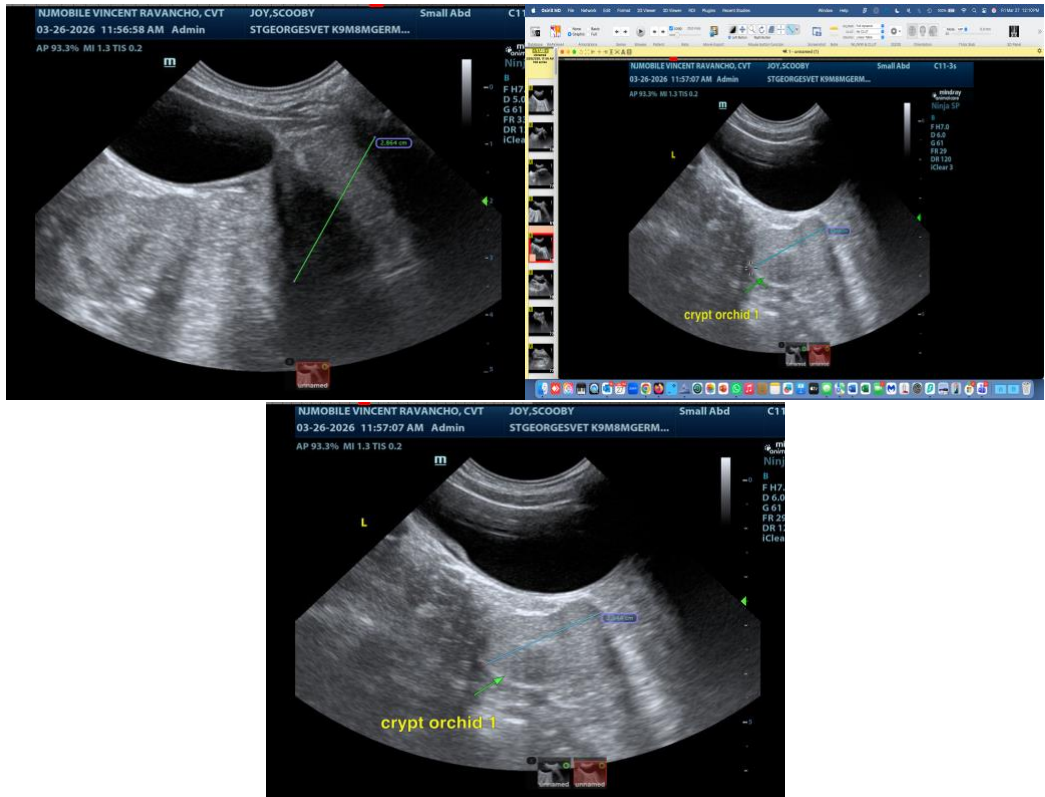
Dr. Ng

**INVOICE**

14636

**DATE**

03/26/26



The information and recommendations provided are based on the images presented by the referring veterinarian/sonographer. No evaluation can be communicated regarding pathology that was not visible in the image/video clips provided.

Thank you for this referral. If the clinical or image interpretation does not parallel your findings or if I can be of any further assistance, please contact me.

**Eric Lindquist, DMV, DABVP(CFM), Cert. IVUSS,**

CEO, Owner, Founder -- SonoPath.com

[info@SonoPath.com](mailto:info@SonoPath.com)