



PATIENT

Renata Montoya

SPECIES

Canine

BREED

Dachshund

SEX

Spayed female

AGE

13 years

WEIGHT

22.6 lbs

INTERPRETED BY

Eric Lindquist, DMV
DABVP, Cert. IVUSS

IMAGING PERFORMED BY

Dr. Salas

HOSPITAL NAME

Tenafly VC

REFERRING VET

Dr. Salas

INVOICE

73816

DATE

3/26/26

PRESENTING CLINICAL SIGNS

- Pet is 13 yr old Dachshund 22lb FS. overweight. History of elevated liver enzymes. Gall bladder emerging mucocele diagnosed 2 yrs ago. hx of pancreatitis. has been doing well. is also an epileptic and is on phenobarb and keppra. presented today- had a seizure. had v/d with blood in both. getting better without any intervention. we pulled bloods Vetsc/CBC/PLI/fecal and we performed a f/up liver/gb ultrasound to evaluate liver/gb/pancreas. pet was not sedated and did not seem overly painful in the Right caudal quadrant.

ULTRASONOGRAPHIC EXAMINATION

Liver

The **liver** revealed coarse architecture with heterogenous parenchymal changes. The liver was uniformly enlarged. Minor coalesced gallbladder debris and striating bile was noted.

ULTRASONOGRAPHIC FINDINGS

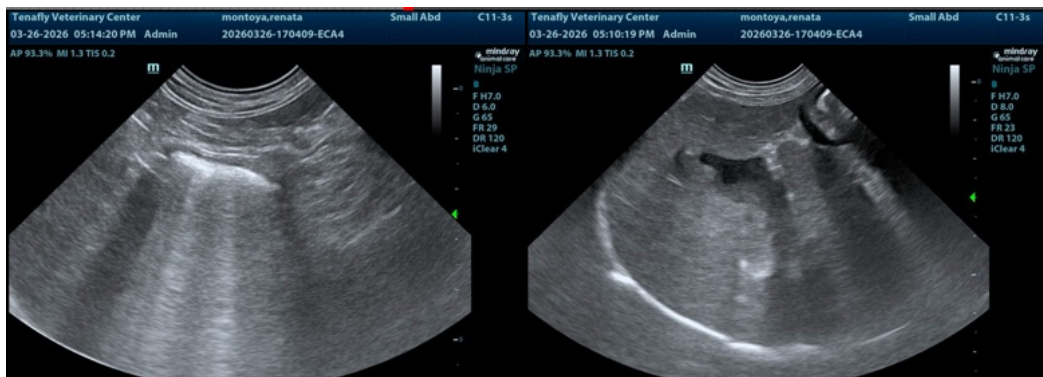
Chronic inflammatory hepatopathy.

Hepatic remodeling.

Minor excessive gallbladder debris

INTERPRETATION OF THE FINDINGS & FURTHER RECOMMENDATIONS

The gallbladder is not to the level of mucocele formation. However, Ursodiol therapy can be considered. FNA of the liver could be considered. Ursodiol should be continued if already being utilized. Bile acid profile is indicated. Nutraceuticals are indicated.





PATIENT

Renata Montoya

SPECIES

Canine

BREED

Dachshund

SEX

Spayed female

AGE

13 years

WEIGHT

22.6 lbs

INTERPRETED BY

Eric Lindquist, DMV
DABVP, Cert. IVUSS

IMAGING PERFORMED BY

Dr. Salas

HOSPITAL NAME

Tenafly VC

REFERRING VET

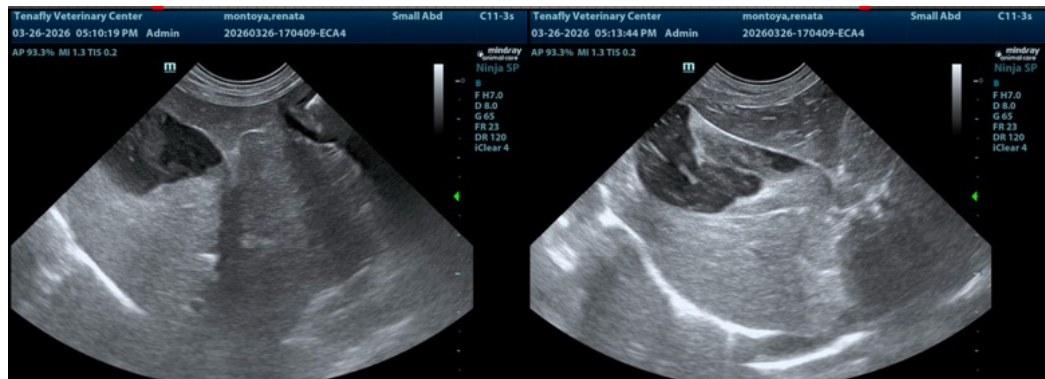
Dr. Salas

INVOICE

73816

DATE

3/26/26



The information and recommendations provided are based on the images presented by the referring veterinarian/sonographer. No evaluation can be communicated regarding pathology that was not visible in the image/video clips provided.

Thank you for this referral. If the clinical or image interpretation does not parallel your findings or if I can be of any further assistance please contact me.

Eric Lindquist, DMV, DABVP (CFM), Cert. IVUSS, CEO of SonoPath.com

info@SonoPath.com