



PATIENT

Mr. Topaz Utech

SPECIES

Feline

BREED

DSH

SEX

Neutered Male

AGE

16 Years 10 Months

WEIGHT

9 pounds

INTERPRETED BY

Eric Lindquist, DMV,
DABVP(CFM), Cert.
IVUSS

IMAGING PERFORMED BY

Kerri Becker

HOSPITAL NAME

Marsh Hospital for
Animals

REFERRING VET

Dr. Armani

INVOICE

14633

DATE

03/26/26

PRESENTING CLINICAL SIGNS

- HX murmur grade 4, hypothyroid, septal hypertrophy

Abnormal PE/Chem/CBC/UA Results: alt-171

ULTRASONOGRAPHIC EXAMINATION OF THE ABDOMEN

Urinary System

The **urinary bladder**, trigone, and pelvic urethra presented normal thicknesses and normal tone. The ureters were not visible which is normal. No uroliths or sediment were visualized, and anechoic urine was present. No evidence of inflammatory or neoplastic changes were noted. Ureteral papillae were normal.

The **kidneys** revealed largely normal size and structure, corticomedullary definition and ratio (cortex 1/3 of medulla) were essentially maintained with some mild to moderate age-related loss of curvilinear patterns regarding the capsule and C/M junction. The cortices presented largely uniform texture with some increased echogenicity expected for his age patient. Medullary structure differed distinctly from that of the cortex and no evidence of pelvic dilation was present. The left kidney measured 3.3 cm in length. The right kidney measured 3.6 cm in length.

Adrenal Glands

Both **adrenal glands** were visualized and recognized as having normal shape, size, position and echogenicity for this breed. The phrenic vasculature, glandular echogenicity and detail were unremarkable. Capsule, cortex, and medullary definition were normal for this age patient. The left adrenal gland measured 0.45 cm width. The right adrenal gland measured 0.46 cm width.

Spleen

The **spleen** presented a smooth homogeneous parenchyma hyperechoic to liver and renal cortical parenchyma. The capsule was smooth without noticeable expansion or deviation from within the spleen or adjacent pathology. The splenic vasculature demonstrated normal volume without signs of congestion or thrombosis. No sonographic evidence of acute or chronic inflammatory, neoplastic, or infarctual changes were noted.

Liver

The **liver** revealed a cystadenomatous lesion in the left medial liver measuring 2.2 cm. No significant progress from the prior sonogram. The remainder of the liver revealed uniform parenchyma. The gallbladder and common bile duct were unremarkable.

Gastrointestinal

The **gastrointestinal tract** revealed minor variable thickening and echogenic submucosal changes most consistent with low grade end result of chronic GI disease such as IBD and may be related to malassimilation of nutrients if any weight loss is present. No obvious neoplastic patterns were noted and luminal content as unremarkable. Some spastic bowel was noted.

Pancreas



PATIENT

Mr. Topaz Utech

SPECIES

Feline

BREED

DSH

SEX

Neutered Male

AGE

16 Years 10 Months

WEIGHT

9 pounds

INTERPRETED BY

Eric Lindquist, DMV,
 DABVP(CFM), Cert.
 IVUSS

IMAGING PERFORMED BY

Kerri Becker

HOSPITAL NAME

Marsh Hospital for
 Animals

REFERRING VET

Dr. Armani

INVOICE

14633

DATE

03/26/26

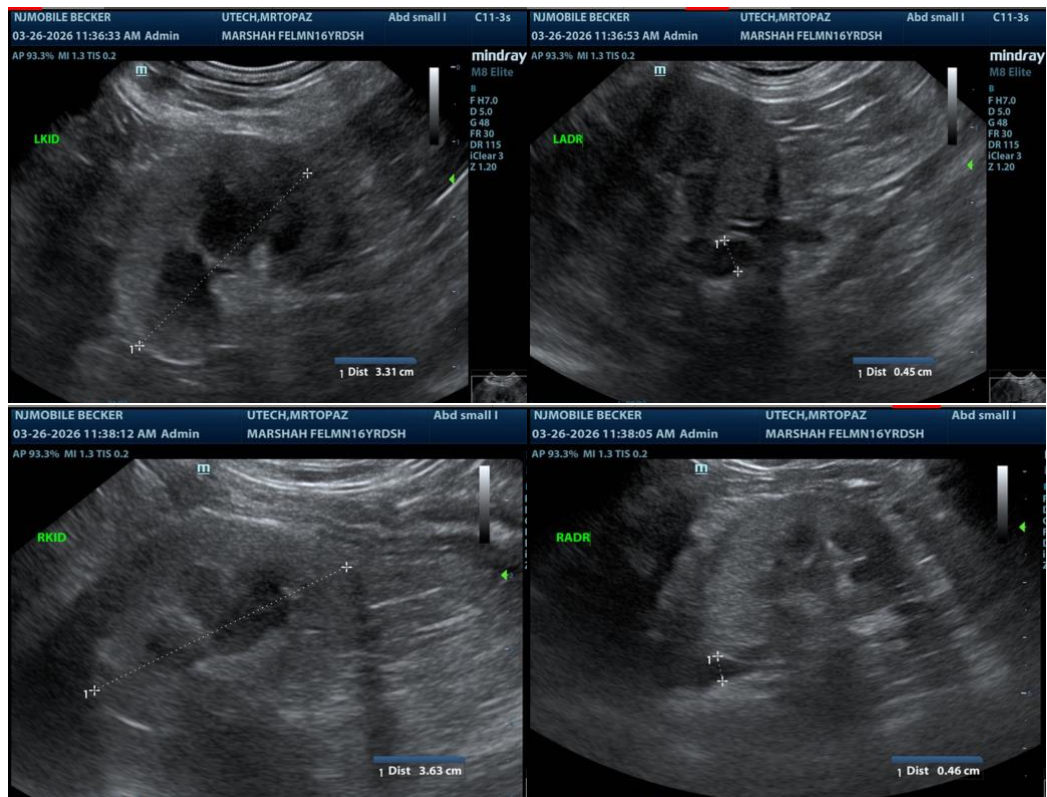
The base and limbs of the **pancreas** were observed to be largely isoechoic to surrounding omental fat. Some mild parenchymal remodeling, however, with mild deviation from curvilinear normalcy was observed. Pancreatic duct and capsular irregularities were present consistent with age related changes. If pain upon imaging (+ Murphy sign) was present or if the patient is focally painful in subxiphoid palpation then low-grade smoldering chronic pancreatitis should be suspected. No evidence of active inflammation.

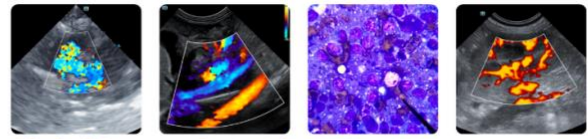
ULTRASONOGRAPHIC FINDINGS

- Minor chronic intestinal thickening- chronic inflammatory bowel presentation. NO neoplastic criteria or foreign bodies.
- Geriatric abdomen.

INTERPRETATION OF THE FINDINGS & FURTHER RECOMMENDATIONS

Abdomen appears geriatric and stable.





PATIENT

Mr. Topaz Utech

SPECIES

Feline

BREED

DSH

SEX

Neutered Male

AGE

16 Years 10 Months

WEIGHT

9 pounds

INTERPRETED BY

Eric Lindquist, DMV,
 DABVP(CFM), Cert.
 IVUSS

IMAGING PERFORMED BY

Kerri Becker

HOSPITAL NAME

Marsh Hospital for
 Animals

REFERRING VET

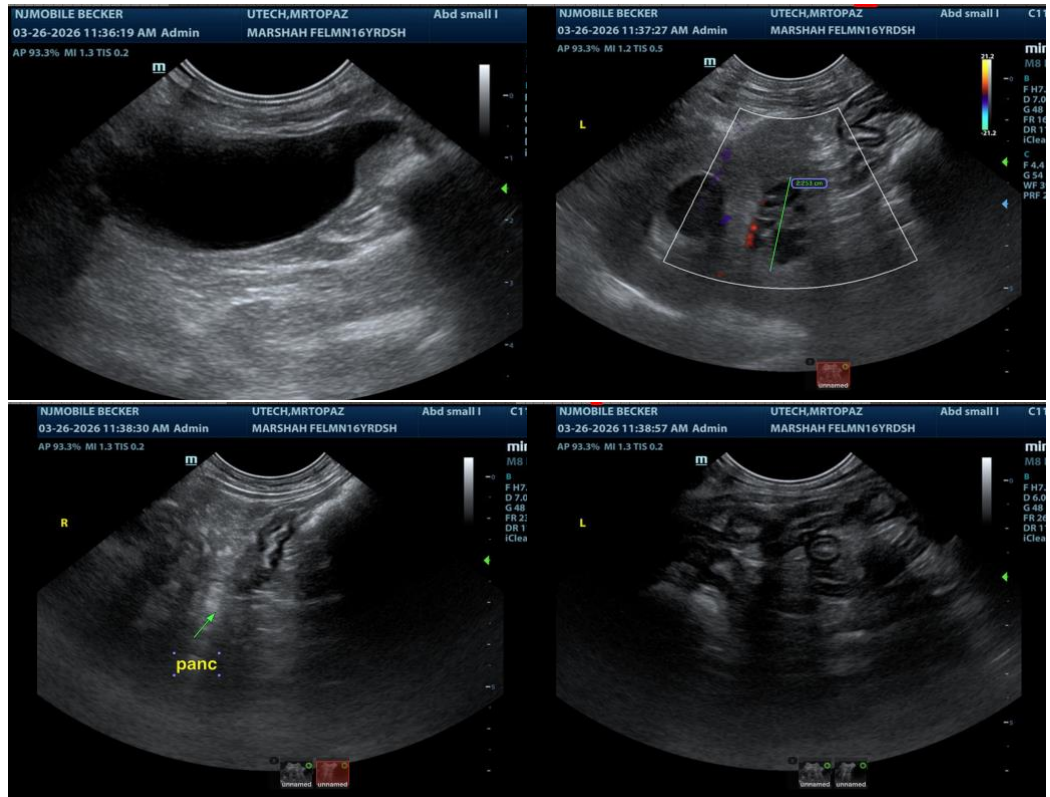
Dr. Armani

INVOICE

14633

DATE

03/26/26



The information and recommendations provided are based on the images presented by the referring veterinarian/sonographer. No evaluation can be communicated regarding pathology that was not visible in the image/video clips provided.

Thank you for this referral. If the clinical or image interpretation does not parallel your findings or if I can be of any further assistance, please contact me.

Eric Lindquist, DMV, DABVP(CFM), Cert. IVUSS,

CEO, Owner, Founder -- SonoPath.com

info@SonoPath.com