

**PATIENT PRESENTING CLINICAL SIGNS**

Pippi Biss T 100, HR 110, RR 30, BCS 3/5, PS 0/4, FAS green.  
Diabetic

**SPECIES**

Canine

**BREED**

Miniature Schnauzer

**SEX**

Spayed Female

**AGE**

9 years

**WEIGHT**

19.2 lbs

**INTERPRETED BY**

Eric Lindquist, DMV  
DABVP, Cert. IVUSS

**HOSPITAL NAME**

SDEP Lab

**INVOICE**

97838

**DATE**

3/26/22

**ULTRASONOGRAPHIC EXAMINATION OF THE ABDOMEN**  
*Urinary System*

The **urinary bladder** presented a relatively uniform thickening of the cranioventral and craniodorsal mucosae with micropolypoid mucosal changes without involvement of the submucosae. The urine presented some echogenicity consistent with suspended debris. No evidence of urethral pathology was present. This presentation is most consistent with chronic cystitis. Technically transitional cell carcinoma cannot be ruled out without histopathological review but is not overtly suspected based on this pattern. Cystocentesis and urine culture +/- pathological review of urine cytology would be warranted. No overt calculi were present at this time.

The **kidneys** revealed largely normal size and structure, corticomedullary definition and ratio (cortex 1/3 of medulla) were essentially maintained with some age-related loss of curvilinear patterns regarding the capsule and C/M junction. Pinpoint medullary changes were noted. The cortices presented largely uniform texture with some increased echogenicity expected for this age patient. Medullary structure differed distinctly from that of the cortex and no evidence of pelvic dilation was present.

*Adrenal Glands*

Both **adrenal glands** were visualized and recognized as having normal shape, size, position and echogenicity for this breed. The phrenic vasculature, glandular echogenicity and detail were unremarkable. Capsule, cortex, and medullary definition were normal for this age patient.

*Spleen*

The **spleen** presented a smooth homogeneous parenchyma hyperechoic to liver and renal cortical parenchyma. The capsule was smooth without noticeable expansion or deviation from within the spleen or adjacent pathology. The splenic vasculature demonstrated normal volume without signs of congestion or thrombosis. No sonographic evidence of acute or chronic inflammatory, neoplastic, or infarctual changes was noted.

*Liver*

The **liver** images submitted revealed subjectively normal liver size, contour, and structure. Parenchymal echogenicity was naturally coarse and hypoechoic to the spleen. Vascular and biliary tracts were of normal volume with no evidence of congestion. The gallbladder presented acceptably thin walls with primarily anechoic content. The cystic and common bile ducts were normal. No pathological hepatic lymphadenopathy was evident. No overt structural evidence of inflammatory, infiltrative or regenerative pathology was evident.



**PATIENT**

**Gastrointestinal**

Pippi Biss

Examination of the **gastrointestinal tract** revealed a stomach and intestine free of stasis, of normal wall thickness, acceptable curvilinear mural detail, and peristaltic activity. Small and large intestine demonstrated normal luminal chyme and stool consistency respectively. No obstructive or overt infiltrative disease was noted. No associated abnormal lymphatic activity was noted.

**SPECIES**

Canine

**BREED**

Miniature Schnauzer

**Pancreas**

The base and limbs of the **pancreas** were observed to be largely isoechoic to surrounding omental fat. Some parenchymal remodeling, however, with mild deviation from curvilinear normalcy was observed. Pancreatic duct and capsular irregularities were present consistent with age related changes. If pain upon imaging (+ Murphy sign) was present or if the patient is focally painful in subxiphoid palpation then low-grade smoldering chronic pancreatitis should be suspected.

**SEX**

Spayed Female

**AGE**

9 years

**ULTRASONOGRAPHIC EXAMINATION OF THE HEART**

The echocardiogram in this patient demonstrated normal **left atrial** size based on 3 different LA measurement methods. Chamber volumes and echogenicity were normal. The cranial and caudal **mitral** valve leaflets presented vegetative thickening consistent with endocardiosis. Doppler indicated measurable insufficiency. The **left ventricle** presented thicknesses with linear contour and was not dilated nor restricted. The **myocardium** presented normal echogenicity without subjective evidence of significant fibrotic or ischemic disease. **Contractility** of the ventricular walls was adequate and in normal range for this patient evidenced by the fractional shortening measurement and subjective evaluation of the different regions of the myocardium. The **left ventricular outflow** tract demonstrated normal laminar flow and subjective structural integrity. The **right atrium** and auricle revealed normal size, structure and content. No evidence of masses was noted or chamber overload. **Tricuspid** valvular assessment demonstrated adequate linear morphology. The **right ventricle** was of normal size (1/3 diameter of LV), chordae structure, myocardial echogenicity and thickness. **Pulmonic** tract assessment revealed normal valve structure, laminar flow, and diameter (approx. 1:1 pa/ao ratio). No visible **pericardial** or free pleura fluid was noted. No echographically detectable evidence of infiltrative disease was visible. The cranial **mediastinum** and **pericardial regions** were free of masses in the visible window.

**WEIGHT**

19.2 lbs

**INTERPRETED BY**

Eric Lindquist, DMV  
DABVP, Cert. IVUSS

**HOSPITAL NAME**

SDEP Lab

**INVOICE**

97838

**ULTRASONOGRAPHIC FINDINGS**

Mild cystitis bladder pattern.

Pancreatic remodeling.

**DATE**

3/26/22

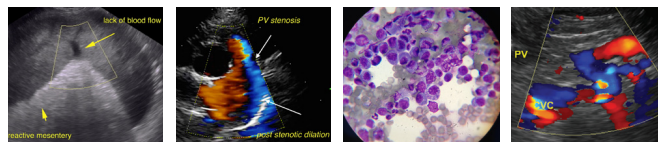
Hepatomegaly.

Age related renal changes with pinpoint medullary changes

Mitral valve disease, compensated.

**INTERPRETATION OF THE FINDINGS & FURTHER RECOMMENDATIONS**

Urine culture and sensitivity is recommended in this patient.



**PATIENT**

Pippi Biss

The information and recommendations provided are based on the images presented by the referring veterinarian/sonographer. No evaluation can be communicated regarding pathology that was not visible in the image/video clips provided.

**SPECIES**

Canine

Thank you for this referral. If the clinical or image interpretation does not parallel your findings or if I can be of any further assistance please contact me.

**BREED**

Miniature Schnauzer

**Eric Lindquist**, DMV, DABVP, Cert. IVUSS, CEO of SonoPath.com  
Eric.Lindquist@SonoPath.com

**SEX**

Spayed Female

**AGE**

9 years

**WEIGHT**

19.2 lbs

**INTERPRETED BY**

Eric Lindquist, DMV  
DABVP, Cert. IVUSS

**HOSPITAL NAME**

SDEP Lab

**INVOICE**

97838

**DATE**

3/26/22