SonoPath
Clinical Sonography & Telecytology

EDUCATIONAL TELECONSULTATION SERVICES™

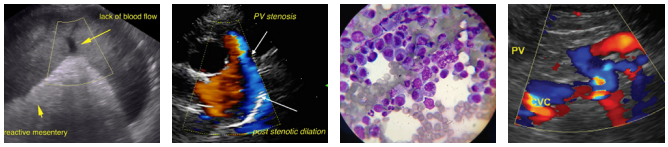

SonoPath.com™
1-800-838-4268 info@sonopath.com

PATIENT
Ida Wenisch

SPECIES
Ferret

BREED
Ferret

SEX
Female

AGE
3 Years 6 Months

WEIGHT
0.62 kg

INTERPRETED BY
Eric Lindquist, DMV
DABVP, Cert. IVUSS

IMAGING PERFORMED BY
Dr. Jessie Evoniuk

HOSPITAL NAME
State Ave Vet

REFERRING VET
Dr. Jessie Evoniuk

INVOICE
36488

DATE
3/26/22

PRESENTING CLINICAL SIGNS

Subjective O called on emergency earlier today concerned Ida had vomited a large amount of fluid and seemed off. Video sent and showed some shaking, squinting of the eyes, and very willing to drink water. Had been seemingly normal prior but Os have noted weight loss since last visit. All other ferrets are doing well. No known toxins. No known FB ingestion. In a safe ferret area. Called again later that afternoon and no improvement so seeking care. Objective Alert, mobile and inquisitive during exam but had not been like that at home. E/E clear. Teeth G2 tarter mm <3s. injected. H/L WNL. BCS 3-4/9. Abd-soft, not painful, able to palpate kidneys well. No overt pain. 1 unit Butorphanol given IM to facilitate handling and venipuncture Urine SpG 1.042 (voided during handling) CBC neutrophils 7.1, HCT 57.46 Chem Glc 147, Na 151 (1420-148), K+ 4.1 (4.5-6.1), TP 7.1 (4.5-6.2), Glob 2.5, Phos 3.6 (5.10-6.5), Ca 9.9 (8.1-9.5), Alb 4.6 (2.5-4) Assessment V+- RO FB, mass/neoplasia, lymphoma, infectious gastritis/gastroenteritis, open Weight loss of 0.3 pounds over the month Elevated HCT, alb, TP, Na- RO dehydration Hypercalcemia/hypophosphatemia- open Plan Recommend imaging to better assess GIT and RO FB, other cause of vomiting and weight loss. Fluid filled stomach and upper GI with associated lymphadenopathy. DIsc findings with Megan and plan to start supportive care including hydration, Carnivore Critical care, Cerenia, Metronidazole pending full review of US imaging. Single R lateral rad taken to confirm fluid/gas in upper GIT but no overt solid FB structure noted.

ULTRASONOGRAPHIC EXAMINATION OF THE ABDOMEN

Urinary System

The **urinary bladder**, trigone, and pelvic urethra presented normal thicknesses and normal tone. The ureters were not visible which is normal. No uroliths or sediment were visualized and anechoic urine was present. No evidence of inflammatory or neoplastic changes were noted. Ureteral papillae were normal.

The **kidneys** revealed normal size and structure, corticomedullary definition and ratio for this age. The cortices presented largely uniform texture with normal echogenic relationship to liver and spleen. Medullary structure differed distinctly from the cortex and no evidence of pelvic dilation was present. The capsules were acceptably uniform without significant irregularities. The left kidney measured 2.0 cm. An anechoic cyst was noted in the right kidney measured 5.0 mm.

Adrenal Glands

Both **adrenal glands** were visualized and recognized as having normal shape, size, position and echogenicity for this breed. The phrenic vasculature, glandular echogenicity and detail were unremarkable. Capsule, cortex, and medullary definition were normal for this age patient. The left adrenal gland measured 0.30 cm. The right adrenal gland measured 0.30 cm.

Spleen

The **spleen** presented a smooth homogeneous parenchyma hyperechoic to liver and renal cortical parenchyma. The capsule was smooth without noticeable expansion or deviation from within the spleen or adjacent pathology. The splenic vasculature demonstrated normal volume without signs of congestion or thrombosis. No sonographic evidence of acute or chronic inflammatory, neoplastic, or infarctual changes were noted.

Liver

The **liver** images submitted revealed subjectively normal liver size, contour, and structure. Parenchymal echogenicity was naturally coarse and hypoechoic to the spleen. Vascular and biliary tracts were of normal volume with no evidence of congestion. The gallbladder presented acceptably thin walls with primarily anechoic content. The cystic and common bile ducts were normal. No pathological hepatic

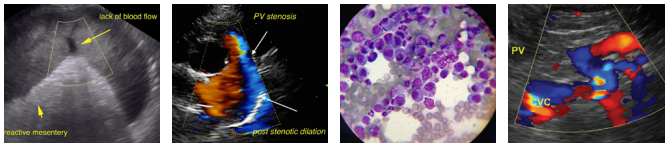

SonoPath.com™
1-800-838-4268 info@sonopath.com

PATIENT

Ida Wenisch

SPECIES

Ferret

BREED

Ferret

SEX

Female

AGE

3 Years 6 Months

WEIGHT

0.62 kg

INTERPRETED BY

Eric Lindquist, DMV

DABVP, Cert. IVUSS

IMAGING PERFORMED BY

Dr. Jessie Evoniuk

HOSPITAL NAME

State Ave Vet

REFERRING VET

Dr. Jessie Evoniuk

INVOICE

36488

DATE

3/26/22

lymphadenopathy was evident. No overt structural evidence of inflammatory, infiltrative or regenerative pathology was evident.

Gastrointestinal

Some **gastric** stasis was noted with echogenic chyme. The pylorus was patent, no evidence of obstruction. The small intestine was empty. The colon was filled with fluid and some echogenic material. Passing hairball or similar possible. Reactive mesenteric lymph nodes noted up to 1.0 cm x 0.5 cm.

Pancreas

The base and limbs of the **pancreas** were observed to be largely isoechoic to surrounding omental fat. Pancreatic duct and capsular contour were acceptably normal and parenchyma respected normal curvilinear patterns. No overt evidence of active inflammatory or neoplastic disease was noted.

ULTRASONOGRAPHIC FINDINGS

- Gastroenteritis pattern – no overt evidence of obstruction.
- Minor right renal cyst

INTERPRETATION OF THE FINDINGS & FURTHER RECOMMENDATIONS

Fluid support and fecal test recommended. Recheck sonogram in 24-48 hours if clinical signs are not improving. Dietary indiscretion, dietary intolerance, enterotoxins, parasites, and viral disease all possible.

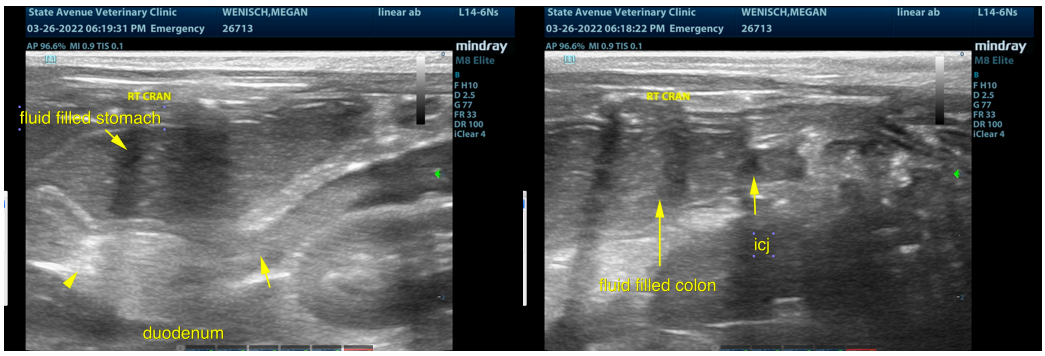

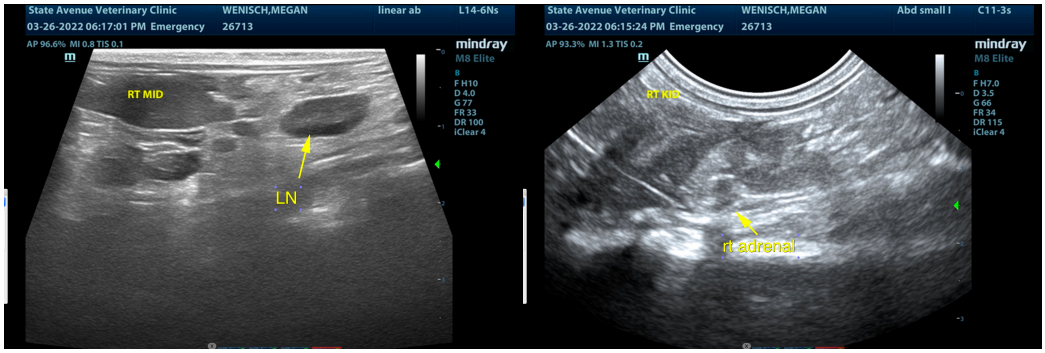

SonoPath
Clinical Sonography & Telecytology

EDUCATIONAL TELECONSULTATION SERVICES™

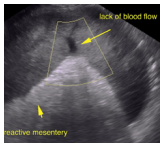

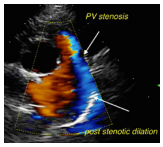

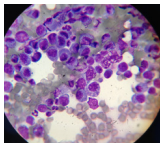
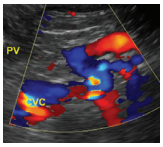

SonoPath.com™
1-800-838-4268 info@sonopath.com

PATIENT

Ida Wenisch

SPECIES

Ferret

BREED

Ferret

SEX

Female

AGE

3 Years 6 Months

WEIGHT

0.62 kg

INTERPRETED BY

Eric Lindquist, DMV

DABVP, Cert. IVUSS

IMAGING PERFORMED BY

Dr. Jessie Evoniuk

HOSPITAL NAME

State Ave Vet

REFERRING VET

Dr. Jessie Evoniuk

INVOICE

36488

DATE

3/26/22

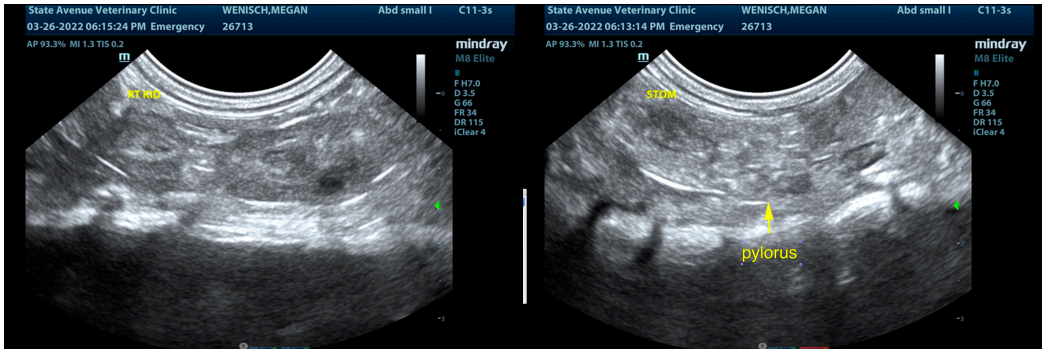

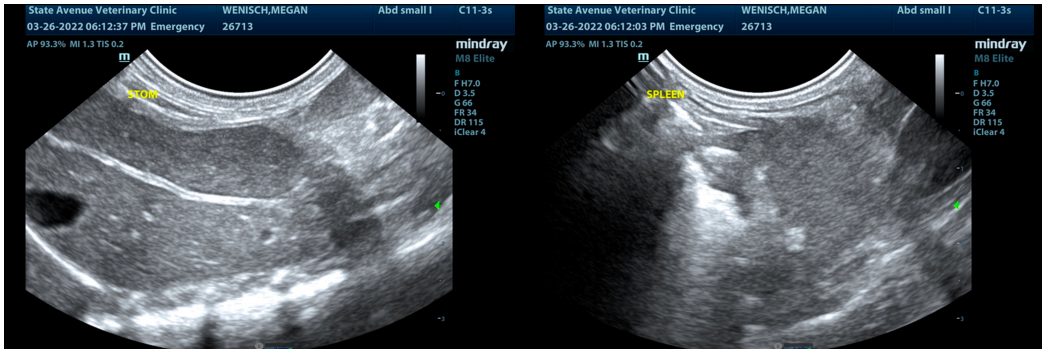

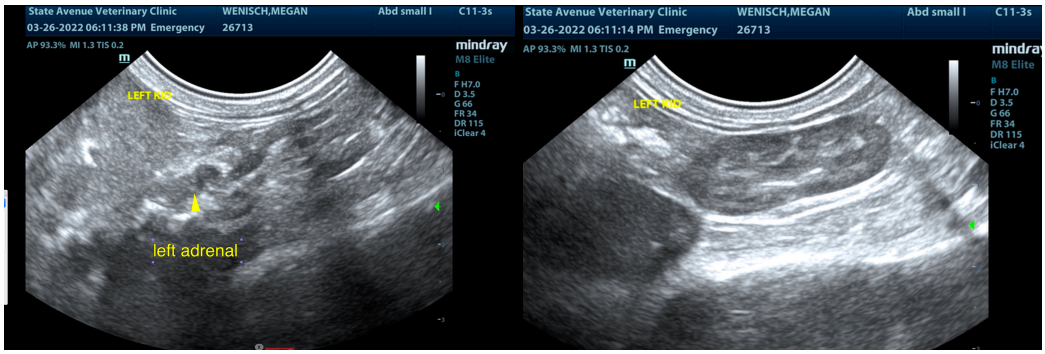

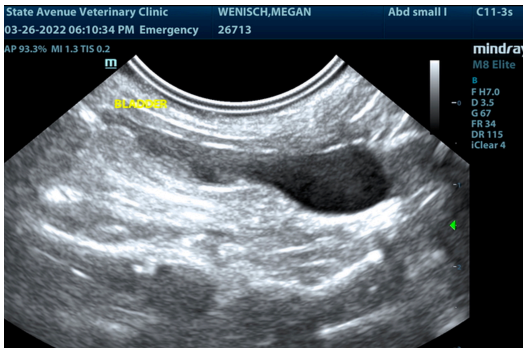

SonoPath
Clinical Sonography & Telecytology

EDUCATIONAL TELECONSULTATION SERVICES™

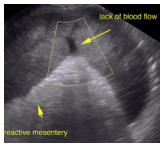

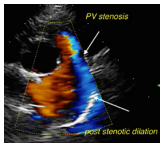

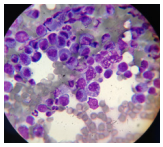
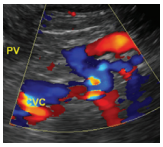

SonoPath.com™
1-800-838-4268 info@sonopath.com

PATIENT

Ida Wenisch

SPECIES

Ferret

BREED

Ferret

SEX

Female

AGE

3 Years 6 Months

WEIGHT

0.62 kg

INTERPRETED BY

Eric Lindquist, DMV

DABVP, Cert. IVUSS

IMAGING PERFORMED BY

Dr. Jessie Evoniuk

HOSPITAL NAME

State Ave Vet

REFERRING VET

Dr. Jessie Evoniuk

INVOICE

36488

DATE

3/26/22

The information and recommendations provided are based on the images presented by the referring veterinarian/sonographer. No evaluation can be communicated regarding pathology that was not visible in the image/video clips provided.

Thank you for this referral. If the clinical or image interpretation does not parallel your findings or if I can be of any further assistance please contact me.

Eric Lindquist, DMV, DABVP, Cert. IVUSS, CEO of SonoPath.com

info@SonoPath.com