SonoPath
Clinical Sonography & Telecytology

EDUCATIONAL TELECONSULTATION SERVICES™

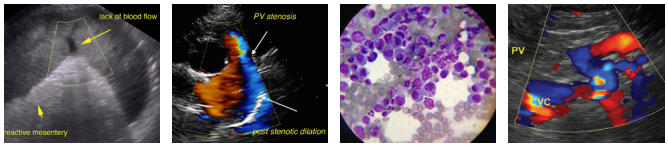

SonoPath.com™
1-800-838-4268 info@sonopath.com

PATIENT
Eli Stringham

SPECIES
Canine

BREED
Poodle X

SEX
Male

AGE
1 Year

WEIGHT
30 Pounds

INTERPRETED BY
Eric Lindquist, DMV
DABVP, Cert. IVUSS

IMAGING PERFORMED BY
Jenn

HOSPITAL NAME
Rockaway AH

REFERRING VET
Dr. Maniar

INVOICE
36486

DATE
3/26/22

PRESENTING CLINICAL SIGNS

had gastrotomy on Tues. now has stopped eating vomiting lethargic

ULTRASONOGRAPHIC EXAMINATION OF THE ABDOMEN

Urinary System

The **urinary bladder**, trigone, and pelvic urethra presented normal thicknesses and normal tone. The ureters were not visible which is normal. No uroliths or sediment were visualized and anechoic urine was present. No evidence of inflammatory or neoplastic changes were noted. Ureteral papillae were normal. The prostate was uniform at 1.5 cm.

The **kidneys** revealed normal size and structure, corticomedullary definition and ratio for this age. The cortices presented largely uniform texture with normal echogenic relationship to liver and spleen. Medullary structure differed distinctly from the cortex and no evidence of pelvic dilation was present. The capsules were acceptably uniform without significant irregularities. The right kidney measured 5.0 cm. The left kidney measured 5.5 cm.

Adrenal Glands

The **adrenal glands** were not visualized.

Spleen

The **spleen** presented a smooth homogeneous parenchyma hyperechoic to liver and renal cortical parenchyma. The capsule was smooth without noticeable expansion or deviation from within the spleen or adjacent pathology. The splenic vasculature demonstrated normal volume without signs of congestion or thrombosis. No sonographic evidence of acute or chronic inflammatory, neoplastic, or infarctual changes were noted.

Liver

The **liver** was largely normal. A trace amount of fluid was noted between the liver and the diaphragm. The gallbladder was unremarkable.

Gastrointestinal

The **stomach** was overdistended in this patient with a severe amount of fluid. The distal small intestine appeared unremarkable. No overt obstruction noted, yet could not be completely ruled out, as the pyloric outflow and upper duodenum was obscured by regional inflammation.

Pancreas

The region of the **pancreas** was nebulous with a 5.0 cm hypoechoic area that appeared to be occupying the right pancreatic base, suggestive for necrosis.

ULTRASONOGRAPHIC FINDINGS

- Gastric stasis
- Pancreatic necrosis/pancreatitis

INTERPRETATION OF THE FINDINGS & FURTHER RECOMMENDATIONS

Gastric tube placement to decompress the stomach would be warranted with IV fluid support, broad-spectrum antibiotics and treatment for pancreatitis recommended with recheck sonogram in 24-48 hours.

SonoPath

Clinical Sonography & Telecytology

EDUCATIONAL TELECONSULTATION SERVICES™

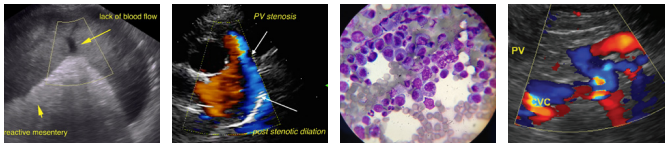

SonoPath.com™
1-800-838-4268 info@sonopath.com

PATIENT

Eli Stringham

SPECIES

Canine

BREED

Poodle X

SEX

Male

AGE

1 Year

WEIGHT

30 Pounds

INTERPRETED BY

Eric Lindquist, DMV

DABVP, Cert. IVUSS

IMAGING PERFORMED BY

Jenn

HOSPITAL NAME

Rockaway AH

REFERRING VET

Dr. Maniar

INVOICE

36486

DATE

3/26/22

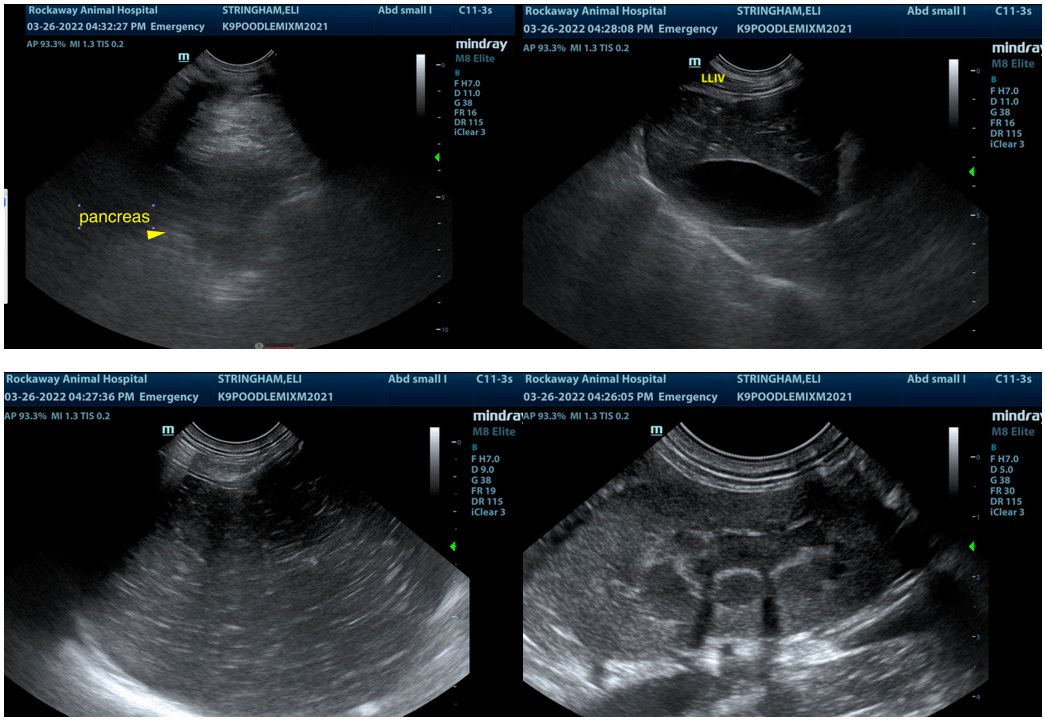

The information and recommendations provided are based on the images presented by the referring veterinarian/sonographer. No evaluation can be communicated regarding pathology that was not visible in the image/video clips provided.

Thank you for this referral. If the clinical or image interpretation does not parallel your findings or if I can be of any further assistance please contact me.

Eric Lindquist, DMV, DABVP, Cert. IVUSS, CEO of SonoPath.com

info@SonoPath.com