



PATIENT

Sadie Reini

SPECIES

Canine

BREED

Beagle

SEX

Spayed female

AGE

10 years

WEIGHT

37 lbs

INTERPRETED BY

Eric Lindquist, DMV
DABVP, Cert. IVUSS

IMAGING PERFORMED BY

Kathleen Byrnes

HOSPITAL NAME

Byrnes Veterinary
Relief Service

REFERRING VET

Dr. Lusk

INVOICE

73824

DATE

3/25/26

PRESENTING CLINICAL SIGNS

- P presented for thyroid US due to ventral cervical mass
- T4 previously 0.9, on thyroxine, T4 today wnl.
- FNA of R sided mass today- mostly rbc's rare cells

ULTRASONOGRAPHIC EXAMINATION OF THE THYROID

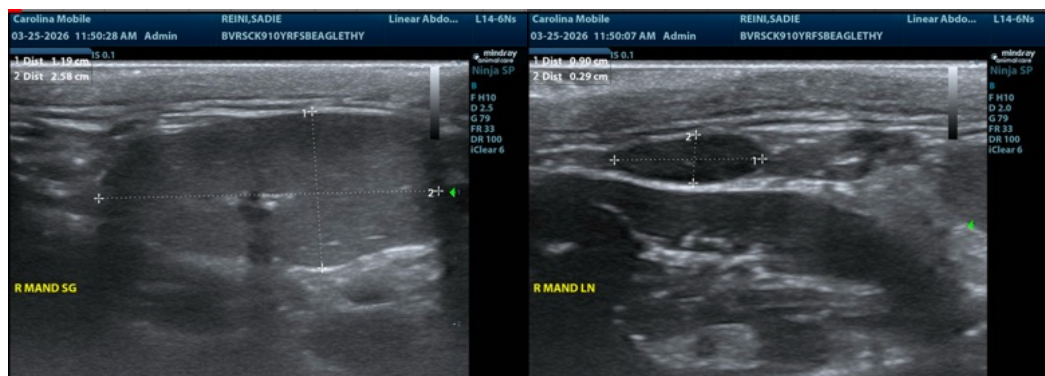
The left and right thyroid regions were imaged. The salivary glands, esophagus and trachea were unremarkable. However, the right thyroid region revealed an undifferentiated 2.6 cm mixed hypoechoic and mildly microcystic mass with areas of capsular expansion and regional escape. The regional lymph nodes were mildly enlarged and measured up to 1.0 x 0.3 cm. The visible parathyroids were unremarkable. Retropharyngeal and submandibular lymph nodes were enlarged. The largest lymph node measured 1.6 x 0.7 cm. Other recognizable portions of the thyroid were nodular. The left thyroid region revealed a hypervascular nodular change that measured up to 1.13 x 0.75 cm. This is suggestive for a crossover invasion of the right sided mass.

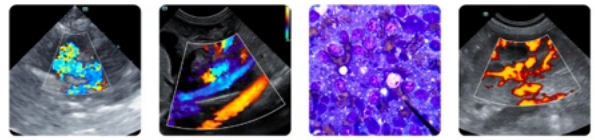
ULTRASONOGRAPHIC FINDINGS

Right thyroid mass with regional lymphadenopathy and capsular escape with extension to the left thyroid region.

INTERPRETATION OF THE FINDINGS & FURTHER RECOMMENDATIONS

I do not believe that a surgical option is present in this patient given the multi-focal lesions. However, FNA of the various lesions and right and left sided thyroid lobes can be considered. 25-gauge FNA is suggested. CT evaluation would be ideal for further definition as well as oncological consult. Thyroiditis is possible, yet less likely. Thyroid carcinoma is suspected.





PATIENT

Sadie Reini

SPECIES

Canine

BREED

Beagle

SEX

Spayed female

AGE

10 years

WEIGHT

37 lbs

INTERPRETED BY

Eric Lindquist, DMV
DABVP, Cert. IVUSS

IMAGING PERFORMED BY

Kathleen Byrnes

HOSPITAL NAME

Byrnes Veterinary
Relief Service

REFERRING VET

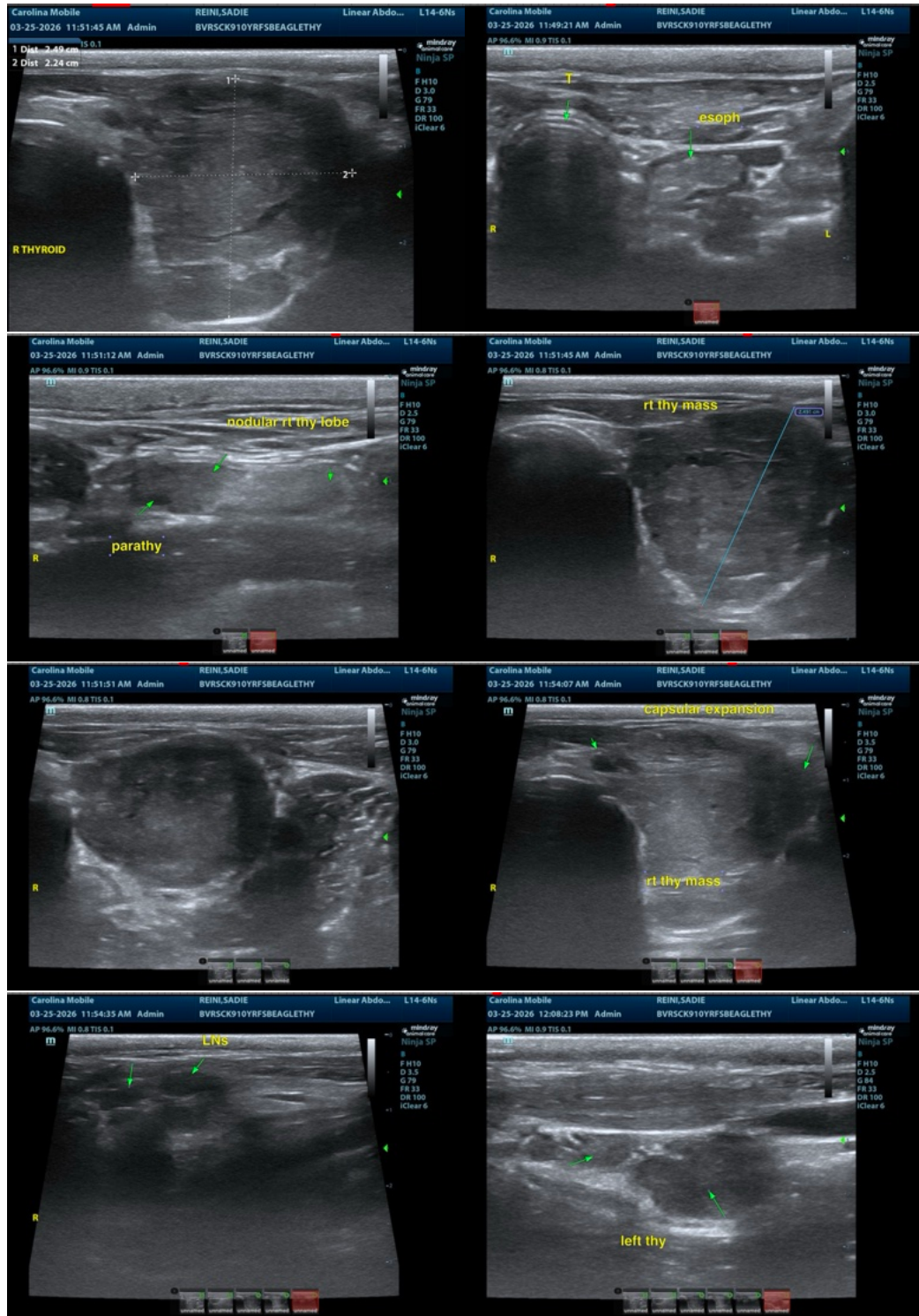
Dr. Lusk

INVOICE

73824

DATE

3/25/26





PATIENT

Sadie Reini

SPECIES

Canine

BREED

Beagle

SEX

Spayed female

AGE

10 years

WEIGHT

37 lbs

INTERPRETED BY

Eric Lindquist, DMV
DABVP, Cert. IVUSS

IMAGING PERFORMED BY

Kathleen Byrnes

HOSPITAL NAME

Byrnes Veterinary
Relief Service

REFERRING VET

Dr. Lusk

INVOICE

73824

DATE

3/25/26

The information and recommendations provided are based on the images presented by the referring veterinarian/sonographer. No evaluation can be communicated regarding pathology that was not visible in the image/video clips provided.

Thank you for this referral. If the clinical or image interpretation does not parallel your findings or if I can be of any further assistance please contact me.

Eric Lindquist, DMV, DABVP (CFM), Cert. IVUSS, CEO of SonoPath.com

info@SonoPath.com