**PATIENT**

Elsa Nordan

SPECIES

Canine

BREED

Rottweiler

SEX

Spayed Female

AGE

8 Years

WEIGHT

126 Pounds

INTERPRETED BYEric Lindquist, DMV
DABVP, Cert. IVUSS**IMAGING PERFORMED BY**

Sarah Pender, CVT

HOSPITAL NAME

SVS Imaging QC

REFERRING VET

Dr. Haenni

INVOICE

36461

DATE

3/25/22

PRESENTING CLINICAL SIGNS

Vomiting, profuse uncontrollable bloody diarrhea, lethargy Hx of GI issues but controlled with i/d until recently

Abnormal PE/Chem/CBC/UA Results: CBC unremarkable, phos 5.4, ALP 347

ULTRASONOGRAPHIC EXAMINATION OF THE ABDOMEN**Urinary System**

The **urinary bladder**, trigone, and pelvic urethra presented normal thicknesses and normal tone. The ureters were not visible which is normal. No uroliths or sediment were visualized and anechoic urine was present. No evidence of inflammatory or neoplastic changes were noted. Ureteral papillae were normal. The pelvic urethra was imaged 2.0 cm beyond the cystourethral junction.

The **kidneys** revealed normal size and structure, corticomedullary definition and ratio for this age. The cortices presented largely uniform texture with normal echogenic relationship to liver and spleen. Medullary structure differed distinctly from the cortex and no evidence of pelvic dilation was present. The capsules were acceptably uniform without significant irregularities. The right kidney measured 9.1 cm. The left kidney measured 9.04 cm.

Adrenal Glands

Both **adrenal glands** were visualized and recognized as having normal shape, size, position and echogenicity for this breed. The phrenic vasculature, glandular echogenicity and detail were unremarkable. Capsule, cortex, and medullary definition were normal for this age patient. The left adrenal gland measured 3.37 cm x 0.53 cm at the cranial pole and 0.65 cm at the caudal pole. The right adrenal gland measured 3.67 cm x 1.1 cm at the cranial pole and 0.95 cm at the caudal pole.

Spleen

The **spleen** presented a smooth homogeneous parenchyma hyperechoic to liver and renal cortical parenchyma. The capsule was smooth without noticeable expansion or deviation from within the spleen or adjacent pathology. The splenic vasculature demonstrated normal volume without signs of congestion or thrombosis. No sonographic evidence of acute or chronic inflammatory, neoplastic, or infarctual changes were noted.

Liver

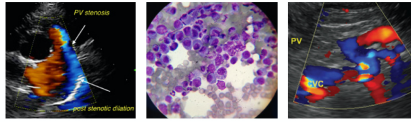

The **liver** images submitted revealed subjectively normal liver size, contour, and structure. Parenchymal echogenicity was naturally coarse and hypoechoic to the spleen. Vascular and biliary tracts were of normal volume with no evidence of congestion. The gallbladder presented acceptably thin walls with primarily anechoic content. The cystic and common bile ducts were normal. No pathological hepatic lymphadenopathy was evident. No overt structural evidence of inflammatory, infiltrative or regenerative pathology was evident.

Gastrointestinal

Examination of the **gastrointestinal tract** revealed minor areas of mural spasm and minor luminal fluid, consistent with gastroenteritis. Mesenteric lymph nodes were slightly enlarged up to 1.5 cm x 10 cm, reactive.

Pancreas

The base and limbs of the **pancreas** were observed to be largely isoechoic to surrounding omental fat. Pancreatic duct and capsular contour were acceptably normal and parenchyma respected normal curvilinear patterns. No overt evidence of active inflammatory or neoplastic disease was noted.



PATIENT

Elsa Nordan

SPECIES

Canine

BREED

Rottweiler

SEX

Spayed Female

AGE

8 Years

WEIGHT

126 Pounds

INTERPRETED BY

Eric Lindquist, DMV
DABVP, Cert. IVUS

IMAGING PERFORMED BY

Sarah Pender, CVT

HOSPITAL NAME

SVS Imaging QC

REFERRING VET

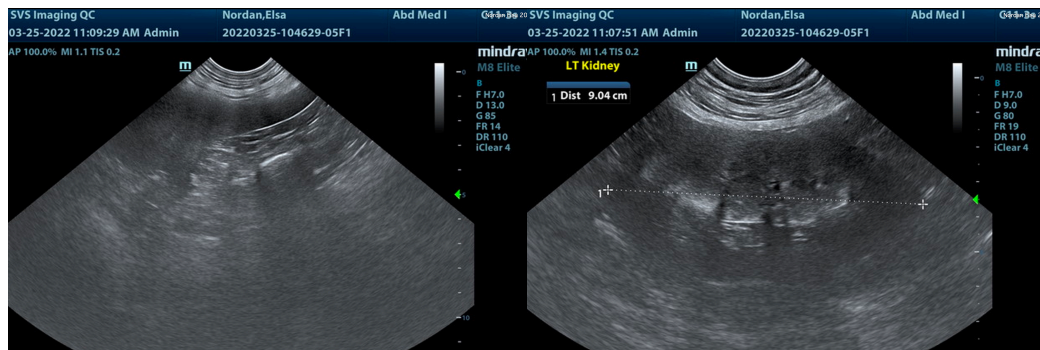
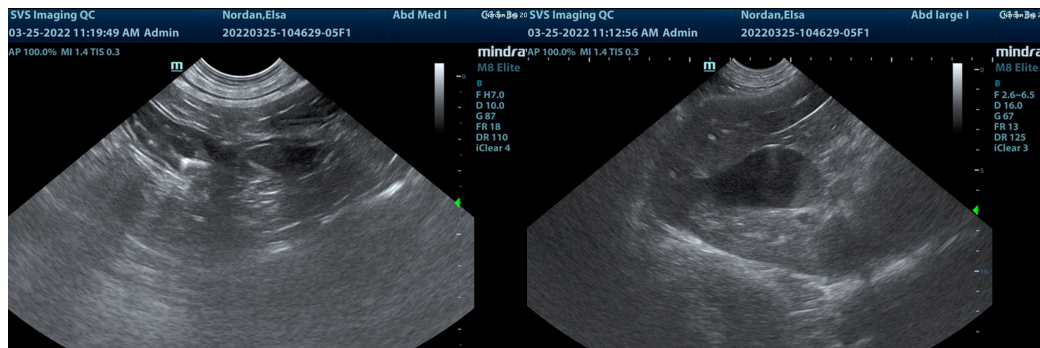
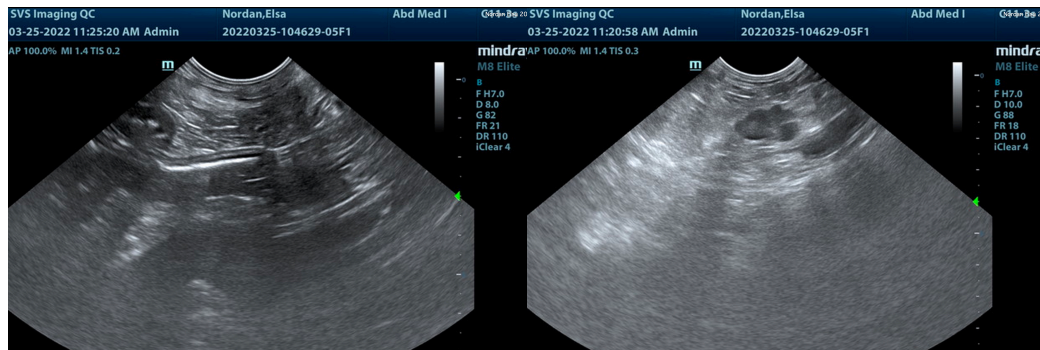
Dr. Haenni

ULTRASONOGRAPHIC FINDINGS

- Gastroenteritis pattern and minor mesenteric lymphadenopathy

INTERPRETATION OF THE FINDINGS & FURTHER RECOMMENDATIONS

No evidence of foreign body. No evidence of neoplastic criteria. Supportive care should prove effective. If clinical signs persist, recheck sonogram indicated. 24-hour NPO, anti-parasitic protocol, IV fluid support, GI protectants +/- FNA of the mesenteric lymph nodes (to ensure an early round cell neoplasia is not developing) recommended. However, no neoplastic criteria present. Acute on chronic inflammatory bowel suspected.

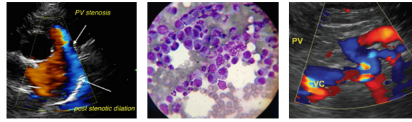



INVOICE

36461

DATE

3/25/22



PATIENT

Elsa Nordan

SPECIES

Canine

BREED

Rottweiler

SEX

Spayed Female

AGE

8 Years

WEIGHT

126 Pounds

INTERPRETED BY

Eric Lindquist, DMV

DABVP, Cert. IVUSS

IMAGING PERFORMED BY

Sarah Pender, CVT

HOSPITAL NAME

SVS Imaging QC

REFERRING VET

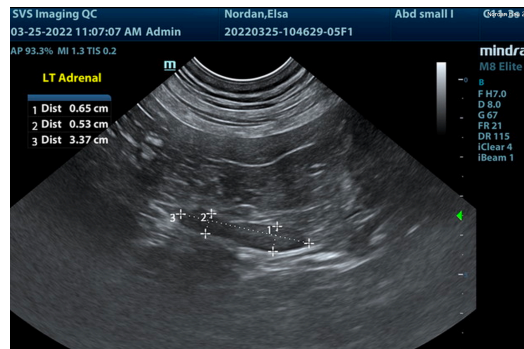
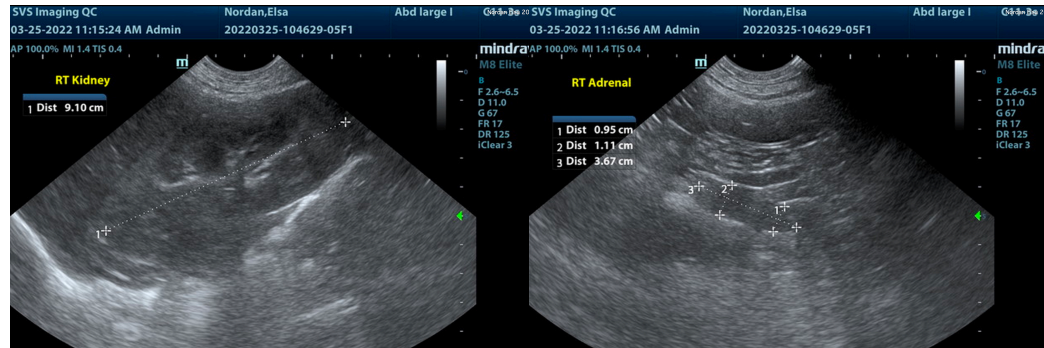
Dr. Haenni

INVOICE

36461

DATE

3/25/22



The information and recommendations provided are based on the images presented by the referring veterinarian/sonographer. No evaluation can be communicated regarding pathology that was not visible in the image/video clips provided.

Thank you for this referral. If the clinical or image interpretation does not parallel your findings or if I can be of any further assistance please contact me.

Eric Lindquist, DMV, DABVP, Cert. IVUSS, CEO of SonoPath.com

info@SonoPath.com