

PATIENT

Eff Eff Sperka

PRESENTING CLINICAL SIGNS

SPECIES

ARF Sunday night, p is waxing and waning azotemic

Feline

Abnormal PE/Chem/CBC/UA Results: CREA 4.5, BUN 65, Marked rods in urine, Urine culture: E. Coli, CBC shows steadily increasing neutrophil count, beyond normal range

BREED

DSH

Urinary System

The **urinary bladder**, trigone, and pelvic urethra presented normal thicknesses and normal tone. The ureters were not visible which is normal. No uroliths or sediment were visualized and anechoic urine was present. No evidence of inflammatory or neoplastic changes were noted.

SEX

Ureteral papillae were normal.

Spayed Female

The **right kidney** presented pyelectasia with enhanced surrounding mesentery. The right kidney measured 3.5 cm. The **left kidney** presented pyelectasia with pericapsular inflammation.

AGE

Pylectasia revealed echogenic debris and pelvic inflammation, consistent with pyelonephritis. The left kidney measured 3.84 cm.

16 Years

Adrenal Glands

The regions of the **adrenal glands** were unremarkable.

WEIGHT

10.5 Pounds

Spleen

The **spleen** was mildly enlarged with slight free fluid present and scalloping contour. Possible concurrent splenitis versus emerging round cell neoplasia. FNA indicated.

INTERPRETED BY

Eric Lindquist, DMV
DABVP, Cert. IVUSS

Liver

The **liver** presented minor heterogeneous changes with minor irregular swelling. Trace free fluid noted. The gallbladder wall was edematous.

Gastrointestinal

Some retention of ingesta noted in the **stomach**. Transit of chyme in the small intestine was unremarkable. No hyperperistalsis present.

IMAGING BY

Loetitia Saint-Jacques,
LVT

Pancreas

The **pancreas** was enlarged and irregular with dilated duct at 0.48 cm. The left limb measured 1.66 cm.

HOSPITAL NAME

Sierra Pet Clinic

Other

Rapid view of the chest revealed slight pleural effusion.

REFERRING VET

Dr. Sperka

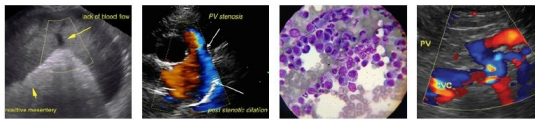
- Bilateral pyelonephritis
- Pancreatitis pattern
- Swollen spleen and liver

INVOICE

36462

DATE

3/25/22



PATIENT

Eff Eff Sperka

INTERPRETATION OF THE FINDINGS & FURTHER RECOMMENDATIONS

SPECIES

Potential emerging round cell neoplasia. Ideally, FNA spleen, liver and kidney recommended. 72-hour IV fluid protocol, urine culture and sensitivity indicated until cytology can be evaluated. Prognosis is guarded.

Feline

BREED

DSH

SEX

Spayed Female

AGE

16 Years

WEIGHT

10.5 Pounds

INTERPRETED BY

Eric Lindquist, DMV
DABVP, Cert. IVUSS

IMAGING BY

Loetitia Saint-Jacques,
LVT

HOSPITAL NAME

Sierra Pet Clinic

REFERRING VET

Dr. Sperka

The information and recommendations provided are based on the images presented by the referring veterinarian/sonographer. No evaluation can be communicated regarding pathology that was not visible in the image/video clips provided.

INVOICE

36462

Eric Lindquist, DMV, DABVP, Cert. IVUSS, CEO of SonoPath.com
info@SonoPath.com

DATE

3/25/22

