



## PATIENT

Token Martinez

## SPECIES

Canine

## BREED

Yorkshire Terrier

## SEX

Neutered male

## AGE

10 years

## WEIGHT

8 lbs

## INTERPRETED BY

Eric Lindquist, DMV  
DABVP, Cert. IVUSS

## IMAGING PERFORMED BY

Jeremiah Gabriel

## HOSPITAL NAME

Central Jersey AH

## REFERRING VET

Dr. Gabriel

## INVOICE

73768

## DATE

3/24/26

## PRESENTING CLINICAL SIGNS

- will travel with the pet to Japan and want to make sure it is safe
- grade 3 heart murmur
- Abnormal PE/Chem/CBC/UA Results: WNL

## ULTRASONOGRAPHIC EXAMINATION OF THE HEART

The echocardiogram in this patient demonstrated enlarged **left atrial** size based on 3 different LA measurement methods. Chamber volumes and echogenicity were normal. The cranial and caudal **mitral** valve leaflets presented vegetative thickening consistent with endocardiosis. Prolapse of the anterior mitral valve leaflet was noted. Doppler indicated measurable insufficiency. The **left ventricle** presented normal thicknesses with linear contour and was not dilated nor restricted. The **myocardium** presented normal echogenicity without subjective evidence of significant fibrotic or ischemic disease. **Contractility** of the ventricular walls was adequate and in normal range for this patient evidenced by the fractional shortening measurement and subjective evaluation of the different regions of the myocardium. The **left ventricular outflow** tract demonstrated normal laminar flow and subjective structural integrity. The **right atrium** and auricle revealed normal size, structure and content. No evidence of masses was noted or chamber overload. **Tricuspid** valvular assessment demonstrated adequate linear morphology. The **right ventricle** was of normal size (1/3 diameter of LV), chordae structure, myocardial echogenicity and thickness. **Pulmonic** insufficiency was also present. No visible **pericardial** or free pleura fluid was noted. No echographically detectable evidence of infiltrative disease was visible. The cranial **mediastinum and pericardial regions** were free of masses in the visible window.

CANINE CARDIAC PARAMETERS	MR VMAX (m/s)	TR VMAX (m/s)	LA/AO	LA/AO (Heart Base)	FS (%)	EF (%)	EPSS (cm)
NORMAL PARAMETER	4.5-5.5	<2.7	1.3	<1.6	28-40	40-100	<0.6
PATIENT	5.4		1.3	1.4			NM
CANINE CARDIAC PARAMETERS	HR (BPM)	AV VMAX (m/s)	PV MAX (m/s)	BODY WEIGHT (kg)	LA 2D short axis Base view (cm)	LVIDd Avg; 2D and m-mode short axis (cm)	LVIDs Avg; 2D and m-mode short axis (cm)
NORMAL PARAMETER	50-100	0.7-1.7	0.7-1.6	BELOW	BELOW	BELOW	BELOW
PATIENT	110	Under-estimated	0.68	8 lbs	3.3	2.63	



## PATIENT

Token Martinez

## SPECIES

Canine

## BREED

Yorkshire Terrier

## SEX

Neutered male

## AGE

10 years

## WEIGHT

8 lbs

## INTERPRETED BY

Eric Lindquist, DMV  
DABVP, Cert. IVUSS

## IMAGING PERFORMED BY

Jeremiah Gabriel

## HOSPITAL NAME

Central Jersey AH

## REFERRING VET

Dr. Gabriel

## INVOICE

73768

## DATE

3/24/26

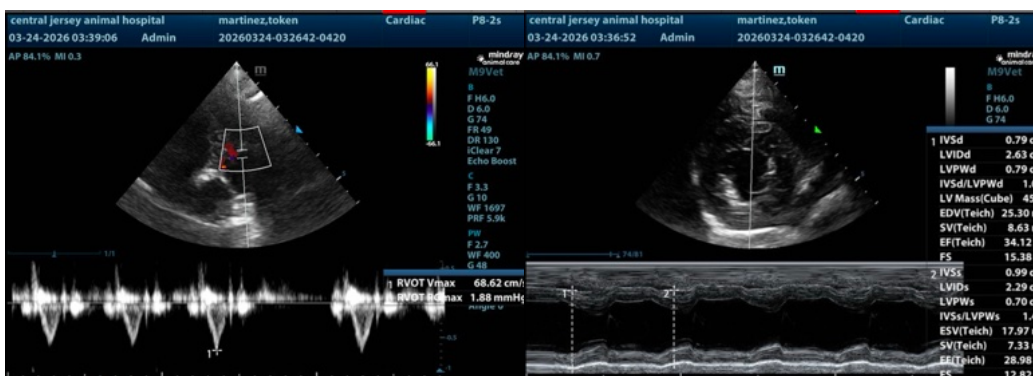
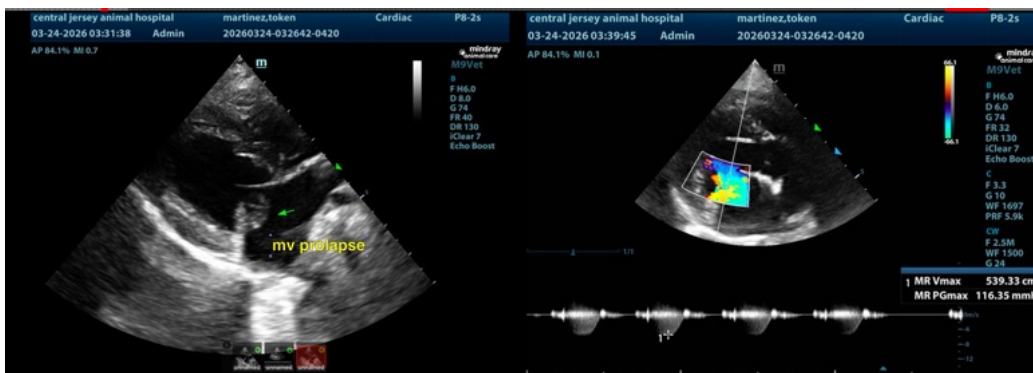## ULTRASONOGRAPHIC FINDINGS

Early stage B2 valvular disease with mitral valve prolapse.

## INTERPRETATION OF THE FINDINGS & FURTHER RECOMMENDATIONS

I believe that the travel risk is mild in this patient. However, I recommend initiating Pimobendan at 0.3 mg/kg b.i.d. ensuring that systolic blood pressure is less than 160. If sedation is to be utilized then opioids and Gabapentin should be safe for this patient.

The heart has minor volume overload and is working to compensate for the valvular insufficiency. Target respiratory rate is < 20 resp/minute after therapy. After initiating or adjusting therapy, I recommend recheck on the clinical exam, BUN, Creatinine, USG, Chest radiographs & Blood pressure in 5-7 days. Recheck echo in 3-6 months, earlier if clinical decompensation is occurring. Minor anesthetic risk for a brief procedure at this time. Repeat preanesthetic echo is ideal if anesthesia is eventually necessary. A suggested anesthetic combination would involve Torbutrol premed, propofol induction, Isoflurane maintenance or equivalent protocol.





**PATIENT**

Token Martinez

**SPECIES**

Canine

**BREED**

Yorkshire Terrier

**SEX**

Neutered male

**AGE**

10 years

**WEIGHT**

8 lbs

**INTERPRETED BY**

Eric Lindquist, DMV  
DABVP, Cert. IVUSS

**IMAGING PERFORMED BY**

Jeremiah Gabriel

**HOSPITAL NAME**

Central Jersey AH

**REFERRING VET**

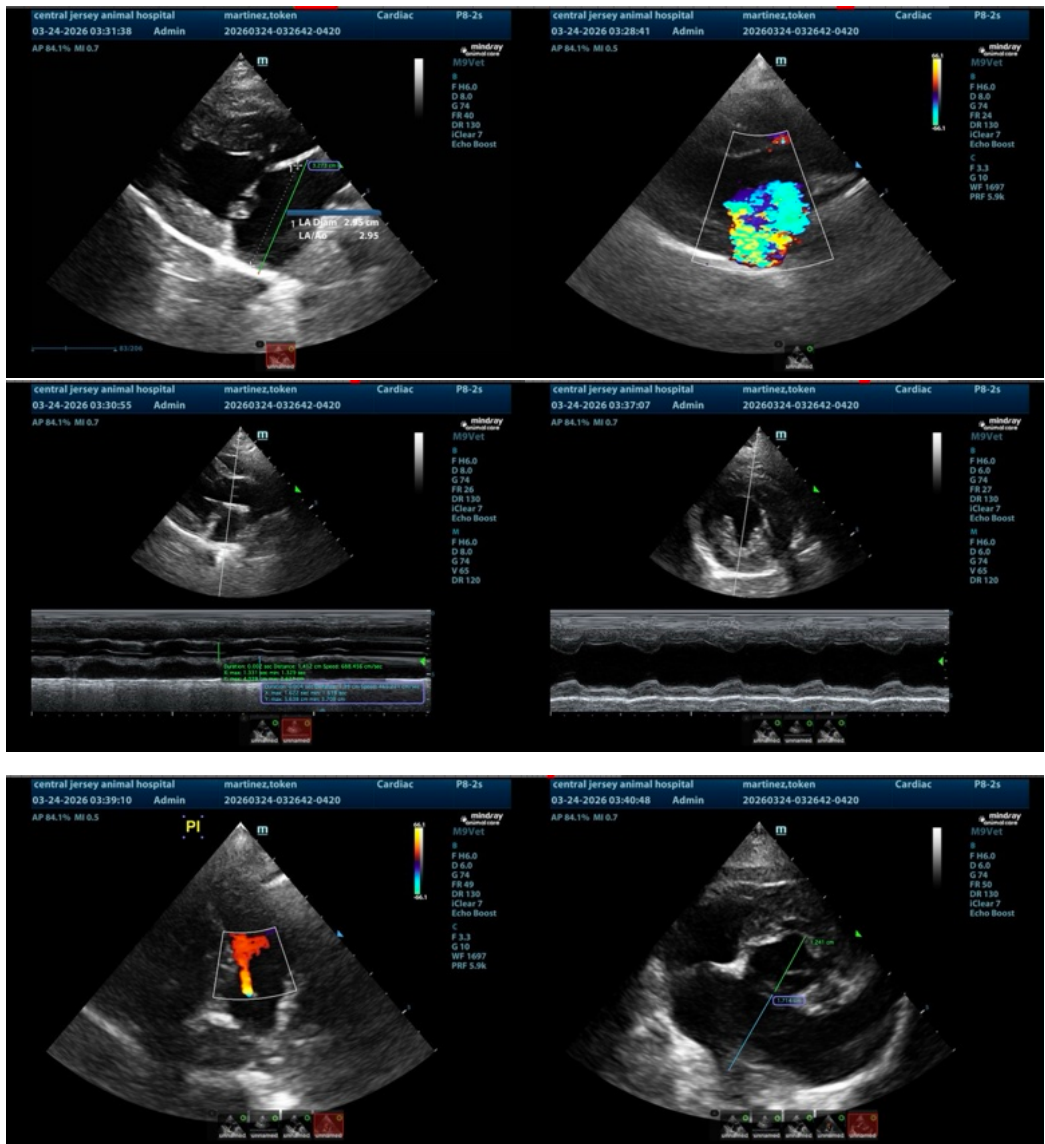
Dr. Gabriel

**INVOICE**

73768

**DATE**

3/24/26



The information and recommendations provided are based on the images presented by the referring veterinarian/sonographer. No evaluation can be communicated regarding pathology that was not visible in the image/video clips provided.

Thank you for this referral. If the clinical or image interpretation does not parallel your findings or if I can be of any further assistance please contact me.

Eric Lindquist, DMV, DABVP (CFM), Cert. IVUSS, CEO of SonoPath.com

[info@SonoPath.com](mailto:info@SonoPath.com)