



PATIENT

Sophie Morrison

SPECIES

Canine

BREED

Dachshund Mix

SEX

Spayed female

AGE

6 years

WEIGHT

18 lbs

INTERPRETED BY

Eric Lindquist, DMV
DABVP, Cert. IVUSS

IMAGING PERFORMED BY

Michelle Roche

HOSPITAL NAME

Fredon AH

REFERRING VET

Dr. Roche

INVOICE

73755

DATE

3/24/26

PRESENTING CLINICAL SIGNS

- Chronic intermittent vomiting/diarrhea
- Typically responds to cerenia/metronidazole
- Unremarkable exam, amputated LH CBC/chem unremarkable per owner- other vet performed two weeks ago

ULTRASONOGRAPHIC EXAMINATION OF THE ABDOMEN

Urinary System

The **urinary bladder**, trigone, and pelvic urethra presented normal thicknesses and normal tone. The ureters were not visible which is normal. A minor amount of suspended debris was noted. No evidence of inflammatory or neoplastic changes was noted. Ureteral papillae were normal.

The **kidneys** revealed normal size and structure, corticomedullary definition and ratio for this age. The cortices presented largely uniform texture with normal echogenic relationship to liver and spleen. Medullary structure differed distinctly from the cortex and no evidence of pelvic dilation was present. The capsules were acceptably uniform without significant irregularities. The left kidney measured 4.4 cm. The right kidney measured 4.4 cm.

Adrenal Glands

Both **adrenal glands** were visualized and recognized as having normal shape, size, position and echogenicity for this breed. The phrenic vasculature, glandular echogenicity and detail were unremarkable. Capsule, cortex, and medullary definition were normal for this age patient. The left adrenal gland measured 0.5 cm. The right adrenal gland measured 0.5 cm.

Spleen

The **spleen** presented a smooth homogeneous parenchyma hyperechoic to liver and renal cortical parenchyma. The capsule was smooth without noticeable expansion or deviation from within the spleen or adjacent pathology. The splenic vasculature demonstrated normal volume without signs of congestion or thrombosis. No sonographic evidence of acute or chronic inflammatory, neoplastic, or infarctual changes was noted.

Liver

The **liver** revealed slightly increased portal markings. The liver is normal in size and contour. The gallbladder and common bile duct were unremarkable.

Gastrointestinal

The **gastrointestinal** presentation revealed mild uniform prominence of the gastric mucosa as well as areas of "ropey" small intestinal wall with slight disruption of the normal 1:3 muscularis/mucosal ratio. The intestinal submucosa was slightly irregular, thickened and hyperechoic suggestive of low grade,



PATIENT

Sophie Morrison

SPECIES

Canine

BREED

Dachshund Mix

SEX

Spayed female

AGE

6 years

WEIGHT

18 lbs

INTERPRETED BY

Eric Lindquist, DMV
DABVP, Cert. IVUSS

IMAGING PERFORMED BY

Michelle Roche

HOSPITAL NAME

Fredon AH

REFERRING VET

Dr. Roche

INVOICE

73755

DATE

3/24/26

chronic disease. No concerning lymphadenopathy was visible. No evidence of obstruction was present. Chronic inflammatory bowel disease is likely with a low possibility of an early neoplastic event such as lymphoma. Full thickness tissue biopsies via open laparotomy, ideally guided by intraoperative ultrasound in order to obtain the most representative mural sample, would be necessary to rule out this possibility.

Pancreas

The base and limbs of the **pancreas** were observed to be largely isoechoic to surrounding omental fat. Pancreatic duct and capsular contour were acceptably normal and parenchyma respected normal curvilinear patterns. No overt evidence of active inflammatory or neoplastic disease was noted.

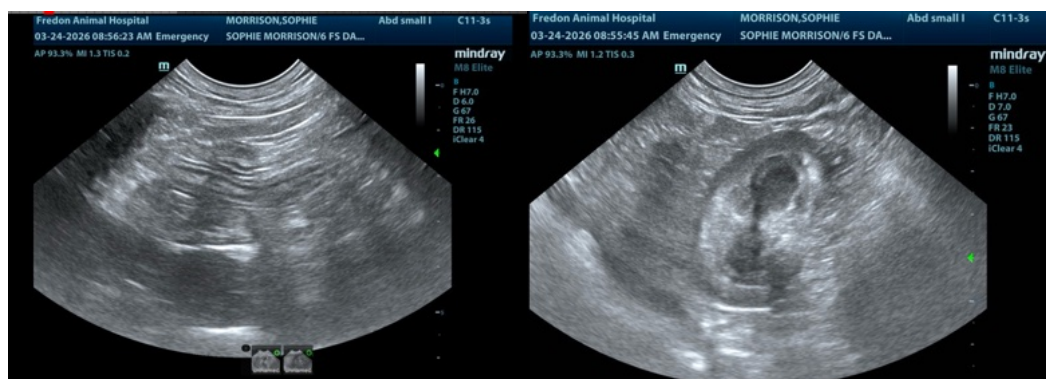
ULTRASONOGRAPHIC FINDINGS

IBD GI Pattern.

Increased portal markings in the liver.

INTERPRETATION OF THE FINDINGS & FURTHER RECOMMENDATIONS

Given the repetitive issues, full thickness gastrointestinal biopsies would be ideal. Fecal test, diet change to a hydrolyzed diet and Prednisolone trial would all be indicated. If general management for inflammatory bowel does not appear effective, then full thickness surgical biopsies of the GI tract would be ideal. I do recommend screening for occult Addison's even though the adrenal glands appear normal.





PATIENT

Sophie Morrison

SPECIES

Canine

BREED

Dachshund Mix

SEX

Spayed female

AGE

6 years

WEIGHT

18 lbs

INTERPRETED BY

Eric Lindquist, DMV
DABVP, Cert. IVUSS

**IMAGING
PERFORMED BY**

Michelle Roche

HOSPITAL NAME

Fredon AH

REFERRING VET

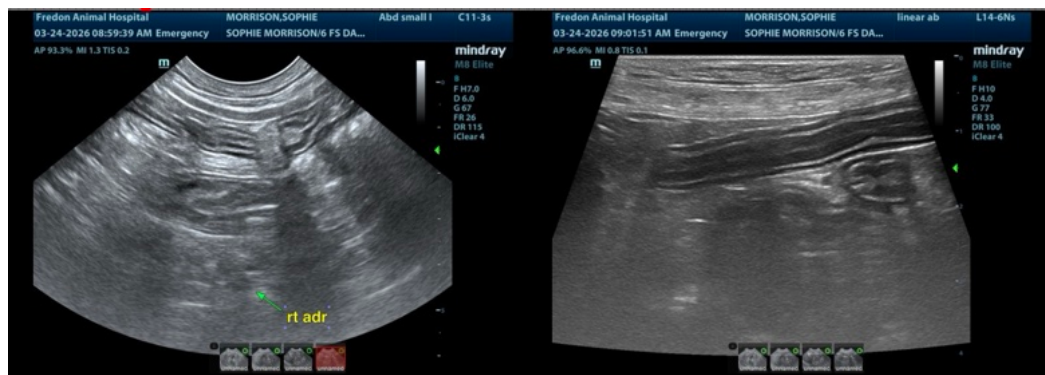
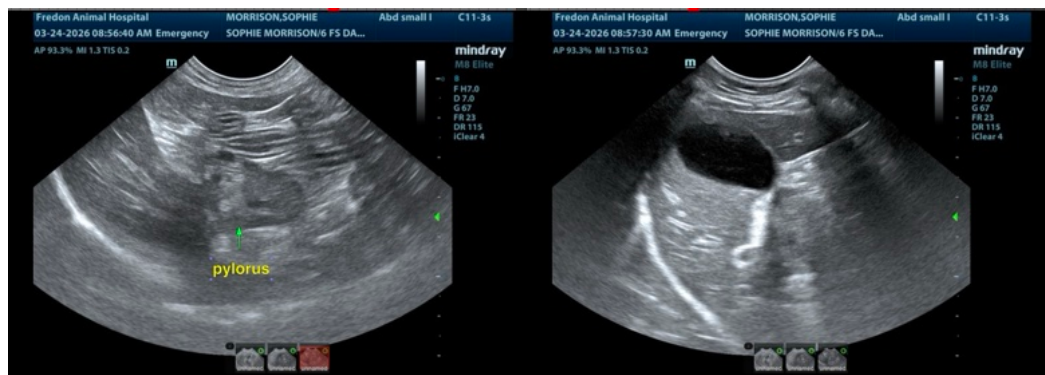
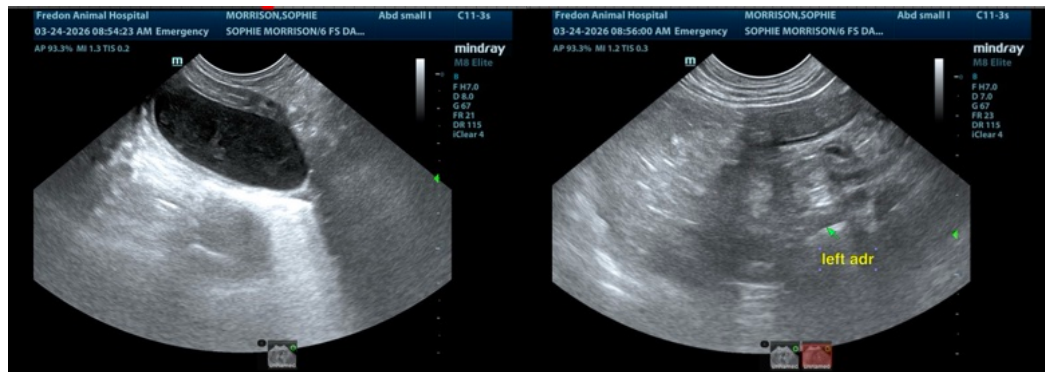
Dr. Roche

INVOICE

73755

DATE

3/24/26



The information and recommendations provided are based on the images presented by the referring veterinarian/sonographer. No evaluation can be communicated regarding pathology that was not visible in the image/video clips provided.

Thank you for this referral. If the clinical or image interpretation does not parallel your findings or if I can be of any further assistance please contact me.

Eric Lindquist, DMV, DABVP (CFM), Cert. IVUSS, CEO of SonoPath.com

info@SonoPath.com