



PATIENT

Shay Shay Martz

SPECIES

Feline

BREED

DSH

SEX

Intact Female

AGE

2 Years

WEIGHT

5 pounds

INTERPRETED BY

Eric Lindquist, DMV,
DABVP(CFM), Cert.
IVUSS

IMAGING PERFORMED BY

Dr. Wasserman

HOSPITAL NAME

Morningside Animal
Hospital

REFERRING VET

Dr. Wasserman

INVOICE

14584

DATE

03/24/26

PRESENTING CLINICAL SIGNS

Presents for abdominal assessment. Reported mass palpated in the cranial abdomen at the time of planned spay. Spay was deferred at this time and client was recommended to have ultrasound performed prior to spay. Sedated with equal volume (0.1ml) of Dexdomitor 0.5mg/ml, ketamine 100mg/ml, butorphanol 10mg/ml IM

Abnormal PE/Chem/CBC/UA Results: UR SG obtained at time of US by cystocentesis 1.045.

ULTRASONOGRAPHIC EXAMINATION OF THE ABDOMEN

Urinary System

The **urinary bladder**, trigone, and pelvic urethra to a depth of 2.0 cm presented normal thicknesses and normal tone. The ureters were not visible which is normal. No uroliths or sediment were visualized, and anechoic urine was present. No evidence of inflammatory or neoplastic changes were noted. Ureteral papillae were normal.

The **kidneys** revealed normal size and structure, corticomedullary definition and ratio for this age. The cortices presented largely uniform texture with normal echogenic relationship to liver and spleen. Medullary structure differed distinctly from the cortex and no evidence of pelvic dilation was present. The capsules were acceptably uniform without significant irregularities. The left kidney measured 3.23 cm in length. The right kidney measured 3.17 cm in length.

Adrenal Glands

Both **adrenal glands** were visualized and recognized as having normal shape, size, position and echogenicity for this breed. The phrenic vasculature, glandular echogenicity and detail were unremarkable. Capsule, cortex, and medullary definition were normal for this age patient. The left adrenal gland measured 0.34 cm width. The right adrenal gland measured 0.26 cm width.

Spleen

The **spleen** presented a smooth homogeneous parenchyma hyperechoic to liver and renal cortical parenchyma. The capsule was smooth without noticeable expansion or deviation from within the spleen or adjacent pathology. The splenic vasculature demonstrated normal volume without signs of congestion or thrombosis. No sonographic evidence of acute or chronic inflammatory, neoplastic, or infarctual changes were noted.

Liver

The **liver** revealed slight increased portal markings. The gallbladder and common bile duct were unremarkable. No evidence of masses.

Gastrointestinal

Examination of the **gastrointestinal tract** revealed a stomach and intestine free of stasis, of normal wall thickness, acceptable curvilinear mural detail, and peristaltic activity. Small and large intestine demonstrated normal luminal chyme and stool consistency respectively. No obstructive or overt infiltrative disease was noted. No associated abnormal lymphatic activity was noted.

Pancreas



PATIENT

Shay Shay Martz

SPECIES

Feline

BREED

DSH

SEX

Intact Female

AGE

2 Years

WEIGHT

5 pounds

INTERPRETED BY

Eric Lindquist, DMV,
DABVP(CFM), Cert.
IVUSS

IMAGING PERFORMED BY

Dr. Wasserman

HOSPITAL NAME

Morningside Animal
Hospital

REFERRING VET

Dr. Wasserman

INVOICE

14584

DATE

03/24/26

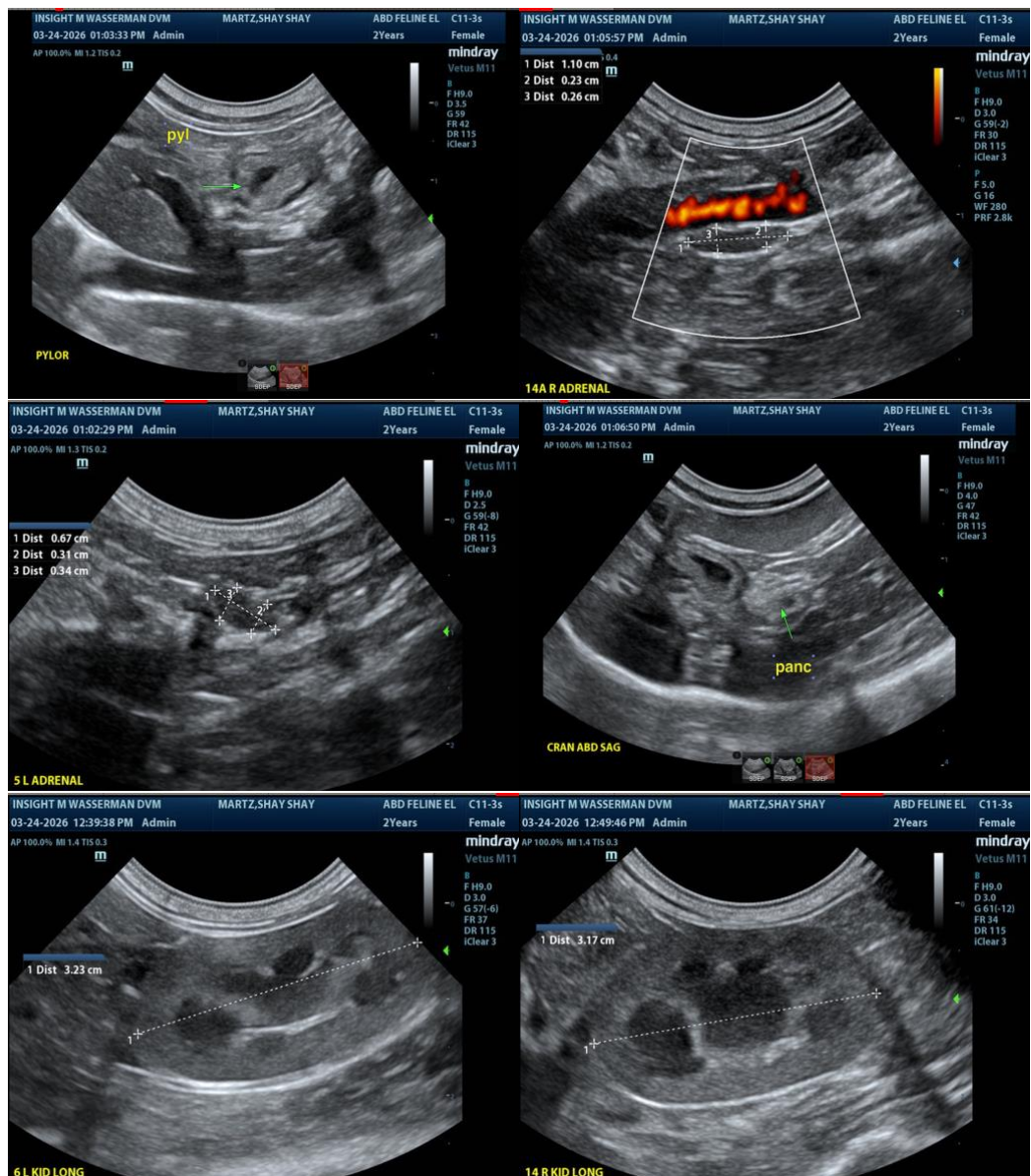
The base and limbs of the **pancreas** were observed to be largely isoechoic to surrounding omental fat. Pancreatic duct and capsular contour were acceptably normal and parenchyma respected normal curvilinear patterns. No overt evidence of active inflammatory or neoplastic disease was noted.

ULTRASONOGRAPHIC FINDINGS

- Normal abdomen with slight hepatic remodeling.

INTERPRETATION OF THE FINDINGS & FURTHER RECOMMENDATIONS

A history of cholangitis is likely yet appears stable at this time.





PATIENT

Shay Shay Martz

SPECIES

Feline

BREED

DSH

SEX

Intact Female

AGE

2 Years

WEIGHT

5 pounds

INTERPRETED BY

Eric Lindquist, DMV,
DABVP(CFM), Cert.
IVUSS

IMAGING PERFORMED BY

Dr. Wasserman

HOSPITAL NAME

Morningside Animal
Hospital

REFERRING VET

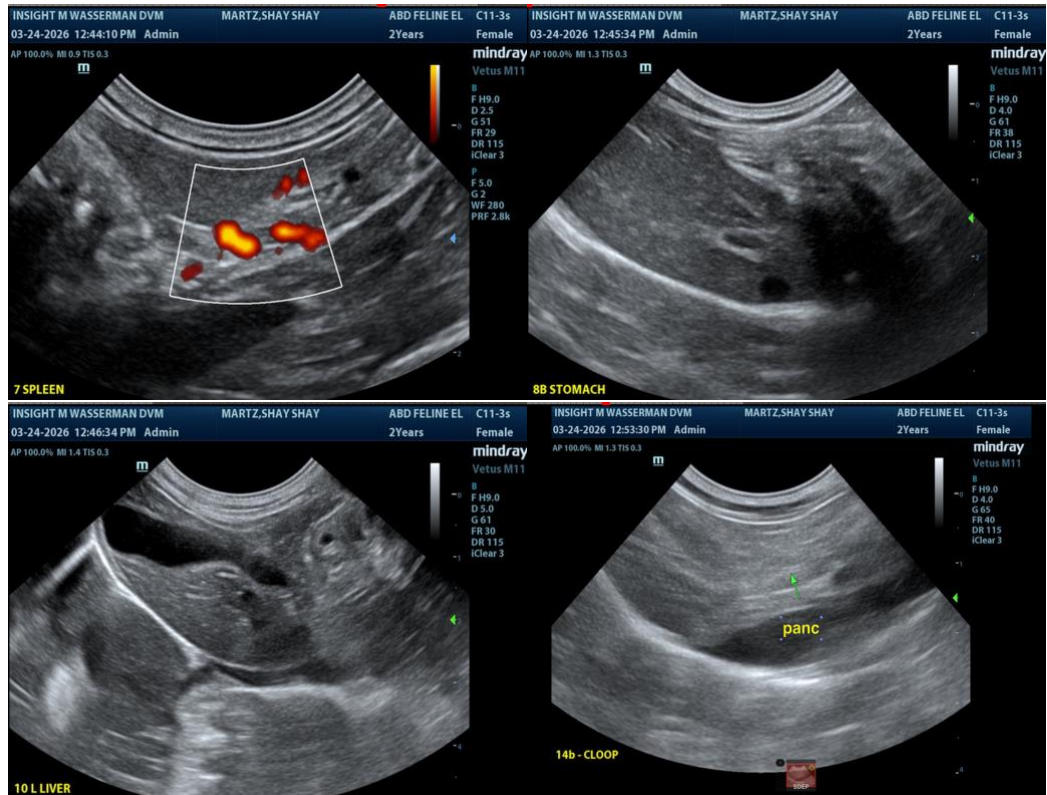
Dr. Wasserman

INVOICE

14584

DATE

03/24/26



The information and recommendations provided are based on the images presented by the referring veterinarian/sonographer. No evaluation can be communicated regarding pathology that was not visible in the image/video clips provided.

Thank you for this referral. If the clinical or image interpretation does not parallel your findings or if I can be of any further assistance, please contact me.

Eric Lindquist, DMV, DABVP(CFM), Cert. IVUSS,

CEO, Owner, Founder -- SonoPath.com

info@SonoPath.com