

## PATIENT

King Kelmer

## SPECIES

Canine

## BREED

Chihuahua

## SEX

Neutered male

## AGE

11 years

## WEIGHT

6.95 lbs

## INTERPRETED BY

Eric Lindquist, DMV  
DABVP, Cert. IVUSS

## IMAGING PERFORMED BY

Meghan Myers, VMD

## HOSPITAL NAME

Hershire AH

## REFERRING VET

Dr. Gallisdorfer

## INVOICE

73777

## DATE

3/24/26

## PRESENTING CLINICAL SIGNS

- 2 year history of on and off again diarrhea - initially started with episode of AHDS in Sept 2023 and since then has multiple bouts of frank blood in stool- on GI biome chronically, bloodwork WNL

## ULTRASONOGRAPHIC EXAMINATION OF THE ABDOMEN

### *Urinary System*

The **urinary bladder**, trigone, and pelvic urethra presented normal thicknesses and normal tone. The ureters were not visible which is normal. No uroliths or sediment were visualized and anechoic urine was present. No evidence of inflammatory or neoplastic changes was noted. Ureteral papillae were normal.

The **kidneys** revealed normal size and structure, corticomedullary definition and ratio for this age. The cortices presented largely uniform texture with normal echogenic relationship to liver and spleen. Medullary structure differed distinctly from the cortex and no evidence of pelvic dilation was present. The capsules were acceptably uniform without significant irregularities. The right kidney measured 3.7 cm.

### *Adrenal Glands*

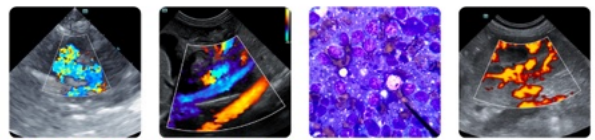
Both **adrenal glands** were visualized and recognized as having normal shape, size, position and echogenicity for this breed. The phrenic vasculature, glandular echogenicity and detail were unremarkable. Capsule, cortex, and medullary definition were normal for this age patient. The right adrenal gland measured 0.66 cm at the cranial pole and 0.4 cm at the caudal pole. The left adrenal gland measured 0.48 cm at the caudal pole and 0.45 cm at the cranial pole.

### *Spleen*

The **spleen** presented a smooth homogeneous parenchyma hyperechoic to liver and renal cortical parenchyma. The capsule was smooth without noticeable expansion or deviation from within the spleen or adjacent pathology. The splenic vasculature demonstrated normal volume without signs of congestion or thrombosis. No sonographic evidence of acute or chronic inflammatory, neoplastic, or infarctual changes was noted.

### *Liver*

The **liver** images submitted revealed subjectively normal liver size, contour, and structure. Parenchymal echogenicity was naturally coarse and hypoechoic to the spleen. Vascular and biliary tracts were of normal volume with no evidence of congestion. The gallbladder presented acceptably thin walls with primarily anechoic content. The cystic and common bile ducts were normal. No pathological hepatic



## PATIENT

King Kelmer

## SPECIES

Canine

## BREED

Chihuahua

## SEX

Neutered male

## AGE

11 years

## WEIGHT

6.95 lbs

## INTERPRETED BY

Eric Lindquist, DMV  
DABVP, Cert. IVUSS

## IMAGING PERFORMED BY

Meghan Myers, VMD

## HOSPITAL NAME

Hershire AH

## REFERRING VET

Dr. Gallisdorfer

## INVOICE

73777

## DATE

3/24/26

lymphadenopathy was evident. No overt structural evidence of inflammatory, infiltrative or regenerative pathology was evident.

## Gastrointestinal

Examination of the **gastrointestinal tract** revealed a stomach and intestine free of stasis, of normal wall thickness, acceptable curvilinear mural detail, and peristaltic activity. Small and large intestine demonstrated normal luminal chyme and stool consistency respectively. No obstructive or overt infiltrative disease was noted. No associated abnormal lymphatic activity was noted.

## Pancreas

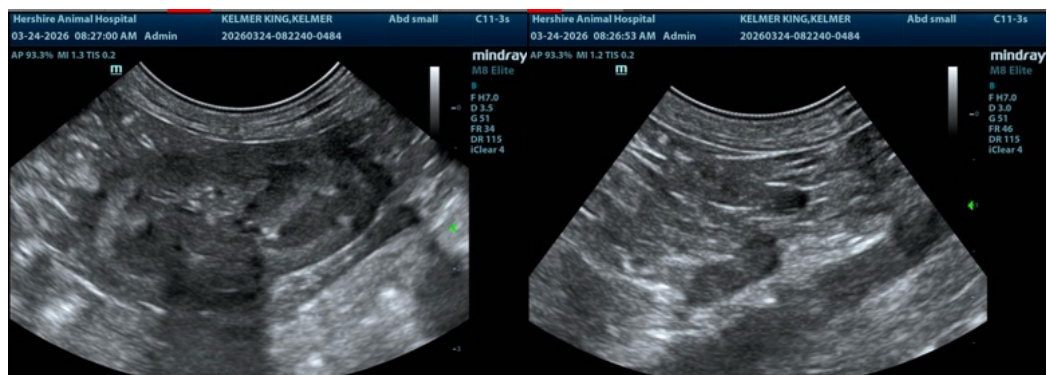
The base and limbs of the **pancreas** were observed to be largely isoechoic to surrounding omental fat. Pancreatic duct and capsular contour were acceptably normal and parenchyma respected normal curvilinear patterns. No overt evidence of active inflammatory or neoplastic disease was noted.

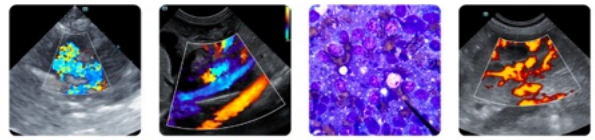
## ULTRASONOGRAPHIC FINDINGS

Structurally normal abdomen, no evidence of pathology.

## INTERPRETATION OF THE FINDINGS & FURTHER RECOMMENDATIONS

Differentials for diarrhea include occult parasitism. Dietary indiscretion, dietary intolerance, antibiotic responsive colitis, intestinal dysbiosis and occult Addison's should all be considered as causes of diarrhea in this patient. A hydrolyzed diet trial may be in this patient's best interest +/- probiotics. 24-hour NPO and reintroduction of bland diet indicated. I recommend a baseline cortisol or ACTH stimulation test, a fresh fecal smear and fecal floatation analysis if not already performed





**PATIENT**

King Kelmer

**SPECIES**

Canine

**BREED**

Chihuahua

**SEX**

Neutered male

**AGE**

11 years

**WEIGHT**

6.95 lbs

**INTERPRETED BY**

Eric Lindquist, DMV  
DABVP, Cert. IVUSS

**IMAGING PERFORMED BY**

Meghan Myers, VMD

**HOSPITAL NAME**

Hershire AH

**REFERRING VET**

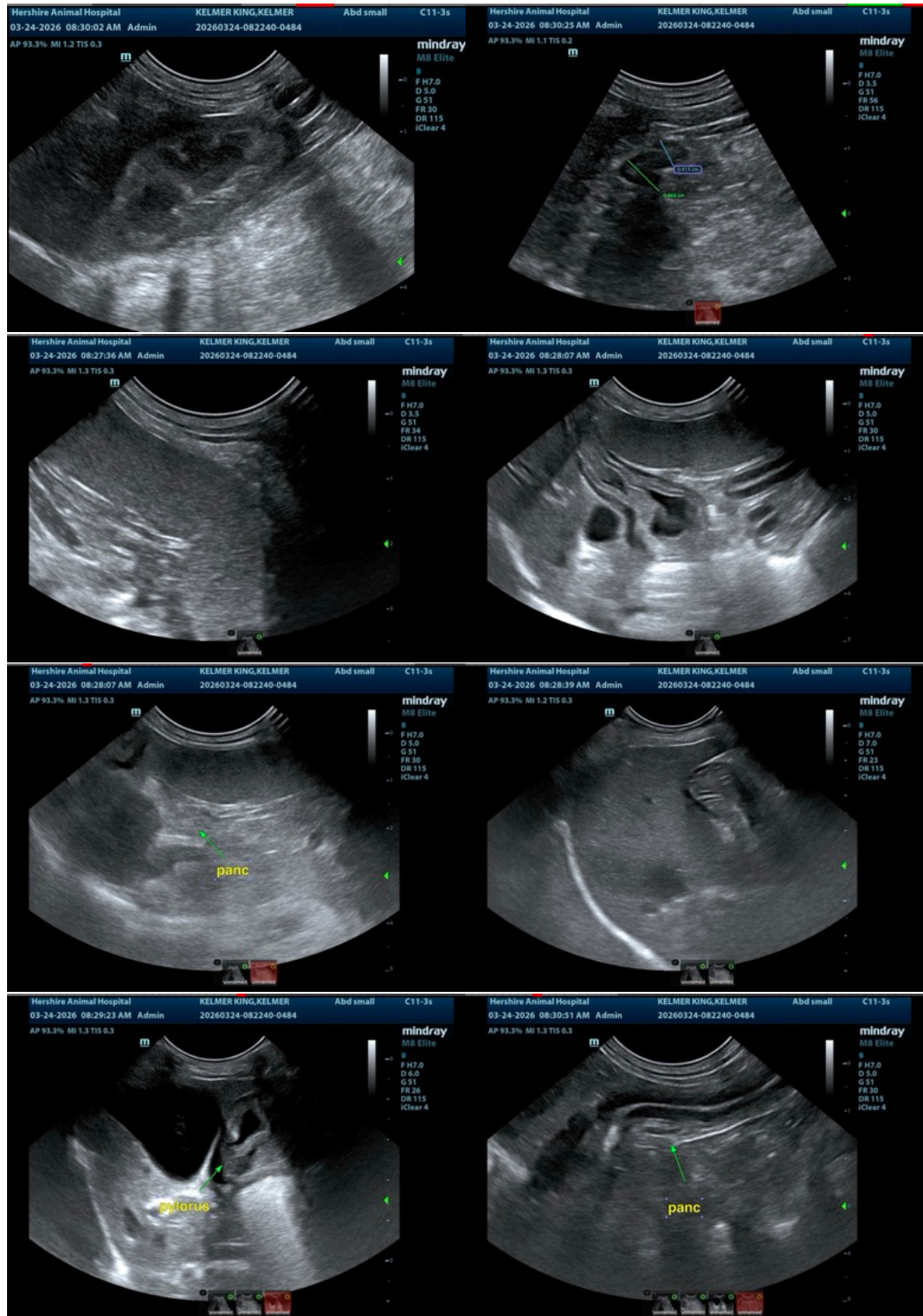
Dr. Gallisdorfer

**INVOICE**

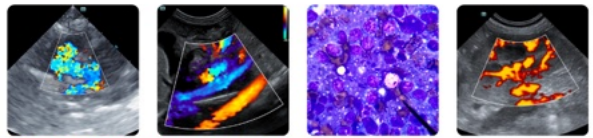
73777

**DATE**

3/24/26



The information and recommendations provided are based on the images presented by the referring veterinarian/sonographer. No evaluation can be communicated regarding pathology



## PATIENT

King Kelmer

## SPECIES

Canine

## BREED

Chihuahua

## SEX

Neutered male

## AGE

11 years

## WEIGHT

6.95 lbs

## INTERPRETED BY

Eric Lindquist, DMV  
DABVP, Cert. IVUSS

## IMAGING PERFORMED BY

Meghan Myers, VMD

## HOSPITAL NAME

Hershire AH

## REFERRING VET

Dr. Gallisdorfer

## INVOICE

73777

## DATE

3/24/26

**that was not visible in the image/video clips provided.**

Thank you for this referral. If the clinical or image interpretation does not parallel your findings or if I can be of any further assistance please contact me.

Eric Lindquist, DMV, DABVP (CFM), Cert. IVUSS, CEO of SonoPath.com

[info@SonoPath.com](mailto:info@SonoPath.com)