



PATIENT

Eleanor Shapiro

SPECIES

Canine

BREED

Labrador Retriever

SEX

Spayed Female

AGE

3

WEIGHT

58.8

INTERPRETED BY

Eric Lindquist, DMV,
DABVP(CFM), Cert.
IVUSS

IMAGING PERFORMED BY

Dr. Susan Lincoski

HOSPITAL NAME

University Drive
Veterinary Hospital

REFERRING VET

Dr. Susan Lincoski

INVOICE

14587

DATE

03/24/26

PRESENTING CLINICAL SIGNS

- Patient is from a rescue, and was considered spayed
- signs of estrus noted, currently having what appears to be a heat cycle
- suspect ovarian remnant
- anti-mullerian test is pending

Abnormal PE/Chem/CBC/UA Results: Brown vaginal discharge, "clingy" behavior noted, cyclic?

ULTRASONOGRAPHIC EXAMINATION OF THE ABDOMEN

Urinary System

The **urinary bladder**, trigone, and pelvic urethra to a depth of 2.0 cm presented normal thicknesses and normal tone. The ureters were not visible which is normal. No uroliths or sediment were visualized, and anechoic urine was present. No evidence of inflammatory or neoplastic changes were noted. Ureteral papillae were normal.

A mixed hypoechoic 2.0 cm x 1.0 cm structure was noted caudal to the left kidney and suspect ovarian remnant as this is the region of the ovarian fossa however, the uterine stump was not visualized in this patient.

The **kidneys** revealed normal size and structure, corticomedullary definition and ratio for this age. The cortices presented largely uniform texture with normal echogenic relationship to liver and spleen. Medullary structure differed distinctly from the cortex and no evidence of pelvic dilation was present. The capsules were acceptably uniform without significant irregularities. The left kidney measured 6.0 cm in length. The right kidney measured 6.6 cm in length.

Adrenal Glands

The **left adrenal gland** was visualized and recognized as having normal shape, size, position and echogenicity for this breed. The phrenic vasculature, glandular echogenicity and detail were unremarkable. Capsule, cortex, and medullary definition were normal for this age patient. The left adrenal gland measured 0.64 cm width.

The region of the **right adrenal gland** was imaged with no evident pathology.

Spleen

The **spleen** presented a smooth homogeneous parenchyma hyperechoic to liver and renal cortical parenchyma. The capsule was smooth without noticeable expansion or deviation from within the spleen or adjacent pathology. The splenic vasculature demonstrated normal volume without signs of congestion or thrombosis. No sonographic evidence of acute or chronic inflammatory, neoplastic, or infarctual changes were noted. The spleen was folded upon itself cranially.

Liver

The **liver** images submitted revealed subjectively normal liver size, contour, and structure. Parenchymal echogenicity was naturally coarse and hypoechoic to the spleen. Vascular and biliary tracts were of normal volume with no evidence of congestion. The gallbladder presented acceptably thin walls with primarily anechoic content. The cystic and common bile ducts were normal. No



PATIENT

Eleanor Shapiro

pathological hepatic lymphadenopathy was evident. No overt structural evidence of inflammatory, infiltrative or regenerative pathology was evident.

SPECIES

Canine

Gastrointestinal

Examination of the **gastrointestinal tract** revealed a stomach and intestine free of stasis, of normal wall thickness, acceptable curvilinear mural detail, and peristaltic activity. Small and large intestine demonstrated normal luminal chyme and stool consistency respectively. No obstructive or overt infiltrative disease was noted. No associated abnormal lymphatic activity was noted.

BREED

Labrador Retriever

Pancreas

SEX

Spayed Female

The base and limbs of the **pancreas** were observed to be largely isoechoic to surrounding omental fat. Pancreatic duct and capsular contour were acceptably normal and parenchyma respected normal curvilinear patterns. No overt evidence of active inflammatory or neoplastic disease was noted.

AGE

3

ULTRASONOGRAPHIC FINDINGS

- Folded spleen.
- Hypoechoic structure caudal to the left kidney.

WEIGHT

58.8

INTERPRETATION OF THE FINDINGS & FURTHER RECOMMENDATIONS

Recommend further imaging. If anti-malarian testing is positive, then exploratory surgery is indicated with focus on both ovarian fossa but particularly the left one as well as the region of the uterine stump even though no evident pathology noted in this region.

INTERPRETED BY

Eric Lindquist, DMV,
DABVP(CFM), Cert.
IVUSS

IMAGING PERFORMED BY

Dr. Susan Lincoski

HOSPITAL NAME

University Drive
Veterinary Hospital

REFERRING VET

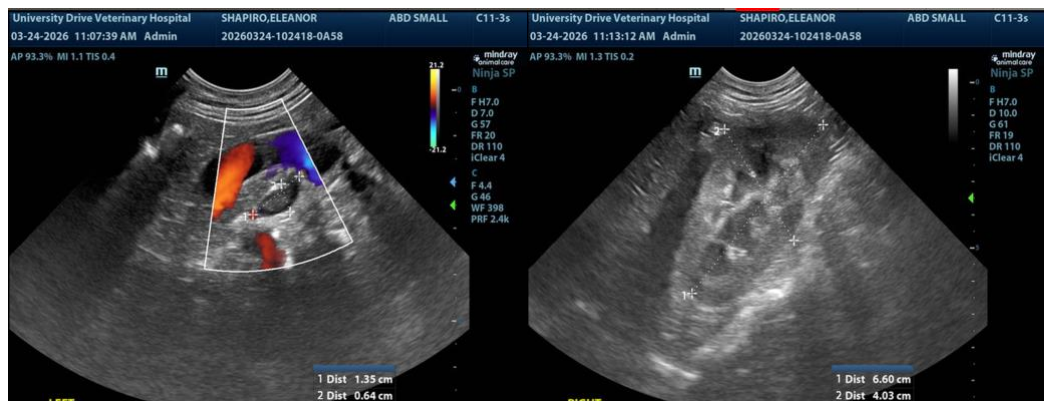Dr. Susan Lincoski

INVOICE

14587

DATE

03/24/26





PATIENT

Eleanor Shapiro

SPECIES

Canine

BREED

Labrador Retriever

SEX

Spayed Female

AGE

3

WEIGHT

58.8

INTERPRETED BY

Eric Lindquist, DMV,
DABVP(CFM), Cert.
IVUSS

IMAGING PERFORMED BY

Dr. Susan Lincoski

HOSPITAL NAME

University Drive
Veterinary Hospital

REFERRING VET

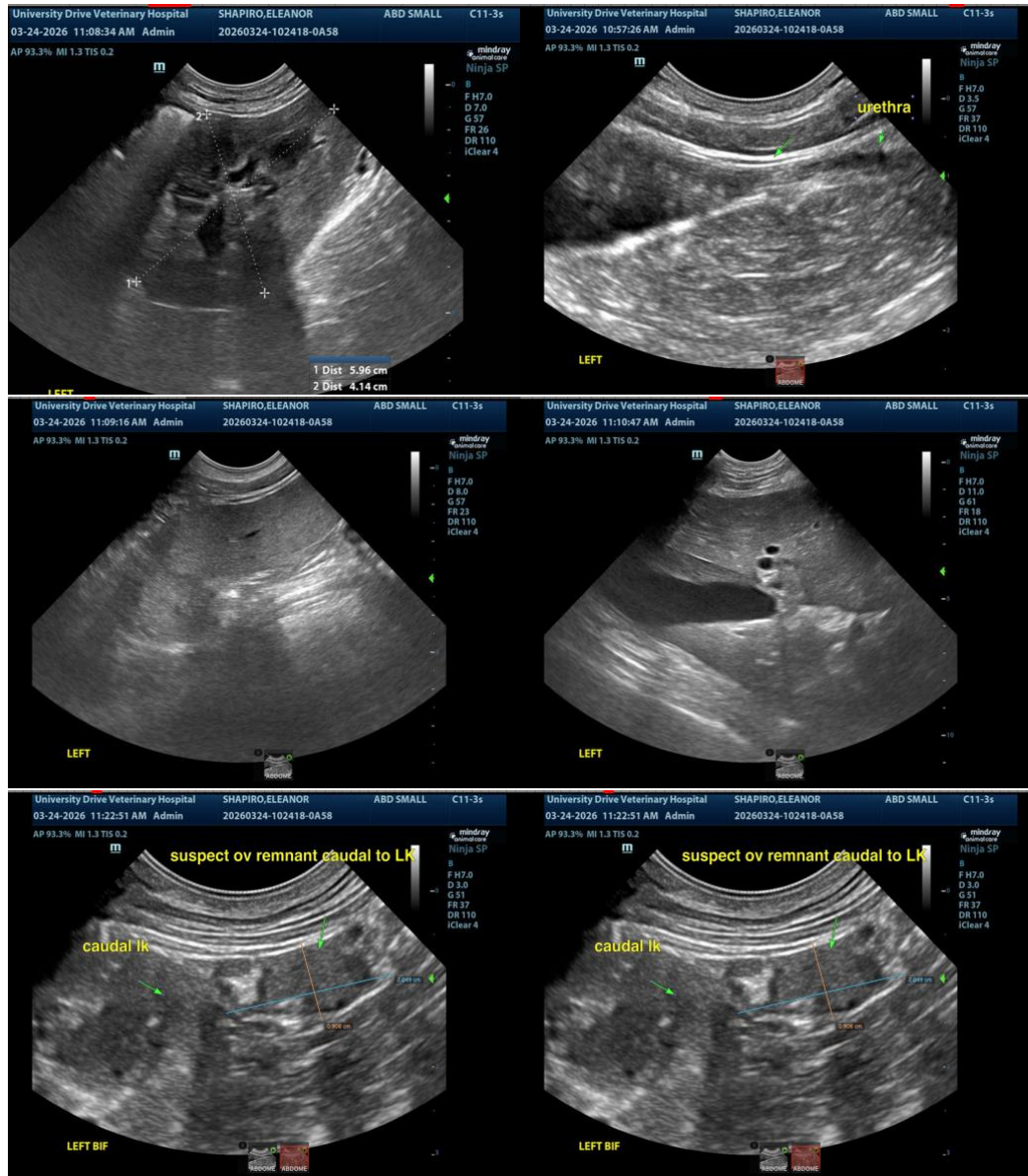
Dr. Susan Lincoski

INVOICE

14587

DATE

03/24/26



The information and recommendations provided are based on the images presented by the referring veterinarian/sonographer. No evaluation can be communicated regarding pathology that was not visible in the image/video clips provided.

Thank you for this referral. If the clinical or image interpretation does not parallel your findings or if I can be of any further assistance, please contact me.

Eric Lindquist, DMV, DABVP(CFM), Cert. IVUSS,

CEO, Owner, Founder -- SonoPath.com

info@SonoPath.com



PATIENT

Eleanor Shapiro

SPECIES

Canine

BREED

Labrador Retriever

SEX

Spayed Female

AGE

3

WEIGHT

58.8

INTERPRETED BY

Eric Lindquist, DMV,
DABVP(CFM), Cert.
IVUSS

IMAGING PERFORMED BY

Dr. Susan Lincoski

HOSPITAL NAME

University Drive
Veterinary Hospital

REFERRING VET

Dr. Susan Lincoski

INVOICE

14587

DATE

03/24/26