



PATIENT

Cody Marques

SPECIES

Canine

BREED

Pitbull Mix

SEX

Neutered male

AGE

11 years

WEIGHT

61 lbs

INTERPRETED BY

Eric Lindquist, DMV
DABVP, Cert. IVUSS

IMAGING PERFORMED BY

Dr. Christensen

HOSPITAL NAME

Tranquility VC

REFERRING VET

Dr. Christensen

INVOICE

73729

DATE

3/24/26

PRESENTING CLINICAL SIGNS

- Recently started on Adaquan and laser therapy for OA.
- Owner reports intermittent eating, soft feces progressing to watery diarrhea this morning, marked flatulence, and selective appetite for treats/human food with reluctance to consume regular diet and supplements. Has been going on for the past 4 days.
- Plan is to manage appetite and diarrhea at home until ultrasound results are available. Mirtazapine will be continued @ 15 mg BID (split from prior 30 mg SID). Continue Provable Forte. Start Pro-Pectalin to promote fecal consistency. Hold Adequan and other injectables for now; laser therapy may continue.
- ALT previously noted mildly elevated at 223 U/L; CPL normal

ULTRASONOGRAPHIC EXAMINATION OF THE HEART

The echocardiogram in this patient demonstrated normal **left atrial** size based on 3 separate methods of LA evaluation. **Mitral** valve insufficiency was noted and centralized measuring 5.5 m/sec. The **left ventricle** presented thicknesses with linear contour and was not dilated nor restricted. The **myocardium** presented normal echogenicity without subjective evidence of significant fibrotic or ischemic disease. **Contractility** of the ventricular walls was adequate and in normal range for this patient evidenced by the fractional shortening measurement and subjective evaluation of the different regions of the myocardium. The **left ventricular outflow** tract demonstrated normal laminar flow and subjective structural integrity. The **right atrium** and auricle revealed normal size, structure and content. No evidence of masses was noted. **Tricuspid** valvular assessment demonstrated adequate linear morphology and kinesis. The **right ventricle** was of normal size (1/3 diameter of LV), chordae structure, myocardial echogenicity and thickness. **Pulmonary outflow** tract assessment revealed normal valve structure, laminar flow, and diameter (approx. 1:1 pa/ao ratio). No visible **pericardial** or free pleura fluid was noted. The cranial **mediastinum and pericardial and extra-cardiac regions** were free of masses in the visible window.

CANINE CARDIAC PARAMETERS	MR VMAX (m/s)	TR VMAX (m/s)	LA/AO	LA/AO (Heart Base)	FS (%)	EF (%)	EPSS (cm)
NORMAL PARAMETER	4.5-5.5	<2.7	1.3	<1.6	28-40	40-100	<0.6
PATIENT			NM	1.2	42	75	0.1
CANINE CARDIAC PARAMETERS	HR (BPM)	AV VMAX (m/s)	PV MAX (m/s)	BODY WEIGHT (kg)	LA 2D short axis Base view (cm)	LVIDd Avg; 2D and m-mode short axis (cm)	LVIDs Avg; 2D and m-mode short axis (cm)
NORMAL PARAMETER	50-100	0.7-1.7	0.7-1.6	BELOW	BELOW	BELOW	BELOW
PATIENT	80				3.5	2.75	



PATIENT

Cody Marques

SPECIES

Canine

BREED

Pitbull Mix

SEX

Neutered male

AGE

11 years

WEIGHT

61 lbs

INTERPRETED BY

Eric Lindquist, DMV
DABVP, Cert. IVUSS

IMAGING PERFORMED BY

Dr. Christensen

HOSPITAL NAME

Tranquility VC

REFERRING VET

Dr. Christensen

INVOICE

73729

DATE

3/24/26

ULTRASONOGRAPHIC EXAMINATION OF THE ABDOMEN

Urinary System

The **urinary bladder**, trigone, and pelvic urethra presented normal thicknesses and normal tone. The ureters were not visible which is normal. No uroliths or sediment were visualized and anechoic urine was present. No evidence of inflammatory or neoplastic changes was noted. Ureteral papillae were normal.

The **kidneys** revealed normal size and structure, corticomedullary definition and ratio for this age. The cortices presented largely uniform texture with normal echogenic relationship to liver and spleen. Medullary structure differed distinctly from the cortex and no evidence of pelvic dilation was present. The capsules were acceptably uniform without significant irregularities. The right kidney measured 5.9 cm.

Adrenal Glands

The right **adrenal gland** revealed a slight, hyperechoic nodule that measured 1.1 cm at the cranial pole. The right adrenal gland measured 2.95 x 0.94 cm at the cranial pole and 0.89 cm at the caudal pole. The left adrenal gland was uniform and measured 2.72 x 1.04 cm at the cranial pole and 0.82 cm at the caudal pole.

Spleen

The **spleen** in this patient was mildly enlarged with uniform parenchyma and was folded upon itself cranially. This is a positional variant and is not pathological. There was no evidence of significant disease.

Liver

The **liver** images submitted revealed subjectively normal liver size, contour, and structure. Parenchymal echogenicity was naturally coarse and hypoechoic to the spleen. Vascular and biliary tracts were of normal volume with no evidence of congestion. The gallbladder presented acceptably thin walls with primarily anechoic content. The cystic and common bile ducts were normal. No pathological hepatic lymphadenopathy was evident. No overt structural evidence of inflammatory, infiltrative or regenerative pathology was evident.

Gastrointestinal

Examination of the **gastrointestinal tract** revealed a stomach and intestine free of stasis, of normal wall thickness, acceptable curvilinear mural detail, and peristaltic activity. Small and large intestine demonstrated normal luminal chyme and stool consistency respectively. No obstructive or overt infiltrative disease was noted. No associated abnormal lymphatic activity was noted.



PATIENT

Pancreas

Cody Marques

The base and limbs of the **pancreas** were observed to be largely isoechoic to surrounding omental fat. Pancreatic duct and capsular contour were acceptably normal and parenchyma respected normal curvilinear patterns. No overt evidence of active inflammatory or neoplastic disease was noted.

SPECIES

Canine

BREED

Pitbull Mix

SEX

Neutered male

ULTRASONOGRAPHIC FINDINGS

Stage B1 valvular disease, compensated, non-clinical.

Right adrenal nodule, likely benign hyperplasia. Adenoma, emerging carcinoma, pheochromocytoma possible.

AGE

11 years

INTERPRETATION OF THE FINDINGS & FURTHER RECOMMENDATIONS

WEIGHT

61 lbs

The heart is stable without clinical disease. No overt contraindication for anesthesia of brief to moderate duration. I suggest Torbutrol premed, Propofol induction, Isoflor maintenance or similar protocol if anesthesia is desired. Blood pressure recommended if not already performed and target white coat negative systolic pressure of < 160 mmHg. If higher than this ACE-inhibitor is suggested to reach this level. Recheck echocardiogram is recommended in 6 months, earlier if murmur grade increases or clinical signs initiate.

INTERPRETED BY

Eric Lindquist, DMV
DABVP, Cert. IVUSS

Serial blood pressure measurements are warranted. The cause of the clinical signs is not evident in the abdomen or echocardiogram. Orthopedic pain, CNS or thoracic disease should all be considered.

IMAGING PERFORMED BY

Dr. Christensen

HOSPITAL NAME

Tranquility VC

REFERRING VET

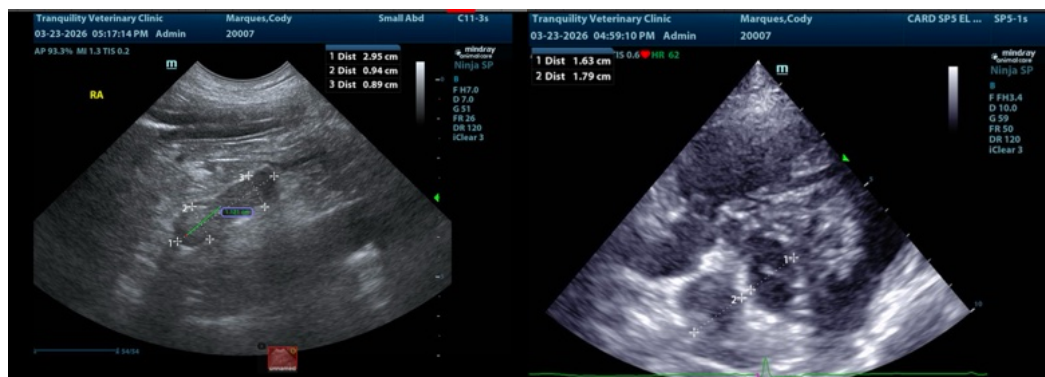
Dr. Christensen

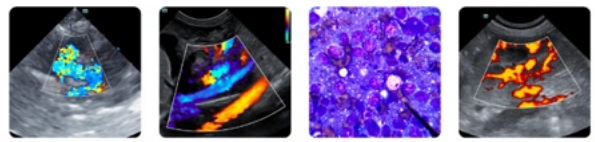
INVOICE

73729

DATE

3/24/26





PATIENT

Cody Marques

SPECIES

Canine

BREED

Pitbull Mix

SEX

Neutered male

AGE

11 years

WEIGHT

61 lbs

INTERPRETED BY

Eric Lindquist, DMV
DABVP, Cert. IVUSS

**IMAGING
PERFORMED BY**

Dr. Christensen

HOSPITAL NAME

Tranquility VC

REFERRING VET

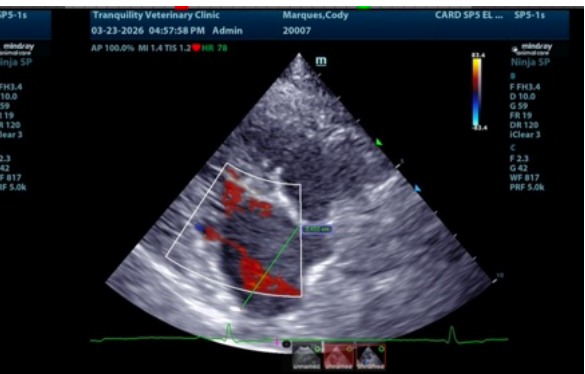
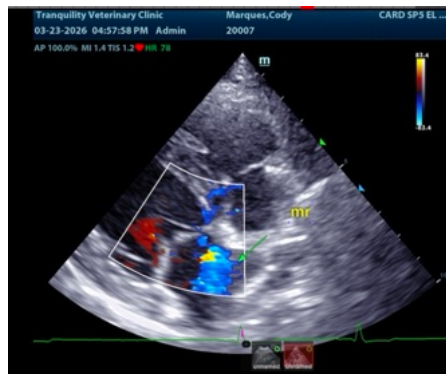
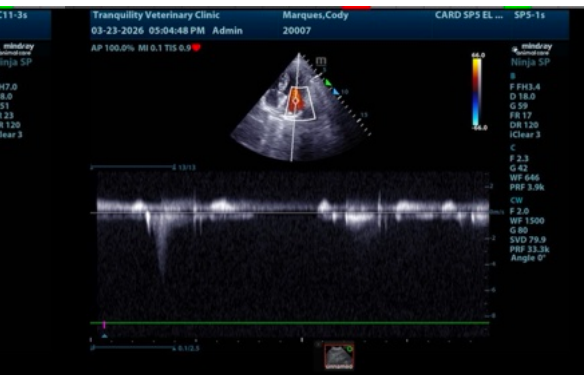
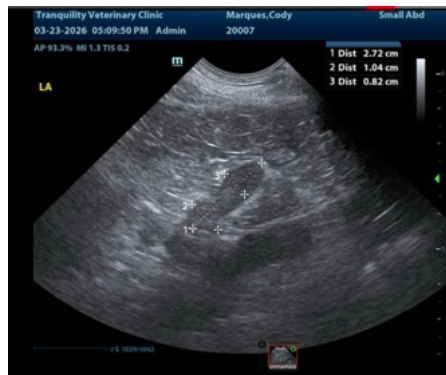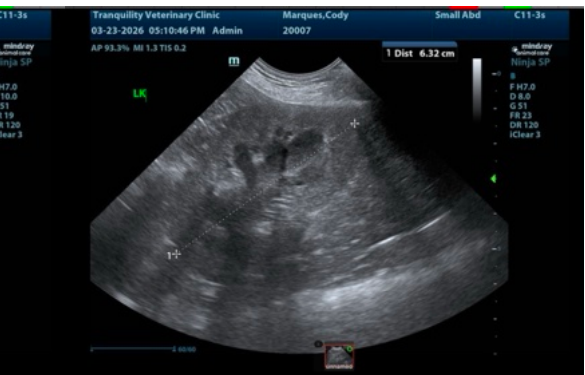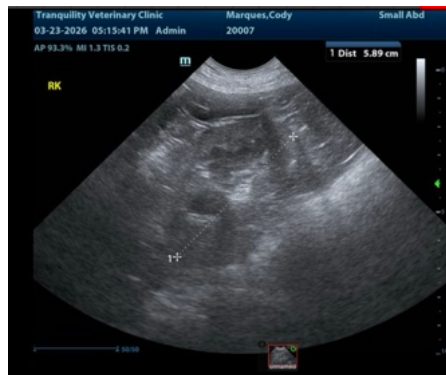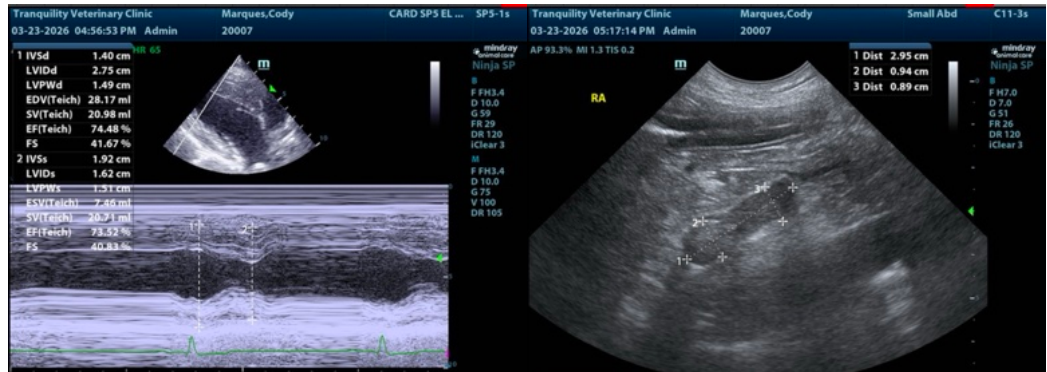
Dr. Christensen

INVOICE

73729

DATE

3/24/26





PATIENT

Cody Marques

SPECIES

Canine

BREED

Pitbull Mix

SEX

Neutered male

AGE

11 years

WEIGHT

61 lbs

INTERPRETED BY

Eric Lindquist, DMV
DABVP, Cert. IVUSS

IMAGING PERFORMED BY

Dr. Christensen

HOSPITAL NAME

Tranquility VC

REFERRING VET

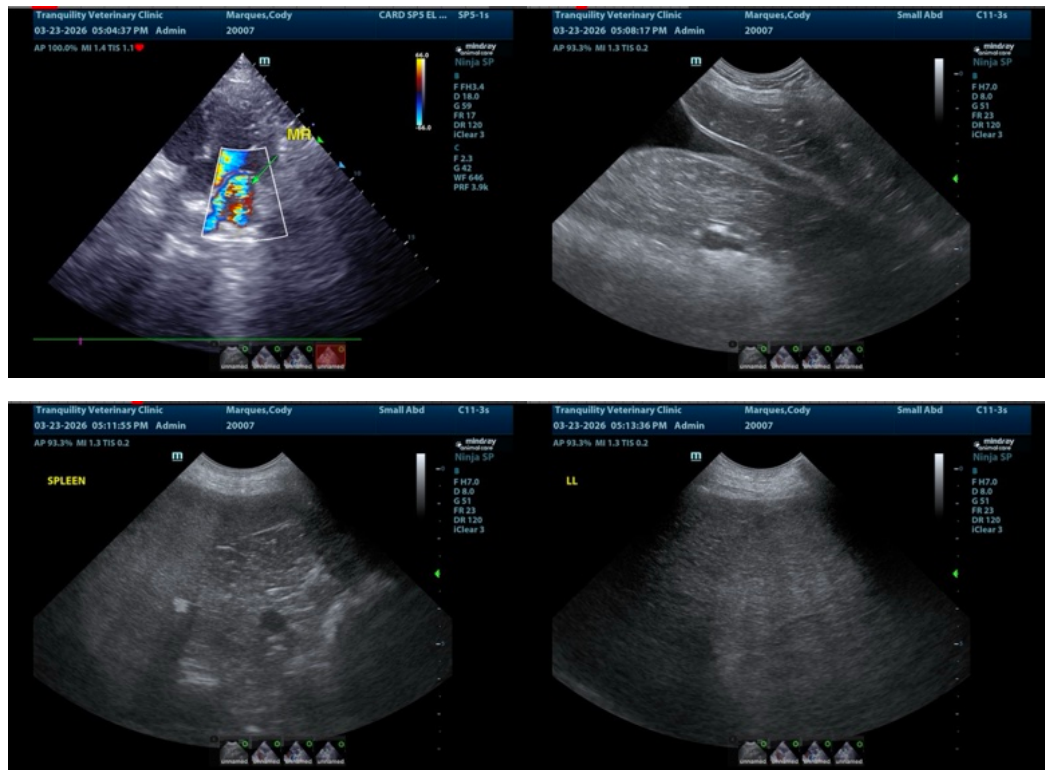
Dr. Christensen

INVOICE

73729

DATE

3/24/26



The information and recommendations provided are based on the images presented by the referring veterinarian/sonographer. No evaluation can be communicated regarding pathology that was not visible in the image/video clips provided.

Thank you for this referral. If the clinical or image interpretation does not parallel your findings or if I can be of any further assistance please contact me.

Eric Lindquist, DMV, DABVP (CFM), Cert. IVUSS, CEO of SonoPath.com

info@SonoPath.com