

PATIENT

Adali Bickert

SPECIES

Canine

BREED

GSP

SEX

Spayed Female

AGE

9 Years

WEIGHT

61.4 pounds

INTERPRETED BY

Eric Lindquist, DMV,
DABVP(CFM), Cert.
IVUSS

IMAGING PERFORMED BY

Eric Lindquist, DMV,
DABVP(CFM), Cert.
IVUSS

HOSPITAL NAME

Franklin Lakes Animal
Hospital

REFERRING VET

Dr. ER

INVOICE

14561

DATE

03/24/26

PRESENTING CLINICAL SIGNS

Mediastinal versus heart base mass. Progressive murmur from grade 2 to 5.

Current medications: Trazadone/Gabapentin

ULTRASONOGRAPHIC EXAMINATION OF THE HEART

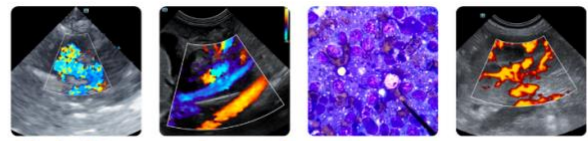
CANINE CARDIAC PARAMETERS	MR VMAX (m/s)	TR VMAX (m/s)	LA/AO (M-Mode)	LA/AO (Heart Base; Swe)	FS (%)	EF (%)	EPSS (cm)
NORMAL PARAMETER	4.5-5.5	<2.7	1.3	Up to 1.6	28-40	40-100	<0.6
PATIENT	5.8	--	1.2	1.4	32	61	0.1
CANINE CARDIAC PARAMETERS	HR (BPM)	AV VMAX (m/s)	PV MAX (m/s)	BODY WEIGHT (lbs)	LAD LA MAX 4 Chamber	LVIDd Avg; 2D and m-mode short axis (cm)	LVIDs Avg; 2D and m-mode short axis (cm)
NORMAL PARAMETER	50-100	0.7-1.7	0.7-1.6				
PATIENT	110	1.43	1.23	61.4	3.07	3.45	--

Cardiac Presentation

The echocardiogram in this patient demonstrated normal **left atrial** size based on 3 different LA measurement methods. Chamber volumes and echogenicity were normal. The cranial and caudal **mitral** valve leaflets presented vegetative thickening consistent with endocardiosis. Doppler indicated mild to moderate eccentric insufficiency. The **left ventricle** presented normal thicknesses with linear contour and was not dilated nor restricted. The **myocardium** presented normal echogenicity without subjective evidence of significant fibrotic or ischemic disease. **Contractility** of the ventricular walls was adequate and in normal range for this patient evidenced by the fractional shortening measurement and subjective evaluation of the different regions of the myocardium. The **left ventricular outflow** tract demonstrated normal laminar flow and subjective structural integrity. The **right atrium** and auricle revealed normal size, structure and content. No evidence of masses was noted or chamber overload. **Tricuspid** valvular assessment demonstrated adequate linear morphology. The **right ventricle** was of normal size (1/3 diameter of LV), chordae structure, myocardial echogenicity and thickness. **Pulmonic** tract assessment revealed normal valve structure, laminar flow, and diameter (approx.1:1 pa/ao ratio). No echographically detectable evidence of infiltrative disease was visible. The cranial **mediastinum** was free of masses in the visible window. There is approximately 4.0 cm of fat accumulation. Heart base is free of masses as well.

ULTRASONOGRAPHIC FINDINGS

- Stage B1 valvular disease with fat accumulation.



PATIENT

Adali Bickert

SPECIES

Canine

BREED

GSP

SEX

Spayed Female

AGE

9 Years

WEIGHT

61.4 pounds

INTERPRETED BY

Eric Lindquist, DMV,
 DABVP(CFM), Cert.
 IVUSS

IMAGING PERFORMED BY

Eric Lindquist, DMV,
 DABVP(CFM), Cert.
 IVUSS

HOSPITAL NAME

Franklin Lakes Animal
 Hospital

REFERRING VET

Dr. ER

INVOICE

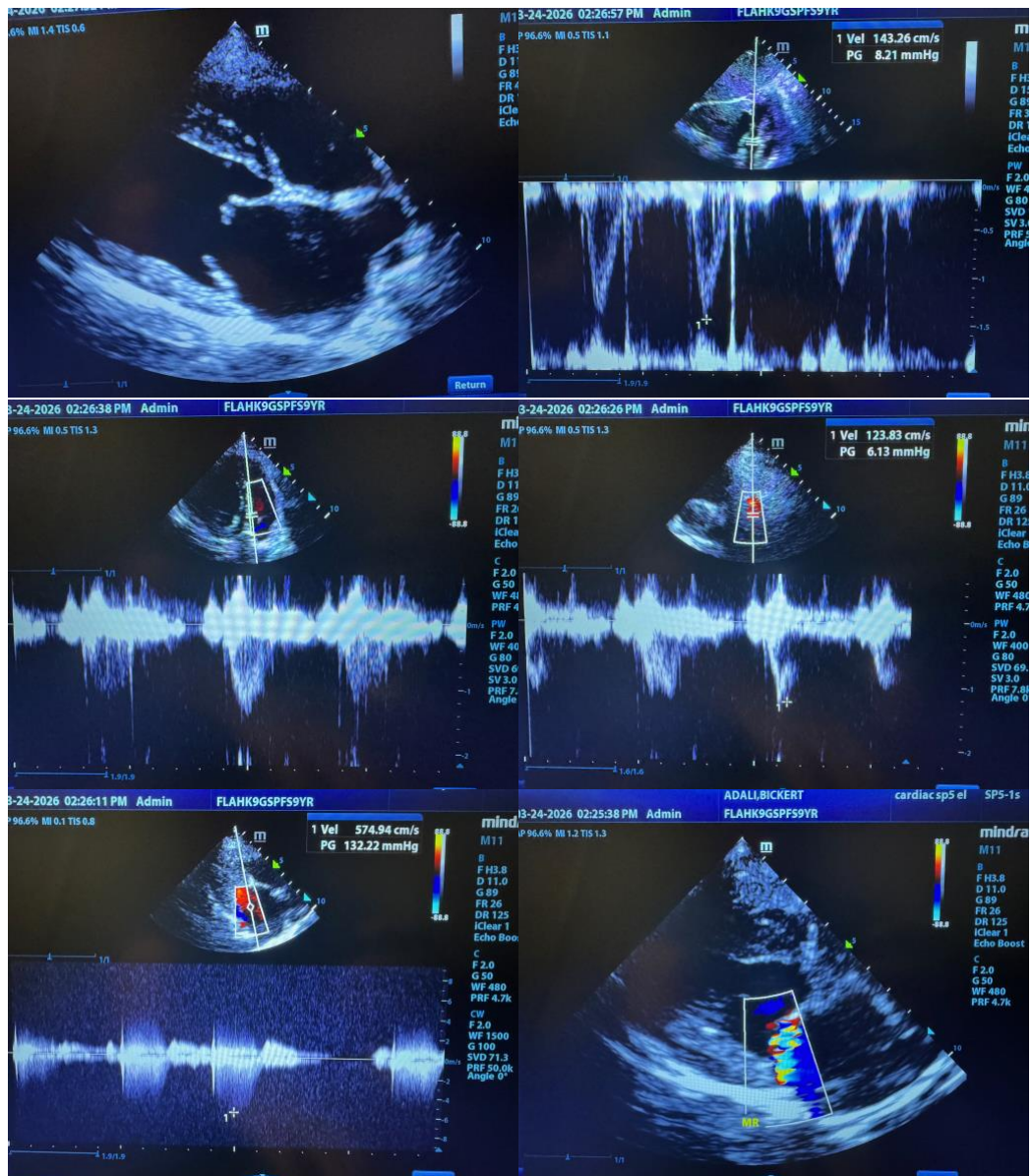
14561

DATE

03/24/26

INTERPRETATION OF THE FINDINGS & FURTHER RECOMMENDATIONS

I can't absolutely rule out a neoplastic event) in the chest, however, no acoustic window was able to reproduce the VD radiograph finding. Recommend recheck radiographs in one month ensuring that the head is extended at the time of radiograph acquisition. Recheck sonogram if the lesion is growing. It may grow into an acoustic window. Otherwise, chest CT would be appropriate.





PATIENT

Adali Bickert

SPECIES

Canine

BREED

GSP

SEX

Spayed Female

AGE

9 Years

WEIGHT

61.4 pounds

INTERPRETED BY

Eric Lindquist, DMV,
 DABVP(CFM), Cert.
 IVUSS

IMAGING PERFORMED BY

Eric Lindquist, DMV,
 DABVP(CFM), Cert.
 IVUSS

HOSPITAL NAME

Franklin Lakes Animal
 Hospital

REFERRING VET

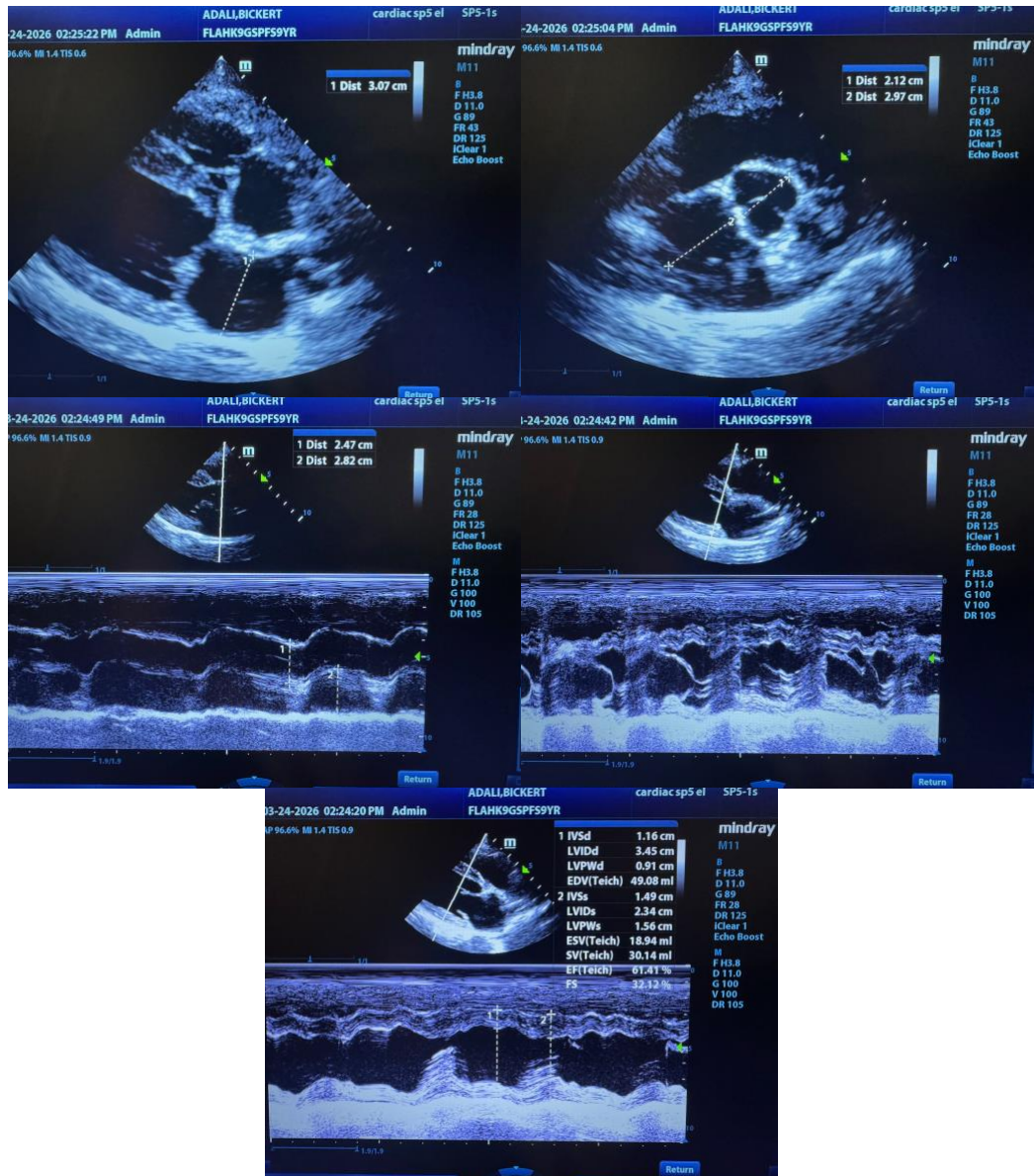
Dr. ER

INVOICE

14561

DATE

03/24/26



The information and recommendations provided are based on the images presented by the referring veterinarian/sonographer. No evaluation can be communicated regarding pathology that was not visible in the image/video clips provided.

Thank you for this referral. If the clinical or image interpretation does not parallel your findings or if I can be of any further assistance, please contact me.

Eric Lindquist, DMV, DABVP(CFM), Cert. IVUSS,

CEO, Owner, Founder -- SonoPath.com

info@SonoPath.com



PATIENT

Adali Bickert

SPECIES

Canine

BREED

GSP

SEX

Spayed Female

AGE

9 Years

WEIGHT

61.4 pounds

INTERPRETED BY

Eric Lindquist, DMV,
DABVP(CFM), Cert.
IVUSS

**IMAGING
PERFORMED BY**

Eric Lindquist, DMV,
DABVP(CFM), Cert.
IVUSS

HOSPITAL NAME

Franklin Lakes Animal
Hospital

REFERRING VET

Dr. ER

INVOICE

14561

DATE

03/24/26