



**PATIENT**

Miklo Summers

**SPECIES**

Canine

**BREED**

Pitbull

**SEX**

Neutered Male

**AGE**

7 Years

**WEIGHT**

72.2 Pounds

**INTERPRETED BY**

Eric Lindquist, DMV  
DABVP, Cert. IVUSS

**IMAGING PERFORMED BY**

Dr. Dorris

**HOSPITAL NAME**

County Line VC

**REFERRING VET**

Dr. Dorris

**INVOICE**

21781

**DATE**

3/24/23

**PRESENTING CLINICAL SIGNS**

History: Miklo is a 7-year-old neutered pitbull who presented for a mass removal of a small mass on his left toe. His preanesthetic work up revealed a mildly elevated ALT at 131. His procedure was post-poned and he was placed on hepatoprotectants. He returned several weeks later and his ALT was similarly elevated at 141. He has intermittent diarrhea, but otherwise no other clinical signs at home.

**ULTRASONOGRAPHIC EXAMINATION OF THE ABDOMEN**

**Urinary System**

The **urinary bladder**, trigone, and pelvic urethra presented normal thicknesses and normal tone. The ureters were not visible which is normal. No uroliths or sediment were visualized and anechoic urine was present. No evidence of inflammatory or neoplastic changes were noted. Ureteral papillae were normal. The pelvic urethra was imaged 2.0 cm beyond the cystourethral junction. Iliac trifurcation was unremarkable.

The **kidneys** revealed normal size and structure, corticomedullary definition and ratio for this age. The cortices presented largely uniform texture with normal echogenic relationship to liver and spleen. Medullary structure differed distinctly from the cortex and no evidence of pelvic dilation was present. The capsules were acceptably uniform without significant irregularities. The left kidney measured 6.8 cm. The right kidney measured 6.8 cm.

**Adrenal Glands**

Both **adrenal glands** were visualized and recognized as having normal shape, size, position and echogenicity for this breed. The phrenic vasculature, glandular echogenicity and detail were unremarkable. Capsule, cortex, and medullary definition were normal for this age patient. The left adrenal gland measured 0.4 cm. The right adrenal gland measured 0.8 cm at the cranial pole and 0.5 cm at the caudal pole.

**Spleen**

The **spleen** presented a smooth homogeneous parenchyma hyperechoic to liver and renal cortical parenchyma. The capsule was smooth without noticeable expansion or deviation from within the spleen or adjacent pathology. The splenic vasculature demonstrated normal volume without signs of congestion or thrombosis. No sonographic evidence of acute or chronic inflammatory, neoplastic, or infarctual changes were noted.

**Liver**

The **liver** revealed mild increased portal markings and slight coarse architecture, consistent with nonspecific low grade inflammatory hepatopathy, likely reactive hepatopathy. The gallbladder and common bile duct were unremarkable.

**Gastrointestinal**

Examination of the **gastrointestinal tract** revealed a stomach and intestine free of stasis, of normal wall thickness, acceptable curvilinear mural detail, and peristaltic activity. Small and large intestine demonstrated normal luminal chyme and stool consistency respectively. No obstructive or overt infiltrative disease was noted. No associated abnormal lymphatic activity was noted.

**Pancreas**



## PATIENT

Miklo Summers

The base and limbs of the **pancreas** were observed to be largely isoechoic to surrounding omental fat. Pancreatic duct and capsular contour were acceptably normal and parenchyma respected normal curvilinear patterns. No overt evidence of active inflammatory or neoplastic disease was noted.

## SPECIES

Canine

## ULTRASONOGRAPHIC FINDINGS

- Non-specific low grade inflammatory hepatopathy, likely reactive hepatopathy

## BREED

Pitbull

## INTERPRETATION OF THE FINDINGS & FURTHER RECOMMENDATIONS

FNA could be considered for further definition. No evidence or suspicion of neoplasia.

## SEX

Neutered Male

The hepatic clinical sonographic presentation is most consistent with Reactive Hepatopathy which is the most common cause of liver enzyme elevation in dogs and cats. The presumption is that gut and other organ antigen stimuli may be causing a low-grade immune response through portal system with which the liver is reacting to causing low-grade enzyme elevations. US-guided FNA could be performed to assess if low grade lymphoplasmacytic inflammation is present that would support this theory. If FNA is performed, please ask the cytologist to emphasize the primary inflammatory cell type. Empirical treatment measures to address this issue can include diet change to hydrolyzed diet, probiotics, deworming, nutraceuticals (SAME, Actigall...), dental exam and cleaning, and potentially antibiotics such as Clavamox. Metronidazole and Tylosin have traditionally been utilized for this purpose but new studies show that both these antibiotics can disrupt the normal intestinal bacterial flora (intestinal dysbiosis) for weeks and up to 4-6 months. Therefore, Metronidazole and Tylosin should be utilized as a last resort if other efforts have not been effective and sonographic organ appearance remains benign.

## AGE

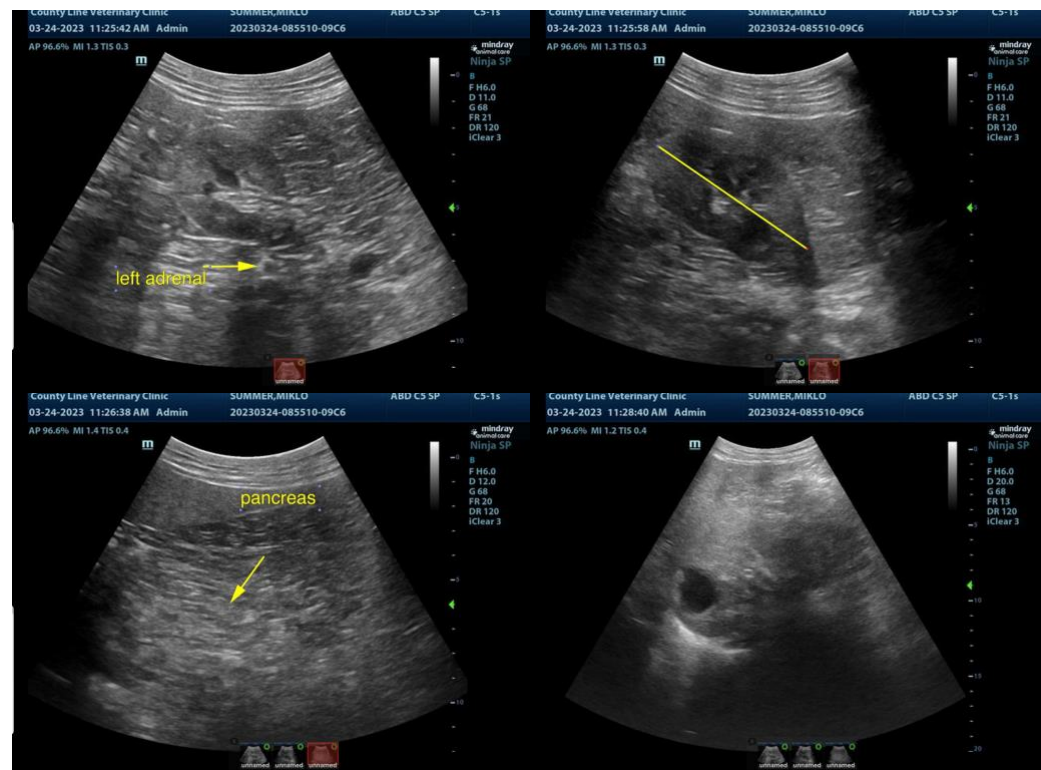
7 Years

## WEIGHT

72.2 Pounds

## INTERPRETED BY

Eric Lindquist, DMV  
DABVP, Cert. IVUSS



## IMAGING PERFORMED BY

Dr. Dorris

## HOSPITAL NAME

County Line VC

## REFERRING VET

Dr. Dorris

## INVOICE

21781

## DATE

3/24/23



## PATIENT

Miklo Summers

## SPECIES

Canine

## BREED

Pitbull

## SEX

Neutered Male

## AGE

7 Years

## WEIGHT

72.2 Pounds

## INTERPRETED BY

Eric Lindquist, DMV  
DABVP, Cert. IVUSS

## IMAGING PERFORMED BY

Dr. Dorris

## HOSPITAL NAME

County Line VC

## REFERRING VET

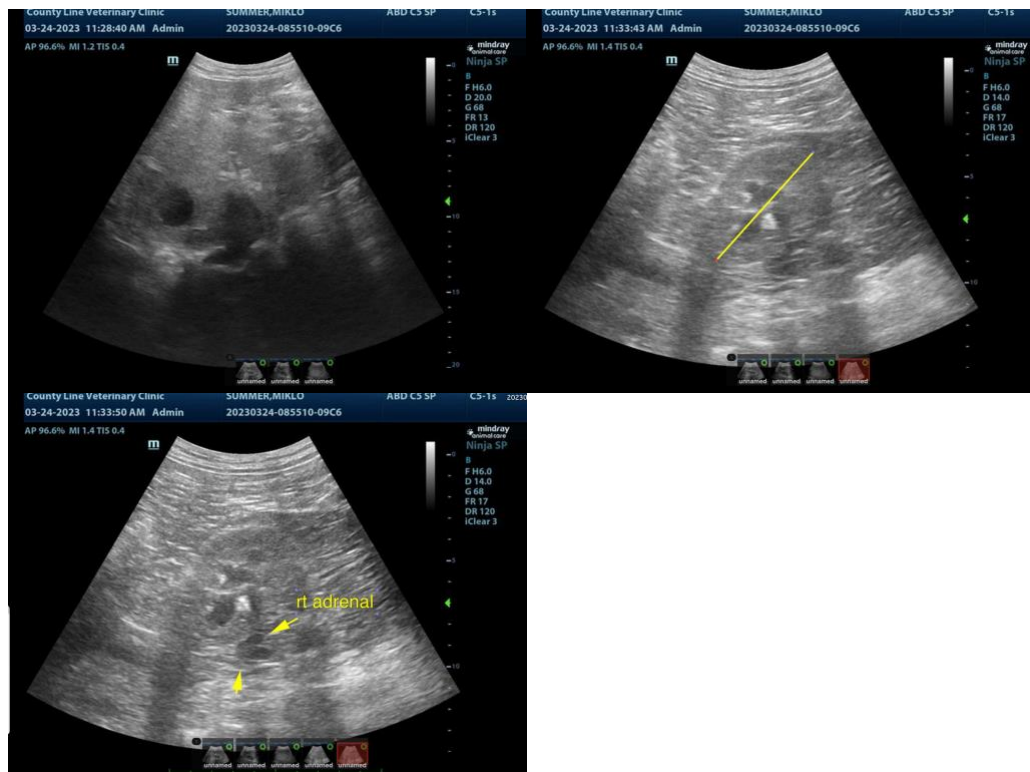
Dr. Dorris

## INVOICE

21781

## DATE

3/24/23



The information and recommendations provided are based on the images presented by the referring veterinarian. No evaluation can be communicated regarding pathology that was not visible in the image/video clips provided.

Thank you for this referral. If the clinical or image interpretation does not parallel your findings or if I can be of any further assistance please contact me.

**Eric Lindquist**, DMV, DABVP, Cert. IVUSS, CEO of SonoPath.com  
info@SonoPath.com