



**PATIENT**

Maddie Englert

**SPECIES**

Canine

**BREED**

Tibetan Terrier

**SEX**

Spayed Female

**AGE**

12 Years

**WEIGHT**

23.2 Pounds

**INTERPRETED BY**

Eric Lindquist, DMV  
DABVP, Cert. IVUSS

**IMAGING PERFORMED BY**

Mary Arpaia

**HOSPITAL NAME**

VCA McKenzie AH

**REFERRING VET**

Mary Arpaia

**INVOICE**

21778

**DATE**

3/24/23

**PRESENTING CLINICAL SIGNS**

History: Ate bones 2/1, acute vomiting and diarrhea, progressed to hemorrhagic colitis, partially responsive to medical management within 2 weeks. Since then, ongoing intermittent diarrhea (loose formed in am) and lower energy. Incidental Grade 3/6 systolic murmur

Abnormal PE/Chem/CBC/UA Results: 2/1/23- low ALT 10; Precision PSL 151 (15-140)

**ULTRASONOGRAPHIC EXAMINATION OF THE ABDOMEN**

**Urinary System**

The **urinary bladder** revealed multiple nonobstructive calculi, a grouping of which measured 1.0 cm. Minor micropolypoid changes were noted. The pelvic urethra was imaged 2.0 cm beyond the cystourethral junction.

The **kidneys** revealed largely normal size and structure, corticomedullary definition and ratio (cortex 1/3 of medulla) were essentially maintained with some moderate age-related loss of curvilinear patterns regarding the capsule and C/M junction. The cortices presented largely uniform texture with some increased echogenicity expected for his age patient. Medullary structure differed distinctly from that of the cortex and no evidence of pelvic dilation was present. Mineralization was present in the kidneys, nonobstructive. The right kidney measured 4.7 cm. The left kidney measured 4.35 cm.

**Adrenal Glands**

Both **adrenal glands** were visualized and recognized as having normal shape, size, position and echogenicity for this breed. The phrenic vasculature, glandular echogenicity and detail were unremarkable. Capsule, cortex, and medullary definition were normal for this age patient. The right adrenal gland measured 1.47 cm x 0.6 cm. The left adrenal gland measured 0.3 cm in width.

**Spleen**

The **spleen** presented a smooth homogeneous parenchyma hyperechoic to liver and renal cortical parenchyma. The capsule was smooth without noticeable expansion or deviation from within the spleen or adjacent pathology. The splenic vasculature demonstrated normal volume without signs of congestion or thrombosis. No sonographic evidence of acute or chronic inflammatory, neoplastic, or infarctual changes were noted.

**Liver**

The **liver** images submitted revealed subjectively normal liver size, contour, and structure. Parenchymal echogenicity was naturally coarse and hypoechoic to the spleen. Vascular and biliary tracts were of normal volume with no evidence of congestion. No pathological hepatic lymphadenopathy was evident. No overt structural evidence of inflammatory, infiltrative or regenerative pathology was evident. Coalesced gallbladder debris was noted, not overtly pathological.

**Gastrointestinal**

Examination of the **gastrointestinal tract** revealed a stomach and intestine free of stasis, of normal wall thickness, acceptable curvilinear mural detail, and peristaltic activity. Small and large intestine demonstrated normal luminal chyme and stool consistency respectively. No obstructive or overt infiltrative disease was noted. No associated abnormal lymphatic activity was noted.

**Pancreas**



**PATIENT**

Maddie Englert

The base and limbs of the **pancreas** were observed to be largely isoechoic to surrounding omental fat. Pancreatic duct and capsular contour were acceptably normal and parenchyma respected normal curvilinear patterns. No overt evidence of active inflammatory or neoplastic disease was noted.

**SPECIES**

Canine

**ULTRASONOGRAPHIC FINDINGS**

- Urinary bladder calculi
- Nonobstructive nephrolithiasis, likely oxalate
- Coalesced gallbladder debris

**BREED**

Tibetan Terrier

**INTERPRETATION OF THE FINDINGS & FURTHER RECOMMENDATIONS**

Cystostomy, stone analysis and culture are indicted, however, the patient may pass periodically, from the kidneys to the bladder, and therefore, lower urinary lithiasis may reform.

**SEX**

Spayed Female

**AGE**

12 Years

**WEIGHT**

23.2 Pounds

**INTERPRETED BY**

Eric Lindquist, DMV  
DABVP, Cert. IVUSS

**IMAGING PERFORMED BY**

Mary Arpaia

**HOSPITAL NAME**

VCA McKenzie AH

**REFERRING VET**

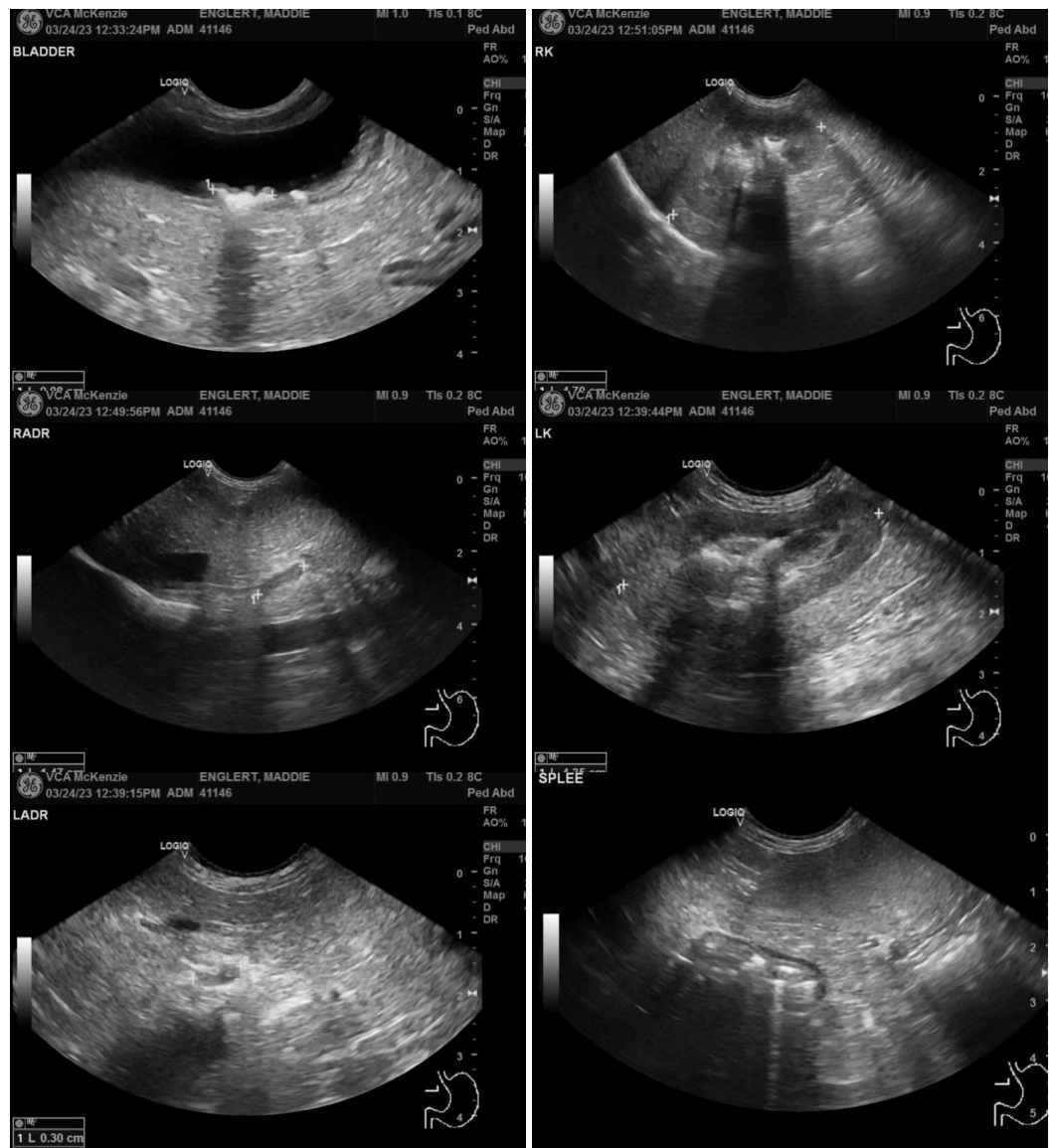
Mary Arpaia

**INVOICE**

21778

**DATE**

3/24/23





**PATIENT**

Maddie Englert

**SPECIES**

Canine

**BREED**

Tibetan Terrier

**SEX**

Spayed Female

**AGE**

12 Years

**WEIGHT**

23.2 Pounds

**INTERPRETED BY**

Eric Lindquist, DMV  
DABVP, Cert. IVUSS

**IMAGING PERFORMED BY**

Mary Arpaia

**HOSPITAL NAME**

VCA McKenzie AH

**REFERRING VET**

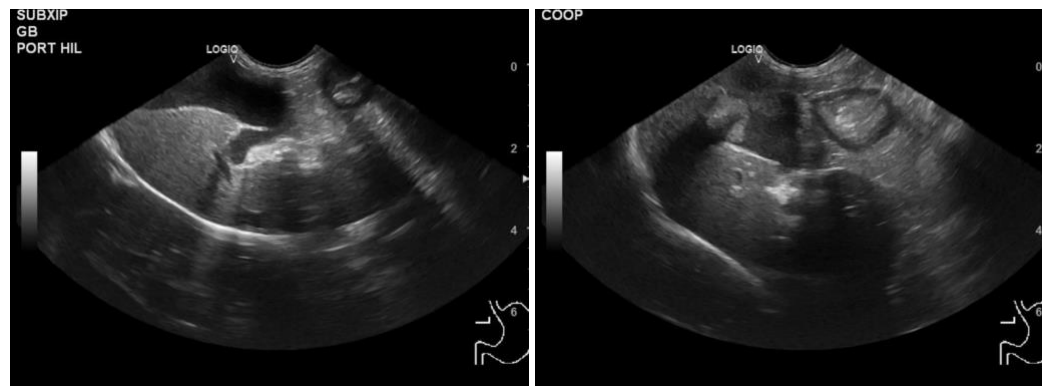
Mary Arpaia

**INVOICE**

21778

**DATE**

3/24/23



The information and recommendations provided are based on the images presented by the referring veterinarian. No evaluation can be communicated regarding pathology that was not visible in the image/video clips provided.

Thank you for this referral. If the clinical or image interpretation does not parallel your findings or if I can be of any further assistance please contact me.

**Eric Lindquist**, DMV, DABVP, Cert. IVUSS, CEO of SonoPath.com  
info@SonoPath.com