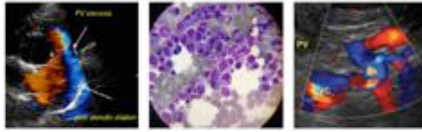


IMAGING PERFORMED BYSVS Mobile Imaging 262-366-5970
fredgromalak@gmail.com

Clinical Sonography & Telectology

EDUCATIONAL TELECONSULTATION SERVICES™

1-800-838-4268 info@sonopath.com SonoPath.com

PATIENT

Oreo Coleman

SPECIES

Canine

BREED

Dachshund

SEX

Spayed Female

AGE

12 years

WEIGHT

10.5 lbs

INTERPRETED BYEric Lindquist, DMV
DABVP, Cert. IVUSS**IMAGING PERFORMED BY**

Kim Liedberg

HOSPITAL NAME

SVS Imaging WI

REFERRING VET

Dr. Mullen

INVOICE

97785

DATE

3/22/22

PRESENTING CLINICAL SIGNS

History: 2.13.2022 seen for vomiting, excessive thirst and hunger, Crystals in the urine Blood testing showed elevated calcium levels, DDx = Grade IV/V periodontal disease, canine hyperthyroidism, cardiac disease.

2/16/22 Urinalysis: color = dark yellow, SB 1.025, pH 6.0, crystals:3+ calcium oxalate. 2/23/22 proBNP 279. Parathyroid hormone 10.9, CPK 289, Alk/Phos 176 Chol 368.

ULTRASONOGRAPHIC EXAMINATION

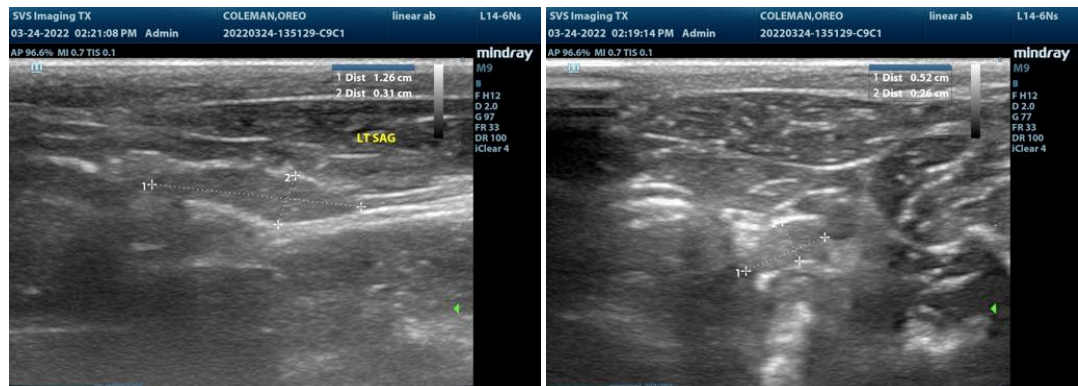
The thyroid lobes were imaged and uniform. The maximum size on the right side measured 0.5 cm and the left thyroid lobe measured 0.3 cm. The parenchyma was uniform. The trachea, salivary glands and regional tissues were all normal. There were no visible parathyroid adenomas noted in this patient.

ULTRASONOGRAPHIC FINDINGS

Normal thyroid lobes and regional tissues.

INTERPRETATION OF THE FINDINGS & FURTHER RECOMMENDATIONS

No therapy is recommended.



The information and recommendations provided are based on the images presented by the referring veterinarian/sonographer. No evaluation can be communicated regarding pathology that was not visible in the image/video clips provided.

Thank you for this referral. If the clinical or image interpretation does not parallel your findings or if I can be of any further assistance please contact me.

Eric Lindquist, DMV, DABVP, Cert. IVUSS, CEO of SonoPath.com
Eric.Lindquist@SonoPath.com