



PATIENT

Mia Agosto Fernandez

SPECIES

Canine

BREED

Dachshund

SEX

Spayed Female

AGE

7 years

WEIGHT

12.6 lbs

INTERPRETED BY

Eric Lindquist, DMV
DABVP, Cert. IVUSS

IMAGING PERFORMED BY

Dr. Ferrer

HOSPITAL NAME

Paseos VC

REFERRING VET

Dr. Davila

INVOICE

97760

DATE

3/24/22

PRESENTING CLINICAL SIGNS

History: Presented as a referral for a neck ultrasound. The patient originally presented to the referring vet on March 18th for an evaluation of hypoactive, fever, and weight loss. The PE showed during that visit that the pt had swelling and inflammation of the entire neck region. The neck measured 3.23 inches wide and 3.82 inches tall on 3-18-22. The neck measured 2.7 inches wide and 3.2 inches tall on 3-21-22. The patient is currently on Clavamox and Prednisone. Ultrasound to rule out: Lymph nodes enlargement, thyroid or salivary gland enlargement.
Abnormal PE/Chem/CBC/UA Results: PE: Very swollen neck area bilateral. The entire neck region. Today's temp: 102.7F BW: no information was provided

ULTRASONOGRAPHIC EXAMINATION

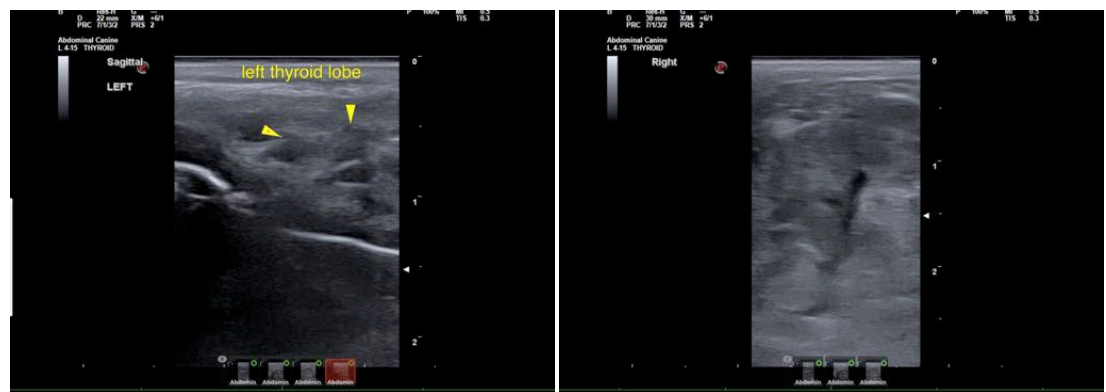
The neck region was imaged. The salivary glands and regional tissues appear normal. The left thyroid region appeared unremarkable. However, the right thyroid region revealed a complex, ill-defined, poorly margined mass that measured approximately 2.5-4.0 cm in length. The mass displaced regional tissues and enveloped the regional vasculature. This does not appear resectable. This is strongly suggestive for carcinoma.

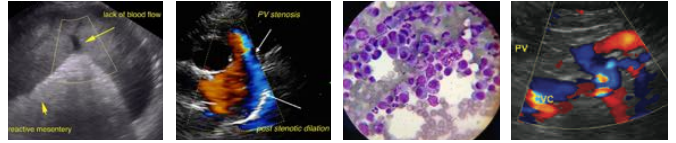
ULTRASONOGRAPHIC FINDINGS

Right thyroid mass, suspect carcinoma. Otherwise, unremarkable tissues.

INTERPRETATION OF THE FINDINGS & FURTHER RECOMMENDATIONS

Treatment is recommended based on FNA results. CT evaluation would be ideal.





PATIENT

Mia Agosto Fernandez

SPECIES

Canine

BREED

Dachshund

SEX

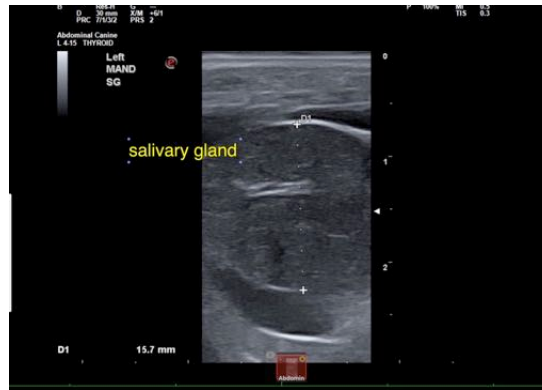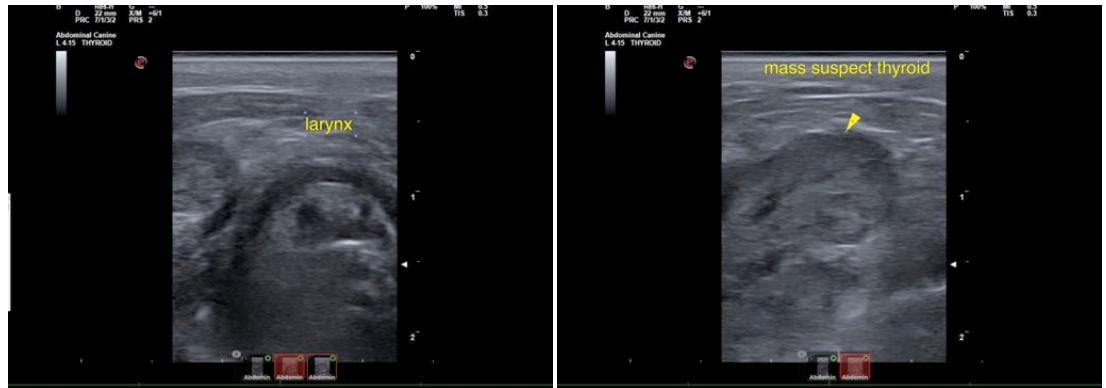
Spayed Female

AGE

7 years

WEIGHT

12.6 lbs



INTERPRETED BY

Eric Lindquist, DMV
DABVP, Cert. IVUSS

The information and recommendations provided are based on the images presented by the referring veterinarian/sonographer. No evaluation can be communicated regarding pathology that was not visible in the image/video clips provided.

IMAGING PERFORMED BY

Dr. Ferrer

Eric Lindquist, DMV, DABVP, Cert. IVUSS, CEO of SonoPath.com
info@SonoPath.com

HOSPITAL NAME

Paseos VC

Thank you for this referral. If the clinical or image interpretation does not parallel your findings or if I can be of any further assistance please contact me.

REFERRING VET

Dr. Davila

INVOICE

97760

DATE

3/24/22